

Case Report

***Streptococcus constellatus*-associated pyoderma in a dog**

Luisa De Martino,¹ Sandra Nizza,¹ Claudio de Martinis,¹ Valentina Foglia Manzillo,² Valentina Iovane,¹ Orlando Paciello¹ and Ugo Pagnini¹

Correspondence

Luisa De Martino

luisa.demartino@unina.it

¹Department of Pathology and Animal Health, Faculty of Veterinary Medicine, University of Naples 'Federico II', Via F. Delpino 1, 80137 Naples, Italy

²Department of Veterinary Clinical Sciences, Faculty of Veterinary Medicine, University of Naples 'Federico II', Via F. Delpino 1, 80137 Naples, Italy

This report describes a case of chronic and deep pyodermitis in a 4-year-old male dog with a 3-month skin problems history that had been treated unsuccessfully with fluoroquinolone therapy, prescribed by a private medical veterinary practice, without an early diagnosis. Microbiological examination and antimicrobial susceptibility testing were performed in our laboratory (Faculty of Veterinary Medicine) and a diagnosis of *Streptococcus constellatus*-associated pyoderma in the dog was made. A new antimicrobial treatment, with tetracyclines, was designed after the definitive diagnosis and antimicrobial susceptibility testing performed by the Kirby–Bauer disc diffusion method. The dog remained free of clinical illness at completion of therapy. To our knowledge, this is the first case of a canine pyoderma caused by *S. constellatus*, a commensal organism which may also cause pyogenic infections. Furthermore, this study confirms that a fluoroquinolone represents a poor empirical choice for initial therapy of canine pyoderma.

Received 29 April 2011

Accepted 3 November 2011

Introduction

Streptococcus intermedius, *Streptococcus constellatus* and *Streptococcus anginosus* represent the three species of the '*Streptococcus milleri*' group (Whiley *et al.*, 1990; Whitworth, 1990), synonym *Streptococcus anginosus* group (Facklam, 2002), and form part of the normal flora of the mouth, gastrointestinal tract and genitourinary tract. Moreover, the literature describes that they are often associated with purulent infections in humans: *S. intermedius* has been associated with abscesses of the brain and liver, while both *S. anginosus* and *S. constellatus* have been isolated from a wider range of sites and infections (Whiley *et al.*, 1992). These micro-organisms are often α -haemolytic, but occasionally can be β -haemolytic or non-haemolytic (Ruoff, 1988), and have a predisposition to form abscesses (Clarridge *et al.*, 2001).

Puppies and older dogs are most susceptible to developing streptococcal infection (Lamm *et al.*, 2010), as their immune systems are not fully developed or have declined.

We report what we believe to be the first case illustrating how an organism of the '*Streptococcus milleri*' group, namely *S. constellatus*, is associated with clinical manifestations of chronic and deep pyodermitis in a dog, and show the importance of performing antimicrobial resistance profiling to guide an appropriate initial antibiotic therapy.

Case report

A 4-year-old male Italian hound was referred in April 2010 to the Department of Clinical Science, University of Veterinary Medicine of Naples (Italy), presenting severe and chronic cutaneous lesions localized on the lumbar (Fig. 1) and left flank (Fig. 2) regions. The following information was tabulated and evaluated: signalment (age, breed, sex and weight), history (prior skin disease, prior noncutaneous disease, prior treatments and systemic antibiotic administration), dermatological examination (skin lesions and body sites involved). There was no history of recent antimicrobial therapy. Legal consent was required and obtained.

The owner reported that the dog had shown cutaneous signs for 3 months and had been treated in the past, for the same problem, with enrofloxacin (10 mg kg⁻¹) per os s.i.d. for 21 days without any improvement but with an aggravation of cutaneous signs.

Exploration of the cutaneous lesions revealed the presence of large nodular lesions with fistulas and purulent exudates. Blood sampling, skin imprints and multiple superficial and deep skin scraping were done for diagnostic procedures.

Complete blood cell counts were performed using an automated cell counter (HeCo 5 Vet C-SEAC; Radim) on whole blood treated with EDTA K3.

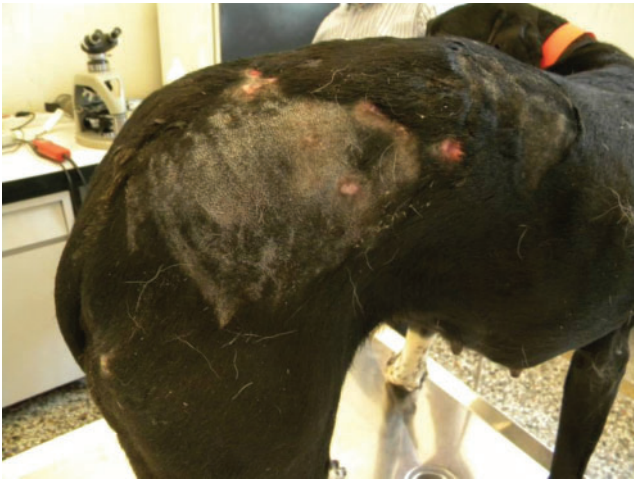

Fig. 1. Large nodular lesions on the lumbar region: fistulas and purulent exudates are present.

Sera, obtained after whole blood centrifugation, were analysed using an automatic multianalyser (Analyser Medical System). Quantitative determination of urea (Urease-GLDH. Kinetic UV), creatinine (Jaffé Colorimetric-Kinetic), alanine aminotransferase (NADH.kinetic UV.IFCC rec), aspartate aminotransferase (NADH.kinetic UV.IFCC rec), glucose (Trinder. GOD-POD) and total protein (Biuret. Colorimetric) was done using Spinreact reagents; Spintrol H Cal-Serum human calibrator and Spintrol H normal-Serum human control serum (Spinreact) were used.

The haematological and biochemical values assayed were within the expected ranges for a 4-year-old dog.

Skin scraping, fine needle aspiration cytology and slit smears were done to obtain material for cytological examination. The smears were air-dried and stained with May-Grünwald Giemsa, Ziehl-Neelsen and periodic acid-Schiff stains.

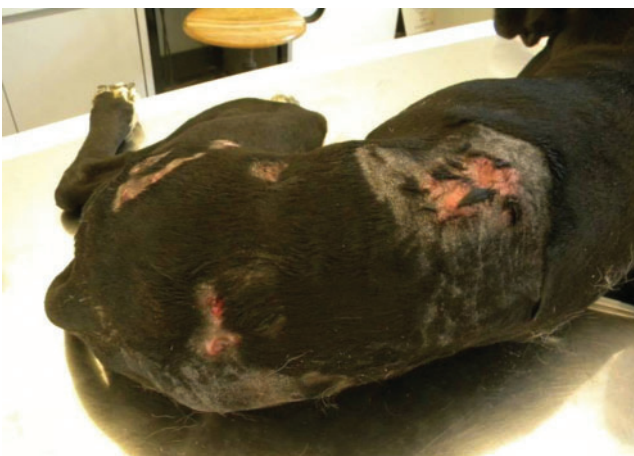

Fig. 2. Cutaneous lesions with irregular borders and purulent fluid material disseminated on the left-flank region.

Cytology revealed the presence of numerous degenerated neutrophils, and some macrophages with abundant foamy cytoplasm. Many coccus-shaped bacteria were seen in the cytoplasm of neutrophils and on the background of the slide. Sometimes eosinophils and red blood cells were also found. The Ziehl-Neelsen and periodic acid-Schiff stains were negative for mycobacteria and fungi, respectively. A diagnosis of deep pyoderma was made (Fig. 3).

No fungi or dermatophytes were found to be present on microbiological analysis of a fine needle aspiration of a skin lesion. Moreover, there was no growth on MacConkey agar or Baird Parker agar (both from Oxoid), but a β -haemolytic strain was observed on Columbia CNA agar base with colistin sulfate and nalidixic acid added (CNA) (Oxoid) cultured anaerobically at 37 °C in a plastic anaerobic jar in the presence of Oxoid AnaeroGen used for the rapid generation of an anaerobic environment, which is essential for the isolation and growth of fastidious anaerobes. Bacterial growth under these conditions was observed on day 3, while no growth on CNA agar cultured aerobically was observed. Colonies were catalase-negative and a Gram stain revealed Gram-positive cocci. The phenotypic reaction profile of this isolate (excellent identification, 99.9%) was obtained with the API 20A test for anaerobic bacteria (bioMérieux) and was in accordance with the identification of *S. constellatus*. To obtain further confirmation, the isolate was characterized to species level by use of the Fluo-Card Milleri test kit (KEY Scientific Products) and 16S rRNA sequencing was used to definitively identify the strain (Clarridge *et al.*, 1999).

The isolate was tested for susceptibility to 16 antimicrobial agents by the Kirby-Bauer disc diffusion method on Mueller-Hinton agar incubated at 37 °C, in accordance with the principles described in the Clinical and Laboratory Standards Institute standard method for veterinary pathogens (CLSI, 2002). Discs of amoxicillin and clavulanic acid (30 μ g), ampicillin (10 μ g), ceftiofur (30 μ g), ceftriaxone (30 μ g), ceftazidime (30 μ g), doxycycline (30 μ g), erythromycin (15 μ g), gentamicin (10 μ g), kanamycin (30 μ g), tetracycline (30 μ g), penicillin G (10 μ g), nalidixic acid (30 μ g), enrofloxacin (5 μ g), streptomycin (10 μ g), trimethoprim/sulfamethoxazole (25 μ g) and vancomycin (30 μ g) were tested. After measuring the antimicrobial zone diameters, and following the instructions of the manufacturer of the antibiotic discs (Oxoid), the strain was categorized as susceptible or resistant to the drug. However, antibiotics that the strain was characterized as intermediately susceptible to were included with those that the strain was characterized as resistant to. *S. constellatus* was sensitive to several antibiotics, and showed resistance to nalidixic acid, enrofloxacin, streptomycin and trimethoprim/sulfamethoxazole. The results of the antimicrobial susceptibility testing are given in Table 1. The resistance to fluoroquinolones, represented by enrofloxacin, confirmed the improper use of the initial choice for antibiotic therapy treatment of the dog, and highlights that a full antimicrobial investigation should be considered when providing antibiotic therapy.

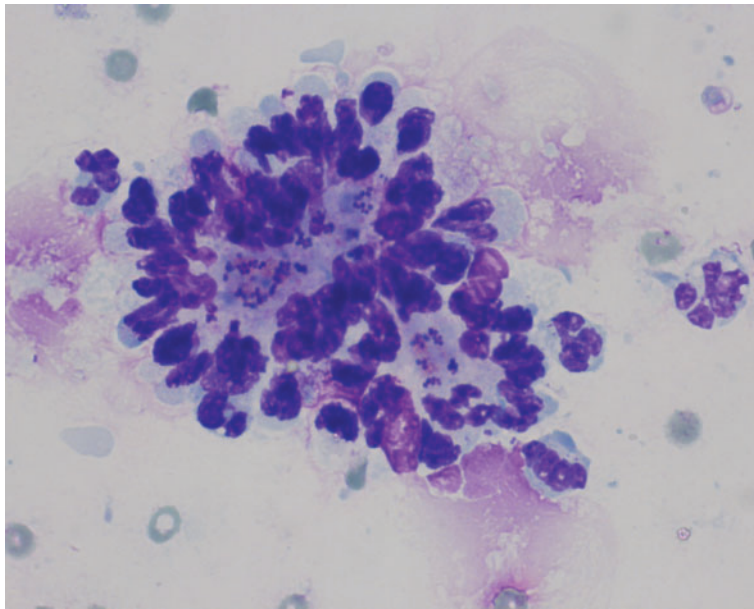


Fig. 3. Photomicrograph of a cytological slide showing several degenerated neutrophils associated with many spherical-shaped bacteria.

After the definitive diagnosis, the dog was treated with doxycycline 5 mg kg^{-1} per os s.i.d. for 1 month. The owner reported that all of the dog's clinical signs resolved and it remained free of clinical illness after completion of the new therapy.

Discussion

Pyoderma is a common infectious skin disorder in dogs, and most of the cases are caused by staphylococcal strains, in particular *Staphylococcus pseudintermedius* (Gross *et al.*,

2005; Kawakami *et al.*, 2010). To our knowledge, this is the first report in the literature of canine pyoderma caused by *Streptococcus constellatus*.

S. constellatus is a member of the '*Streptococcus milleri*' group (Whitworth, 1990) along with *S. intermedius* and *S. anginosus*. They are found among the normal oropharyngeal and gastrointestinal flora, but can cause abscesses in the abdominal cavity, lower respiratory tract, urogenital tract, orofacial and sinus area and skin (Clarridge *et al.*, 2001).

S. constellatus is frequently isolated from dental abscesses and other suppurative lesions, and a high level of hydrogen

Table 1. Susceptibility of the *S. constellatus* strain to 16 antibiotics

S, Susceptible; R, resistant.

Category	Antibiotics	Susceptible/ resistant
Penicillins	Penicillin	S
	Amoxicillin and clavulanate	S
Aminopenicillins	Ampicillin	S
Aminoglycosides	Gentamicin	S
	Kanamycin	R
	Streptomycin	R
Cephalosporin 3rd generation	Ceftiofur	S
	Ceftriaxone	S
	Ceftazidime	R
Quinolones 1st generation	Nalidixic acid	R
Fluoroquinolones (quinolones 2nd generation)	Enrofloxacin	R
Glycopeptides	Vancomycin	S
Macrolides C14	Erythromycin	S
Sulfonamides + diaminopyrimidines	Trimethoprim/sulfamethoxazole	R
Tetracyclines	Tetracycline	S
	Doxycycline	S

sulfide production seems to be associated with its abscess formation (Yoshida *et al.*, 2008). *S. constellatus* is a Gram-positive, group-C, β -haemolytic, microaerophilic streptococcus known to cause upper body abscesses and respiratory infections, especially in immunocompromised individuals (Fuentes Olmo *et al.*, 2006). Its ability to produce capsular material acts a protective shield from the body's defences. The complete clinical spectrum of infections caused by this organism has yet to be determined.

In the medical literature, *S. constellatus* has been considered a commensal micro-organism and not to be pathogenic for humans. However, more recently, *S. constellatus* has been included in the list of pathogens causing mycotic aneurysms (Chiang *et al.*, 2004), it has been reported as cause of multiple pyogenic liver abscesses (Rodrigues *et al.*, 2009), and *S. constellatus* bacteraemia following an incomplete tooth extraction resulting in septic shock has also been described (Ng & Mukhopadhyay, 2009).

We hypothesize that this case may have implications for the control of *S. constellatus* infections in dog kennels. Furthermore, it is likely that *S. constellatus* colonization in dogs in contact with humans or vice versa may provide a previously unrecognized reservoir of the infection.

This study also reports the alarming antimicrobial resistance to an antibiotic used as therapy without a definitive diagnosis, and highlights the importance of a correct bacteriological diagnosis and of the susceptibility testing of antimicrobial agents.

The use of antimicrobials has increased significantly in human and veterinary medicine, and the widespread use of antibiotics has markedly improved public health over the last 60 years (Soulsby, 2005). However, the efficacy of antibiotic treatment is rapidly decreasing as a result of the continual spread of antibiotic resistance in pathogen populations, and the decreased utility of many antibiotics has created a critical need for new therapeutic agents.

Although there is evidence of multidrug-resistant infections in both humans and domestic animals, the source of this resistance is not clear. Recent work has shown that both the mechanisms of antibiotic action and resistance and the ecological (treatment) context in which resistance evolves influence the evolution of resistance in a predictable manner (MacLean *et al.*, 2010). However, antibiotic resistance is compounded by the misuse of antibiotics (Livermore, 2003), and reducing the inappropriate use of antibiotics has been advocated as a means of minimizing the development of resistance (Livermore, 2005).

Recently, the testing recommendations have not included quinolones and aminoglycosides for viridans group streptococci (CLSI, 2008, 2010), and the failure of the first antibiotic therapy with enrofloxacin confirms that fluoroquinolones represent a poor empirical choice for initial therapy of pyoderma. Additionally, the reported ceftazidime resistance is very interesting given the pan-susceptibility to all simple β -lactams, which requires further

investigation. Similar instances of streptococcal strains that are penicillin-susceptible and resistant to ceftazidime have already been reported (Barry *et al.*, 1995), and ceftazidime resistance has been attributed to mutations in several *bla*_{CTX-M} determinants (Welsh *et al.*, 2005).

Further investigations are also needed to define the role of *S. constellatus* in animal disease and the potential for zoonotic transmission.

References

- Barry, A. L., Brown, S. D. & Novick, W. J. (1995). In vitro activities of cefotaxime, ceftriaxone, ceftazidime, cefpirome, and penicillin against *Streptococcus pneumoniae* isolates. *Antimicrob Agents Chemother* **39**, 2193–2196.
- Chiang, W. C., Tsai, J. C., Chen, S. Y., Hsu, C. Y., Wu, C. T., Teng, L. J. & Hsueh, P. R. (2004). Mycotic aneurysm caused by *Streptococcus constellatus* subsp. *constellatus*. *J Clin Microbiol* **42**, 1826–1828.
- Clarridge, J. E., III, Osting, C., Jalali, M., Osborne, J. & Waddington, M. (1999). Genotypic and phenotypic characterization of “*Streptococcus milleri*” group isolates from a Veterans Administration hospital population. *J Clin Microbiol* **37**, 3681–3687.
- Clarridge, J. E., III, Attorri, S., Musher, D. M., Hebert, J. & Dunbar, S. (2001). *Streptococcus intermedius*, *Streptococcus constellatus*, and *Streptococcus anginosus* (“*Streptococcus milleri* group”) are of different clinical importance and are not equally associated with abscess. *Clin Infect Dis* **32**, 1511–1515.
- CLSI (2002). *Zone Diameter Interpretive Standards and Minimal Inhibitory Concentration (MIC) Breakpoints for Veterinary Pathogens*; Approved Standard, 2nd edn. M31-A2. Wayne, PA: Clinical and Laboratory Standards Institute.
- CLSI (2008). *Performance Standards for Antimicrobial Disk and Dilution Susceptibility Tests for Bacteria Isolated from Animals*; Approved Standard, 3rd edn. M31-A3. Wayne, PA: Clinical and Laboratory Standards Institute.
- CLSI (2010). *Performance Standards for Antimicrobial Susceptibility Testing*, 20th Informational Supplement. M100-S20. Wayne, PA: Clinical and Laboratory Standards Institute.
- Facklam, R. (2002). What happened to the streptococci: overview of taxonomic and nomenclature changes. *Clin Microbiol Rev* **15**, 613–630.
- Fuentes Olmo, J., Ruiz Mariscal, M., Uribarrena Amezcaga, R. & Omiste Sanvicente, T. (2006). [Spontaneous bacterial peritonitis due to *Streptococcus constellatus*]. *Gastroenterol Hepatol* **29**, 595–596 (in Spanish).
- Gross, T. A., Ihrke, P. J., Walder, E. J. & Affolter, V. K. (2005). Pustular diseases of the epidermis. In *Skin Diseases of the Dog and Cat: Clinical and Histopathologic Diagnosis*, 2nd edn, pp. 6–9. Oxford: Blackwell Science.
- Kawakami, T., Shibata, S., Murayama, N., Nagata, M., Nishifuji, K., Iwasaki, T. & Fukata, T. (2010). Antimicrobial susceptibility and methicillin resistance in *Staphylococcus pseudintermedius* and *Staphylococcus schleiferi* subsp. *coagulans* isolated from dogs with pyoderma in Japan. *J Vet Med Sci* **72**, 1615–1619.
- Lamm, C. G., Ferguson, A. C., Lehenbauer, T. W. & Love, B. C. (2010). Streptococcal infection in dogs: a retrospective study of 393 cases. *Vet Pathol* **47**, 387–395.
- Livermore, D. M. (2003). Bacterial resistance: origins, epidemiology, and impact. *Clin Infect Dis* **36** (Suppl. 1), S11–S23.
- Livermore, D. M. (2005). Minimising antibiotic resistance. *Lancet Infect Dis* **5**, 450–459.

- MacLean, R. C., Hall, A. R., Perron, G. G. & Buckling, A. (2010).** The population genetics of antibiotic resistance: integrating molecular mechanisms and treatment contexts. *Nat Rev Genet* **11**, 405–414.
- Ng, K. W. & Mukhopadhyay, A. (2009).** *Streptococcus constellatus* bacteremia causing septic shock following tooth extraction: a case report. *Cases J* **2**, 6493.
- Rodrigues, A. L., Soares, M. C., Ramos, F. L. & Crociati Meguins, L. (2009).** Multiple pyogenic liver abscesses caused by *Streptococcus constellatus* in the Amazon region. Case report. *Ann Hepatol* **8**, 255–257.
- Ruoff, K. L. (1988).** *Streptococcus anginosus* (“*Streptococcus milleri*”): the unrecognized pathogen. *Clin Microbiol Rev* **1**, 102–108.
- Soulsby, E. J. (2005).** Resistance to antimicrobials in humans and animals. *BMJ* **331**, 1219–1220.
- Welsh, K. J., Barlow, M., Tenover, F. C., Biddle, J. W., Rasheed, J. K., Clark, L. A. & McGowan, J. E., Jr (2005).** Experimental prediction of the evolution of ceftazidime resistance in the CTX-M-2 extended-spectrum beta-lactamase. *Antimicrob Agents Chemother* **49**, 1242–1244.
- Whiley, R. A., Fraser, H., Hardie, J. M. & Beighton, D. (1990).** Phenotypic differentiation of *Streptococcus intermedius*, *Streptococcus constellatus*, and *Streptococcus anginosus* strains within the “*Streptococcus milleri* group”. *J Clin Microbiol* **28**, 1497–1501.
- Whiley, R. A., Beighton, D., Winstanley, T. G., Fraser, H. Y. & Hardie, J. M. (1992).** *Streptococcus intermedius*, *Streptococcus constellatus*, and *Streptococcus anginosus* (the *Streptococcus milleri* group): association with different body sites and clinical infections. *J Clin Microbiol* **30**, 243–244.
- Whitworth, J. M. (1990).** Lancefield group F and related streptococci. *J Med Microbiol* **33**, 135–151.
- Yoshida, Y., Ito, S., Sasaki, T., Kishi, M., Kurota, M., Suwabe, A., Kunimatsu, K. & Kato, H. (2008).** Molecular and enzymatic characterization of β C-S lyase in *Streptococcus constellatus*. *Oral Microbiol Immunol* **23**, 245–253.