

# Neuroendocrine carcinoma of the larynx with Lambert-Eaton myasthenic syndrome: a rare case report and literature review

Journal of International Medical Research  
49(5) 1–7

© The Author(s) 2021

Article reuse guidelines:

[sagepub.com/journals-permissions](https://sagepub.com/journals-permissions)

DOI: 10.1177/03000605211014784

[journals.sagepub.com/home/imr](https://journals.sagepub.com/home/imr)

Massimo Mesoletta<sup>1</sup> , Salvatore Allosso<sup>1</sup>,  
Sarah Buono<sup>1</sup>, Filippo Ricciardiello<sup>2</sup> and  
Gaetano Motta<sup>3</sup>

## Abstract

This current report describes a rare clinical case of neuroendocrine carcinoma (NEC) of the larynx with associated Lambert-Eaton myasthenic paraneoplastic syndrome (LEMS). A 68-year-old male patient presented with severe dysphonia and dysphagia. He underwent a total laryngectomy and the excised lesion was extremely large. A pathological examination demonstrated ‘morphological findings of a poorly differentiated carcinoma (G3) with aspects of neuroendocrine differentiation’ (i.e. a poorly differentiated neuroendocrine carcinomas [PD-NEC]). Based on the patient’s medical history and the immunohistochemical findings, he was treated with three cycles of neoadjuvant chemotherapy (cisplatin–etoposide) and then radiotherapy with a total dose of 70 Gy. Of the 10 cases of paraneoplastic syndrome (PNS) related to laryngeal NEC reported in the literature, nine of these syndromes were of an endocrine type. Only one case of PNS associated with laryngeal cancer had a neurological manifestation, which was LEMS. To the best of our knowledge, this current case has only one similar precedent in the literature and it is the second report of an association between a PD-NEC and LEMS. Laryngeal NECs are rare lesions with different prognostic characteristics. The diagnosis should be made using an endocrinological, neurological, radiological and histological multidisciplinary approach. A radical surgical approach is recommended.

<sup>3</sup>Unit of Otorhinolaryngology, University Luigi Vanvitelli, Napoli, Italy

### Corresponding author:

Massimo Mesoletta, Unit of Otorhinolaryngology, Department of Neuroscience, Reproductive Sciences and Dentistry, Federico II University of Naples, 36 Via Gaetano Filangieri, 80121 Naples, Italy.  
Email: [massimo.mesoletta@tin.it](mailto:massimo.mesoletta@tin.it)

<sup>1</sup>Unit of Otorhinolaryngology, Department of Neuroscience, Reproductive Sciences and Dentistry, Federico II University of Naples, Naples, Italy

<sup>2</sup>Unit of Otorhinolaryngology, Hospital Cardarelli, Naples, Italy



Creative Commons Non Commercial CC BY-NC: This article is distributed under the terms of the Creative Commons Attribution-NonCommercial 4.0 License (<https://creativecommons.org/licenses/by-nc/4.0/>) which permits non-commercial use, reproduction and distribution of the work without further permission provided the original work is attributed as specified on the SAGE and Open Access pages (<https://us.sagepub.com/en-us/nam/open-access-at-sage>).

## Keywords

Neuroendocrine carcinoma, Lambert-Eaton myasthenic syndrome, larynx, neurological paraneoplastic syndrome, total laryngectomy

Date received: 19 January 2021; accepted: 12 April 2021

## Introduction

Neuroendocrine carcinomas (NECs) of the larynx are a varied and heterogeneous tumour of rare observation in clinical practice.<sup>1</sup> This neoplasm of ectodermal origin assumes distinct functional and biological behaviours depending on the location, the size of the overall tumour mass and the histological differentiation.<sup>2</sup> Several classifications and nomenclatures have been developed over the years and to date there are still no clear guidelines regarding the management and therapy of patients.<sup>3,4</sup>

The World Health Organization (WHO) classification of 2017 takes into account the histological evaluation and clinical behaviour of neuroendocrine tumours of the larynx, dividing them into: (i) well-differentiated neuroendocrine carcinomas (WD-NEC); (ii) moderately differentiated neuroendocrine carcinomas (MD-NEC); and (iii) poorly differentiated neuroendocrine carcinomas (PD-NEC), which includes (a) small cell neuroendocrine carcinoma (SmCC) and (b) large cell neuroendocrine carcinoma (LCNEC).<sup>5</sup> It is important to acknowledge that the WHO classification, in order to classify the different NECs, also examines in addition to histology and immunohistochemistry for neuroendocrine markers two other parameters that are not used in the NEC of the head and neck district: mitotic activity (expressed in mitosis per 10 high power fields) and proliferative activity (defined as the Ki-67 proliferative index).<sup>5</sup>

Well-differentiated neuroendocrine carcinomas or 'typical carcinoids' account for approximately 5.27% of laryngeal NECs found.<sup>1,2</sup> Among the neuroendocrine laryngeal neoplasms these are the rarest type. Their presentation is almost exclusively supraglottic.<sup>1-3</sup> MD-NECs or 'atypical carcinoids' are the most common type of laryngeal NEC, accounting for 53.7% of laryngeal NECs.<sup>1,6</sup> Their presentation is mostly supraglottic.<sup>1,6</sup> PD-NECs are the second most common type of neuroendocrine carcinomas: 48.6% of the laryngeal NECs found are PD-NEC (more specifically, 41.9% are SmCC and 6.7% are LCNEC). The larynx presentation of this type of tumour is varied.<sup>1-3,6,7</sup>

The current case report describes a patient in whom their SmCC was accompanied by Lambert-Eaton myasthenic syndrome (LEMS), a neurological paraneoplastic syndrome (PNS) characterized by proximal muscle weakness and/or autonomic dysfunction caused by self-immunoglobulin G class antibodies directed against voltage-gated type P/Q calcium channels present on the presynaptic cholinergic endings of the neuromuscular plate, decreasing the release of acetylcholine.<sup>8,9</sup> A PNS can sometimes accompany the neoplasm and therefore be useful in monitoring its evolution.<sup>8-11</sup> A diagnosis is achieved by an endocrinological, neurological, radiological and histological multidisciplinary approach. An early diagnosis of a PNS (and its subsequent treatment) can have positive effects on the general clinical

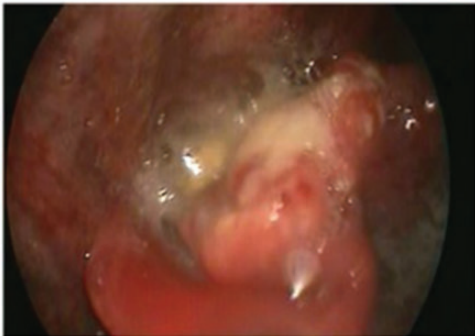
outcome, with more appropriate direct therapy on the tumour and an improvement in quality of life.<sup>8-12</sup> Of the 10 PNS related to laryngeal neuroendocrine carcinoma reported in literature, nine of these syndromes were of an endocrine type.<sup>2</sup> In one case, the PNS linked to the laryngeal cancer (an SmCC) had a neurological manifestation, which was LEMS.<sup>2</sup> To the best of our knowledge, this current case has only one similar precedent in the published literature and it is the second report of an association between a PD-NEC and LEMS.

### Case report

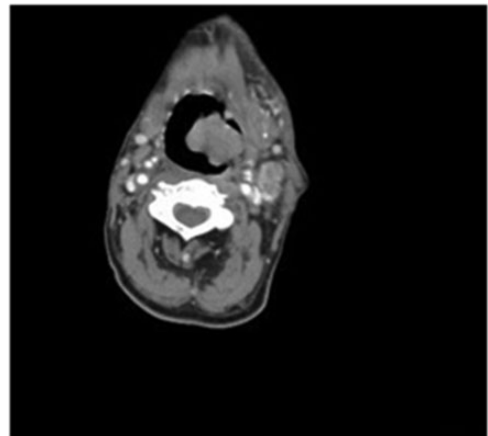
In October 2017, a 68-year-old male patient presented to the Unit of Otorhinolaryngology, Department of Neuroscience, Reproductive Sciences and Dentistry, Federico II University of Naples, Naples, Italy with severe dysphonia and dysphagia during the previous 3 months. Fibrolaryngoscopic examination revealed the presence of a voluminous

ulcer-vegetative neoformation that involved the epiglottis, the anterior commissure, the aryepiglottic folds and the tongue base, with a significant reduction in the respiratory space (Figure 1). Blood chemistry tests revealed positivity for carcinoembryonic antigen and tumour antigen 15-3. The patient's clinical history was characterized by poor personal care, marked asthenia, cachexia, marked xerostomia, constipation and urinary retention. The Karnofsky index was 50%. This clinical condition was explained by the fact that the patient lived in a retirement home, he had dysphagia and was suffering from chronic vascular disease.

A total-body computed tomography examination revealed a voluminous expansive neoformation that presented enhancement after contrast into left lateral wall of the larynx. There were also multiple bilateral lymphadenopathies (Figure 2). A laryngeal biopsy revealed 'morphological findings of poorly differentiated carcinoma (G3) with aspects of neuroendocrine



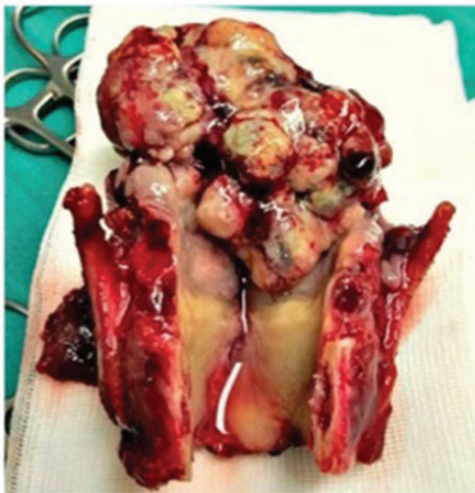**Figure 1.** Fibrolaryngoscopic examination of a 68-year-old male patient that presented with severe dysphonia and dysphagia during the previous 3 months revealed the presence of a voluminous ulcer-vegetative neoformation that involved the epiglottis, the anterior commissure, the aryepiglottic folds and the tongue base, with a significant reduction in the respiratory space. The colour version of this figure is available at: <http://imr.sagepub.com>.



**Figure 2.** Computed tomography examination of a 68-year-old male patient that presented with severe dysphonia and dysphagia during the previous 3 months revealed a voluminous expansive neoformation that presented enhancement after contrast into the left lateral wall of the larynx. There were also multiple bilateral lymphadenopathies.

differentiation' (i.e. PD-NEC). The clinical history and histological examination confirmed the suspicion of associated LEMS. The patient underwent a total laryngectomy with a radical modified neck dissection on the left side with sacrifice of the internal jugular vein and spinal nerve. Selective neck dissection of levels II, III and IV was performed contralaterally. The excised lesion was extremely voluminous (10 cm × 8 cm) (Figure 3).

The postoperative course was uneventful and the patient resumed feeding naturally after approximately 15 days. The histological examination showed a poorly differentiated carcinoma (G3) consisting of small cells with pale cytoplasm, nuclei with finely blotted chromatin and an absence of nucleoli. The immunohistochemical study showed positivity of the neoplastic cells for CK7, synaptophysin and only focal mild positivity for CD56. The results were negative for p40 and p63. The Ki-67 proliferation index was approximately 85%.



**Figure 3.** A 68-year-old male patient that presented with severe dysphonia and dysphagia during the previous 3 months underwent total laryngectomy. The excised lesion was extremely voluminous (10 cm × 8 cm). The colour version of this figure is available at: <http://imr.sagepub.com>.

In the left neck dissection, there were seven lymph nodes infiltrated by carcinoma; and in the right neck dissection, there were two infiltrated lymph nodes. The patient was treated with three cycles of neoadjuvant chemotherapy using the cisplatin–etoposide regimen (130 mg/m<sup>2</sup> cisplatin intravenously per day for 3 days and 45 mg/m<sup>2</sup> etoposide intravenously per day for 2 days every 3 weeks) and then radiotherapy with a total dose of 70 Gy using a linear accelerator.

Approximately 1 month after surgery, a clear improvement in the patient's condition was recorded. After 3 months, the patient resumed walking without the aid of an orthopaedic walker in addition to there being an improvement in autonomic manifestations (constipation, xerostomia, urinary retention). At 3 years after surgery, the patient is still in follow-up at and is free from disease.

The patient's treatment was conducted in accordance with the Declaration of Helsinki and authorized by the institutional review board committee of Federico II University of Naples, Naples, Italy in accordance with the Italian Association of Oncology 2020 (2017/20331). The authors obtained written consent from the patient to publish this case report.

## Discussion

Neuroendocrine carcinomas of the larynx are rare lesions with different prognostic characteristics.<sup>12–14</sup> The most recent WHO classification adequately reflects the genetic and differentiation anomalies underlying the lesions but lacks a correct taxonomy for mixed lesions.<sup>5</sup> Despite the histological similarity of these lesions with other neuroendocrine neoplasms affecting different organs, it is not yet clear whether from the point of view of molecular pathology the laryngeal NECs are identical to the NECs of other organs and whether the NECs of

the head and neck district represent a single nosological spectrum or various distinct pathophysiological entities.<sup>12,13</sup> It is important to consider that the clinical behaviour of these lesions differs from laryngeal squamous cell carcinoma (SCC) due to a higher tendency for distant spread and a higher rate of relapse, both loco-regional and distant.<sup>14,15</sup> There are also differences in the optimal therapeutic management as this differs not only between NEC and SCC but also within the various types of NEC.<sup>8-10,12</sup> A radical surgical approach is recommended in WD-NEC and MD-NEC; and in the latter this is accompanied by laterocervical neck dissection as it is possible to

develop micrometastases in the early stages of this cancer.<sup>14</sup> The most effective approach to the treatment of these lesions is yet to be determined: currently, it seems that only early and aggressive therapies with a multimodal approach can be considered (Table 1).<sup>1-4,6</sup>

Paraneoplastic syndromes related to neuroendocrine carcinomas of the larynx are extremely rare but can cause severe symptoms and almost always correlate with poor prognosis (Table 2).<sup>1-4,6-11</sup> It is debated whether newly diagnosed cases of laryngeal NEC should be screened for one of the PNS already reported in the literature in the 10 existing cases (carcinoid

**Table 1.** Treatment of paraneoplastic syndrome associated with small cell neuroendocrine carcinoma (SCNC).<sup>1-4,6</sup>

Author	Year	Age	Sex	Paraneoplastic syndrome	Type of tumour	Treatment	Follow-up period and outcome
Trotoux et al. <sup>1</sup>	1979	61	Male	SIADH	SCNC	Radiotherapy	DOD 7.7 months
Medina et al. <sup>2</sup>	1984	64	Female	Eaton-Lambert	SCNC	Chemotherapy	DOD 11 months
Bishop et al. <sup>3</sup>	1985	60	Female	ACTH	SCNC	Radiotherapy	DOD 0.5 months
Takeuchi et al. <sup>4</sup>	1989	53	Male	SIADH	SCNC	Radiotherapy and surgery	DOD 15 months
Myers and Kessimian <sup>6</sup>	1995	58	Male	SIADH	SCNC	Chemotherapy	DOD 2 months

SIADH, syndrome of inappropriate secretion of antidiuretic hormone; DOD, dead of disease; ACTH, adrenocorticotrophic hormone.

**Table 2.** Paraneoplastic syndrome associated with laryngeal neuroendocrine neoplasms.<sup>1-4,6-11</sup>

Types of tumour	Authors	Year	Paraneoplastic syndrome
Carcinoid tumour	Wenig et al. <sup>7</sup>	1988	Carcinoid
Atypical carcinoid tumour	Baugh et al. <sup>8</sup>	1986	Carcinoid
	Overholt et al. <sup>9</sup>	1995	Carcinoid
	Kumai et al. <sup>10</sup>	1996	Carcinoid
	Yamanaka et al. <sup>11</sup>	1997	Carcinoid
	Small cell neuroendocrine carcinoma	Trotoux et al. <sup>1</sup>	1979
	Medina et al. <sup>2</sup>	1984	Eaton-Lambert
	Bishop et al. <sup>3</sup>	1985	Cushing
	Takeuchi et al. <sup>4</sup>	1989	Schwartz-Bartter
	Myers and Kessimian <sup>6</sup>	1995	Schwartz-Bartter
Paraganglioma	No reports		

syndrome, syndrome of inappropriate secretion of antidiuretic hormone, Lambert-Eaton, ectopic adrenocorticotrophic hormone) (Table 1).<sup>1-4,6</sup> Considering these 10 cases, the estimated incidence of PNS in patients with a laryngeal NEC is approximately 2.3%.<sup>1-4,6</sup> Patients with MD-NEC or PD-NEC (SmCC, 5%) have a higher probability of also having associated PNS, unlike patients with WD-NEC in whom the probability of having NEC-related PNS is lower.<sup>9,11,12</sup> Of the 10 cases of PNS related to laryngeal neuroendocrine carcinoma reported in literature, nine of these syndromes were of an endocrine type (Table 1).<sup>1-4,6</sup> Only one case of PNS linked to laryngeal cancer (an SmCC) had a neurological manifestation, which was LEMS.<sup>2</sup> This current case report presents the second patient with a neurological manifestation in who the laryngeal cancer was first treated with surgery. The previously reported patient that had a neurological manifestation with a laryngeal cancer was treated with two courses of vincristine sulphate, doxorubicin and cyclophosphamide and had a remarkable response for both the primary tumour and the cervical lymph node metastases.<sup>2</sup> Following chemotherapy, the patient was given radiotherapy.<sup>2</sup> The primary tumour received 6095 rad and the neck received 5400 rad.<sup>2</sup> At the completion of radiotherapy, there was no evidence of disease in the larynx or the neck.<sup>2</sup> The patient's myasthenic syndrome progressively improved as the treatment of the tumour progressed.<sup>2</sup> After 7 months, the patient received three more courses of chemotherapy.<sup>2</sup> After 7 month, the patient was admitted to the hospital complaining of diplopia. A neurological examination then disclosed dysfunction of the third, fourth and sixth cranial nerves.<sup>2</sup> Her neurological status deteriorated rapidly; seizures developed, she went into a coma, and she died 7 days later.<sup>2</sup>

Paraneoplastic syndromes are clinical manifestations that reveal the presence of a carcinoma or that appear during its evolution, but have no direct correlation with the tumour or its metastases.<sup>10,12,14</sup> For a large proportion of them, a precise mechanism underlying their development has not yet been identified, but in some cases, PNS are the consequence of an ectopic synthesis of a hormone or a mediator by the tumour, while the structures affected by the symptomatology are not affected by the tumour.<sup>10-15</sup>

Neuroendocrine carcinomas of the larynx are rare lesions with different prognostic characteristics. PNS can rarely accompany the neoplasm and therefore be useful in monitoring its evolution. The diagnosis should be made using a multidisciplinary approach.<sup>14-16</sup> An early diagnosis of a PNS and its treatment can have positive effects on the general clinical outcome, with more appropriate direct therapy on the tumour and an improvement in quality of life.<sup>8,9,16,17</sup>

### Declaration of conflicting interest

The authors declare that there are no conflicts of interest.

### Funding

This research received no specific grant from funding agency in the public, commercial, or not-for-profit sectors.

### ORCID iD

Massimo Mesolella  <https://orcid.org/0000-0001-5278-6998>

### References

1. Trotoux J, Glickmanas M, Sterkers O, et al. Schwartz-Bartter syndrome. Presentation of a sub-glottal small cell laryngeal carcinoma. *Ann Otolaryngol Chir Cervicofac* 1979; 96: 349-358 [Article in French, English abstract].



2. Medina JE, Moran M and Goepfert H. Oat cell carcinoma of the larynx and Eaton-Lambert syndrome. *Arch Otolaryngol* 1984; 110: 123–126.
3. Bishop JW, Osamura RY and Tsutsumi Y. Multiple hormone production in an oat cell carcinoma of the larynx. *Acta Pathol Jpn* 1985; 35: 915–923.
4. Takeuchi K, Nishii S, Jin CS, et al. Anaplastic small cell carcinoma of the larynx. *Auris Nasus Larynx* 1989; 16: 127–132.
5. Gale N, Poljak M and Zidar N. Update from the 4th Edition of the World Health Organization Classification of Head and Neck Tumours: What is New in the 2017 WHO Blue Book for Tumours of the Hypopharynx, Larynx, Trachea and Parapharyngeal Space. *Head Neck Pathol* 2017; 11: 23–32.
6. Myers TJ and Kessimian N. Small cell carcinoma of the larynx and ectopic antidiuretic hormone secretion. *Otolaryngol Head Neck Surg* 1995; 113: 301–304.
7. Wenig BM, Hyams VJ and Heffner DK. Moderately differentiated neuroendocrine carcinoma of the larynx. A clinicopathologic study of 54 cases. *Cancer* 1988; 62: 2658–2676.
8. Baugh RF, Wolf GT, Beals TF, et al. Small cell carcinoma of the larynx: results of therapy. *Laryngoscope* 1986; 96: 1283–1290.
9. Overholt SM, Donovan DT, Schwartz MR, et al. Neuroendocrine neoplasms of the larynx. *Laryngoscope* 1995; 105: 789–794.
10. Kumai M, Arakawa T, Nakane T, et al. Serum serotonin elevated carcinoid tumor of the larynx. *Larynx Jpn* 1996; 8: 53–55.
11. Yamanaka J, Yao K and Kohno H. A case of primary laryngeal carcinoid with the carcinoid syndrome and rapid clinical course. *Kitasato Med* 1997; 27: 110–113.
12. Strosberg C, Ferlito A, Triantafyllou A, et al. Update on Neuroendocrine Carcinomas of the Larynx. *Am J Clin Pathol* 2019; 152: 686–700.
13. López F, Hunt JL, Nixon IJ, et al. How phenotype guides management of the neuroendocrine carcinomas of the larynx. *J Laryngol Otol* 2018; 132: 568–574.
14. Iqbal MS, Paleri V, Moor J, et al. Small cell neuroendocrine carcinoma of larynx: case series and literature review. *J Laryngol Otol* 2015; 129: 910–915.
15. Mesoilella M, Allosso S, Varricchio S, et al. Small-Cell Carcinoma of Nasopharynx: A Case Report of Unusual Localization. *Ear Nose Throat J* 2020: 145561320973780.
16. Mesoilella M, Iorio B, Misso G, et al. Role of perineural invasion as a prognostic factor in laryngeal cancer. *Oncol Lett* 2016; 11: 2595–2598.
17. Mesoilella M, Iorio B, Landi M, et al. Overexpression of chromatin assembly factor-1/p60 predicts biological behaviour of laryngeal carcinomas. *Acta Otorhinolaryngol Ital* 2017; 37: 17–24.