

CASE SERIES AND REPORTS

Mucoepidermoid carcinoma of the base of tongue

Carcinoma mucoepidermoide della base della lingua

M. MESOLELLA¹, M. IENGO¹, D. TESTA², A.M. DI LULLO¹, G. SALZANO³, F.A. SALZANO³¹ENT Department, University "Federico II", Napoli, Italy; ²ENT Department Second University, Napoli, Italy; ³ENT Department, University of Salerno

SUMMARY

Mucoepidermoid carcinoma (MEC) is the most common malignant, locally-invasive tumour of the salivary glands, and accounts for approximately 35% of all malignancies of the major and minor salivary gland. Minor salivary glands are scattered in different areas of the oral cavity such as palate, retromolar area, floor of the mouth, buccal mucosa, lips and tongue. MECs of tongue base are not common. We present a rare case of MEC localised at the tongue base in a 42-year-old Caucasian woman and discuss the histopathological types, management and review the literature. Adequate intra-oral excision was the treatment of choice in this case and in low-grade MEC. Prognosis of MEC is a function of the histological grade, adequacy of excision and clinical staging.

KEY WORDS: Mucoepidermoid carcinoma • Tongue base • Minor salivary glands • Intra-oral approach

RIASSUNTO

Il carcinoma mucoepidermoide è il più comune tumore maligno, localmente invasivo delle ghiandole salivari. Esso si presenta approssimativamente nel 35% di tutti i tumori delle ghiandole salivari maggiori e minori. Per le ghiandole salivari minori si localizza principalmente nella cavità orale, nel palato, nell'area retro molare, nel pavimento della bocca, sulla mucosa buccale, sulle labbra e sulla lingua. Il carcinoma muco epidermoide della base della lingua è alquanto raro. Presentiamo un raro caso di carcinoma muco epidermoide della base della lingua occorso in una donna di 42 anni giunta alla nostra osservazione. Un'adeguata escissione del tumore per via intraorale ha rappresentato il trattamento più adeguato per il nostro caso e per i carcinomi muco epidermoidi a basso grado di malignità. In generale la prognosi del carcinoma muco epidermoide è in relazione al grado istologico, all'adeguatezza dell'escissione chirurgica e allo stadio clinico.

PAROLE CHIAVE: *Carcinoma mucoepidermoide • Base lingua • Ghiandole salivari minori • Approccio intraorale*

Acta Otorhinolaryngol Ital 2015;35:58-61

Introduction

Mucoepidermoid carcinoma (MEC) is malignant, locally-invasive tumour of the salivary glands¹. It accounts for approximately 35% of all malignancies of the major and minor salivary glands, especially in the parotid gland^{1,2}. MECs can also occur in the submandibular and minor salivary glands³. When MEC arises in minor salivary glands, it can be located in different areas such as palate, retromolar area, floor of the mouth, buccal mucosa, lips and tongue³⁻⁵. Although MECs of tongue base are not common, they constitute more than 50% of malignant lesions of salivary glands in this region⁶⁻⁹. The mean age of patients with MEC is 48 years (range 12-82 years) with peaks in the fifth and sixth decades of life, although it may occur at any age^{1,2}. In this report, we present a rare case of 42-year-old woman with MEC of the tongue base and discuss the histopathological types and management of MEC.

Case report

A 42-year-old woman was referred to the ENT Department of University of Naples. The patient complained of an asymptomatic nodule of the right side of tongue base for 4 months duration. The mass gradually increased in size during this time. The patient complained of dysphagia, but it was not associated with any bleeding or pain (Fig. 1). There was no history of weight loss. The patient denied the use of tobacco and alcohol at any point in her life. Clinical examination showed a non-ulcerated, firm, exophytic, oval mass on the dorsal surface in the right posterior-lateral base of the tongue that was seen easily when the patient protruded her tongue (Fig. 1). The mass was about 3.2 cm crossing the midline, and had an irregular surface. Neck examination showed no palpable lymph nodes. Clinical stage was established as II (T2N0M0).

Computed tomography (CT) showed a soft tissue mass on the right side of tongue base and crossing the midline. It was

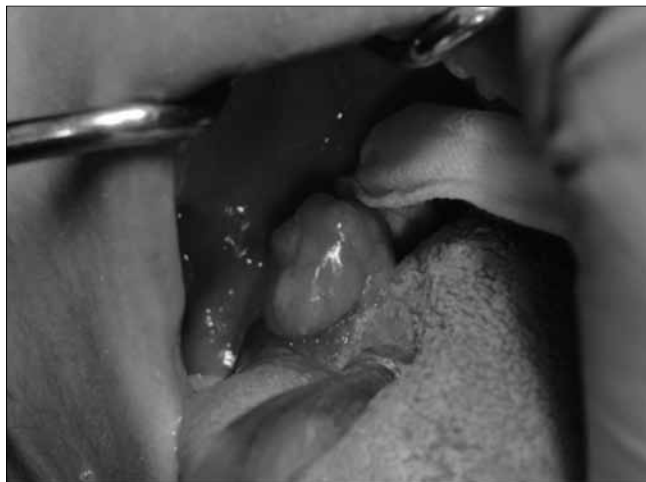

Fig. 1. Asymptomatic, non-ulcerated, firm, exophytic, oval mass on the dorsal surface in the right posterior-lateral base of the tongue.

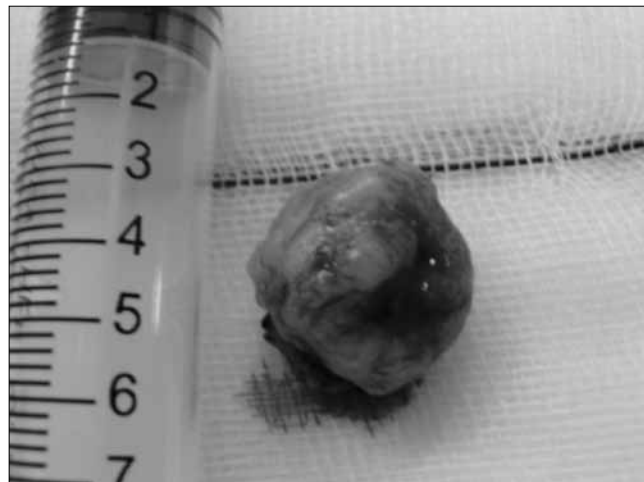


Fig. 3. Complete transoral excision of nodular lesion with intact overlying mucosa. Histological examination confirmed low-grade MEC.

infiltrating the muscles, but was not involving the whole thickness of the tongue. No loco-regional adenomegalies were detected. Magnetic resonance imaging (MRI) showed an irregular oval-shaped mass, 3 cm in diameter arising from the right tongue base (Fig. 2). Findings on chest radiographs and laboratory tests were within normal limits. Complete transoral excision (Fig. 3) was performed under general anaesthesia. The post-surgical course was uneventful. The patient started swallowing foods and water on the second postoperative day. Histopathological examination of the specimen confirmed a slightly raised nodular lesion with intact overlying mucosa measuring 3 x 1.6 x 1.8 cm

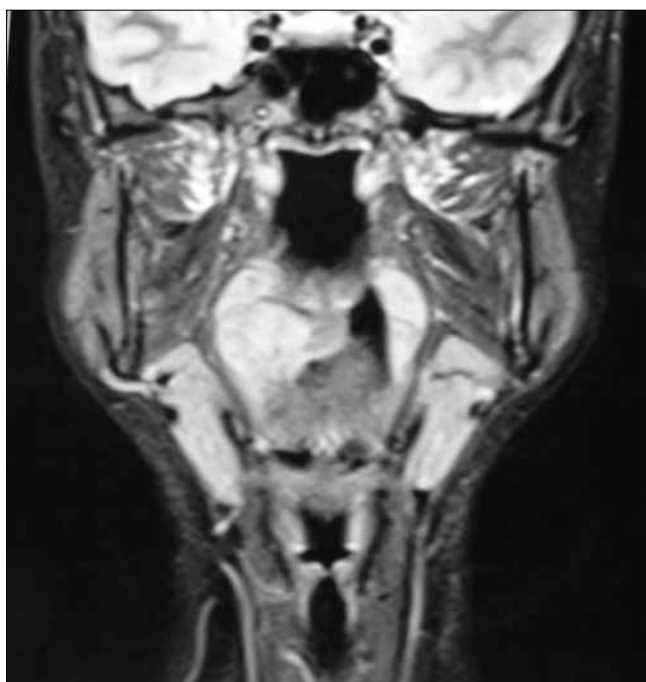


Fig. 2. MRI shows an irregular oval-shaped mass, 3 cm in diameter, arising from the right tongue base.

of a low-grade mucoepidermoid carcinoma with negative margins. No adjuvant therapy was offered due to the low histological grade and clear resection margins. Follow-up for 3 years showed no recurrence. Informed consent was obtained from the patient to publish the case.

Discussion

The first report on mucoepidermoid tumours was by Stewart³: he divided these tumours into relatively favourable and highly unfavourable. The classification of MECs into low, intermediate and high grade was based on the relative proportion of cell types^{1,2}.

MEC of the minor salivary glands is composed histologically of three cell types: mucous cells, epidermoid squamous cells and poorly differentiated intermediate cells that have the ability to differentiate into either mucous-producing or epidermoid cells^{1,2}. When the epidermoid element predominates, the histological appearance of the tumour may closely resemble that of squamous cell carcinoma on histological examination, and it is thus classified as a high-grade MEC tumour. Instead, the presence of mucin-producing cells within a predominantly cystic architecture is regarded as low-grade MEC tumour. Intermediate-grade tumours are less cystic and show a greater tendency to form large, more irregular nests or sheets of squamous cells and often have a more prominent intermediate cell population¹.

Auclair et al.⁶ studied the grading criteria of minor salivary glands MECs. The histopathological features that indicated high-grade behaviour were:

- an intra-cystic component of < 20% (+ 2 points);
- four or more mitotic figures per 10 high power field (+ 3 points);
- neural invasion (+ 2 points);
- necrosis (+3 points);

- cellular anaplasia (+ 4 points)².

According to this grading scale, tumours with a:

- score of 0-4 were considered low-grade;
- scores 5-6 were considered intermediate (between low-grade and high-grade);
- scores ≥ 7 indicated highly aggressive behaviour.

The standard treatment for all grades of MEC is surgical resection^{1,2,6,8,10}. The treatment of choice for MECs of minor salivary glands with low to intermediate-grade is a radical surgery alone by wide local excision intraoral, if it can be achieved, with adequate tumour-free margins. High-grade tumours require more aggressive surgery with or without postoperative radiotherapy and chemotherapy^{2,8}. The methods of surgical removal of neoplasm of base of the tongue include transmandibular and/or transcervical approaches and an intraoral route. The transmandibular approaches have the advantage of good exposure of the surgical site, but may result in complications such as extraoral scar formation, damage of joint components and more traumatic access with consequent high morbidity and poor cosmetic and functional outcomes. The intraoral route may avoid these problems and allow the possibility to deintensify adjuvant treatments, but provides a smaller surgical site. Recently, transoral robotic surgery has been used with good results in the treatment of selected T1-T2 cases of oropharyngeal tumours of the base of the tongue, but one of the main criticisms against using robotic surgery is related to the cost of the procedure¹¹.

During follow-up, patients often develop local or regional recurrence and distant metastases. Metastasis is primarily to subcutaneous tissues, lymph nodes, bone and lung^{4,10}. Generally, lymphatic spread can be common in high-grade MEC. Previously, high-grade MEC has been associated with poorer regional control because it frequently infiltrates surrounding structures, recurs, or metastasises⁴. Management of the neck and the need to assess it during long-term follow-up of MEC has been emphasised¹². Neck dissection is not indicated for patients with low grade mucoepidermoid carcinoma¹¹⁻¹³. In a study of 48 patients from the MD Anderson Cancer Center, the presence of lymphatic spread was closely correlated with increasing histological grade: 0% for low-, 22% for intermediate- and 72% for high-grade tumours¹⁴. Thus, many authors believe that adjuvant radiotherapy (RT) is recommended for high-grade tumours⁴. We believe that post-operative radiotherapy should be given to patients with high-grade tumours and in those invading or in close resection margins, lymph node metastases, perineural or lymphovascular invasion, or both. Treatment with chemotherapy is indicated for patients with metastatic disease and those who are not candidates for salvage surgery or RT^{4,14}. It is generally accepted that, for high-grade MECs, radiotherapy combined with surgery should achieve local control of the disease and good survival rates². We believe that the prognosis of MECs is a function of the histological grade, adequacy of excision and clinical staging.

Low-grade tumours have a 5-year survival rate of 76-95%, with the exception of the submandibular gland MECs that demonstrate a more benign nature². Intermediate and high-grade tumours have a tendency to infiltrate, recur and metastasise with reported 5-year survival of 30-50%^{4,14}. Most high-grade MECs show malignant behaviour within the first 5 years after surgery. Although it is rare, cases of recurrence have been reported 15 years after initial excision, indicating the requirement of long-term follow-up. In our case, surgical excision of the tumour was done transorally because there was no lymph node metastasis (clinically and radiologically), and there is no need to perform neck dissection as suggested by NCCN guidelines¹¹ in low-grade MEC. However, Conley¹⁰ reported that lymph node metastases occur in nearly three-quarters of patients with high-grade cancer. Thus, after surgery, radiotherapy may reduce the risk of loco-regional recurrence in cases of advanced tumours with positive resection margins or high-grade malignancy. Jones advised performance of selective neck dissection for patients with high-grade or large lesions and a N0 neck, and radical dissection for patients with positive neck nodes.

Follow-up of our case for 3 years showed no recurrence. However, some authors recommended follow-up for life as recurrence may be delayed for many years^{1,2,15}.

Conclusions

MECs are rare tumours of the salivary glands. No specific guidelines have evolved for the management of these tumours, but surgical excision is mandatory along with a long-term follow-up. In particular, low and intermediate-grade MECs of salivary glands tend to have a favourable outcome compared with high-grade MECs that have a greater tendency to recur and metastasise. The clinical stage continues to be both a prognostic factor for overall survival and a predictive factor of distant metastases. Therefore, both correct clinical staging and immunohistochemical findings associated with careful follow-up are important factors in minor salivary gland malignancies, especially high-grade MECs, for appropriate management of these tumours. In our case, surgical excision of the tumour was done transorally. This approach is safe and can radically remove limited oropharyngeal tumours of the tongue base with good functional outcomes compared with transmandibular and/or transcervical approaches.

References

- 1 Triantafyllidou K, Dimitrakopoulos J, Iordanidis F, et al. *Mucoepidermoid carcinoma of minor salivary glands: a clinical study of 16 cases and review of the literature*. Oral Dis 2006;12:364-70.
- 2 Brandwein MS, Ivanov K, Wallace DI, et al. *Mucoepidermoid carcinoma: a clinicopathologic study of 80 patients with special reference to histological grading*. Am J Surg

- Pathol 2001;25:835-45.
- ³ Stewart FW, Foote FW, Becker WF. *Mucoepidermoid tumors of salivary glands*. Ann Surg 1945;122:820-44.
 - ⁴ Eversole LR. *Mucoepidermoid carcinoma: review of 815 reports cases*. J Oral Surg 1970;28:490-45.
 - ⁵ Caccames JF, Ord RA. *Paediatric mucoepidermoid carcinoma of the palate*. Int J Oral Maxillofacial Surg 2002;31:136-9.
 - ⁶ Auclair PL, Goode RK, Ellis GL. *Mucoepidermoid carcinoma of intraoral salivary glands. Evaluation and application of grading criteria in 143 cases*. Cancer 1992;69:2021-30.
 - ⁷ Abdel-Aziz M. *Mucoepidermoid carcinoma of the tongue in a child*. Int J Pediatr Otorhinolaryngol Extra 2012;7:6-8.
 - ⁸ Sobani ZA, Junaid M, Ghaffar S, et al. *Mucoepidermoid carcinoma of the base of tongue*. J Pak Med Assoc 2011;61:945-7.
 - ⁹ Leong SCL, Pinder E, Sasae R, et al. *Mucoepidermoid carcinoma of the tongue*. Singapore Med J 2007;48:e272-4.
 - ¹⁰ Conley J, Tinsley PP. *Treatment and prognosis of mucoepidermoid carcinoma in the paediatric age group*. Arch. Otolaryngol 1985;111:322-4.
 - ¹¹ Mercate G, Ruscito P, Pellini R, et al. *Transoral robotic surgery (TORS) for tongue base tumours*. Acta Otorhinolaryngol Ital 2013;33:230-5.
 - ¹² Andrews KV, Eveson JW. *Myokymia (fasciculation) of the tongue as a unique presentation of mucoepidermoid carcinoma*. Int J Oral Maxillofac Surg 2007;36:79-81.
 - ¹³ *NCCN Guidelines: clinical practice guidelines in oncology. Head and Neck Cancer*. Version I. 2013.
 - ¹⁴ Mc Hugh CH, Roberts DB, El-Naggar AK, et al. *Prognostic factors in mucoepidermoid carcinoma of the salivary glands*. Cancer 2012;15:3928-36.
 - ¹⁵ Mesoletta M, Luce A, Marino A, et al. *Treatment of c-kit positive adenoid cystic carcinoma of the tongue: a case report*. Oncol Lett 2014;8:309-12.

Received: January 21, 2014 - Accepted: April 29, 2014

Address for correspondence: Massimo Mesoletta, ENT Department, University "Federico II", via G. Filangieri 36, 80121 Naples, Italy. Tel. +39 081 404545. Fax +39 081 7463227. E-mail: massimo.mesoletta@tin.it