









Intravitreal dexamethasone implant one month before versus concomitant with cataract surgery in patients with diabetic macular oedema: the dexcat study

Matteo Fallico,^{1,2}  Teresio Avitabile,¹ Niccolò Castellino,¹ Antonio Longo,¹ Andrea Russo,¹ Vincenza Bonfiglio,¹  Francesca Parisi,¹ Claudio Furino,³  Giacomo Panozzo,⁴ Vincenzo Scordia,⁵ Adriano Carnevali,⁵ Francesco Bandello,⁶  Maurizio Battaglia Parodi,⁶ Gilda Cennamo,⁷ Salvatore Cillino,⁸  Maria Vadalà,⁸ Valentina Sunseri Trapani,⁸ Carlo Cagini,⁹  Tito Fiore,⁹ Marco Lupidi,⁹ Mariacristina Parravano,¹⁰  Monica Varano,¹⁰ Paola Giorno,¹⁰ Francesco Boscia,¹¹ Ermete Giancipoli,¹¹ Chiara Eandi,^{12,13}  Yannick Le Mer¹³ and Michele Reibaldi^{1,12}

¹Department of Ophthalmology, University of Catania, Catania, Italy

²Eye Unit, Southampton University Hospital, Southampton, UK

³Department of Ophthalmology, University of Bari, Bari, Italy

⁴Ophthalmology Unit, Bussolengo Hospital, Bussolengo, Verona, Italy

⁵Department of Ophthalmology, University of "Magna Graecia", Catanzaro, Italy

⁶Department of Ophthalmology, University Vita-Salute Hospital San Raffaele, Milano, Italy

⁷Department of Public Health, University of Naples Federico II, Naples, Italy

⁸Department of Experimental Biomedicine and Clinical Neuroscience, Ophthalmology Section, University of Palermo, Palermo, Italy

⁹Division of Ophthalmology, Department of Surgery and Biomedical Science, S Maria della Misericordia Hospital, University of Perugia, Perugia, Italy

¹⁰Department of Ophthalmology, IRCCS - Fondazione Bietti, Rome, Italy

¹¹Department of Ophthalmology, University of Sassari, Sassari, Italy

¹²Department of Surgical Science, Eye Clinic, University of Torino, Torino, Italy

¹³Department of Ophthalmology, Fondation Ophtalmologique A. De Rothschild, Paris, France

ABSTRACT.

Purpose: To report clinical outcomes of two different timings of intravitreal dexamethasone (DEX) implant administration for prevention of diabetic macular oedema (DME) worsening following cataract surgery.

Methods: This multicentre, retrospective study included patients with DME who received an intravitreal DEX implant 1 month before cataract surgery, 'precataract DEX' group, or at the time of cataract surgery, 'concomitant treatments' group. Inclusion criteria were a follow-up ≥ 3 months and ophthalmological examination with optical coherence tomography (OCT) imaging at baseline (cataract surgery) and throughout follow-up. Anatomical improvement was considered to be a decrease in OCT central subfield (CSF) thickness $\geq 20\%$ compared to baseline. The primary outcomes were anatomical and functional results at 3 months.

Results: Two hundred twenty-one patients were included: 136 in the 'precataract DEX' group and 85 in the 'concomitant treatments' group. At 3 months, a reduction of CSF thickness $\geq 20\%$ was found in 7.3% of eyes in the 'precataract DEX group' and in 83.7% of eyes in the 'concomitant treatments' group ($p < 0.001$), with mean CSF thickness lower in the latter group ($371 \pm 52 \mu\text{m}$ versus $325 \pm 57 \mu\text{m}$, $p < 0.001$). At 3 months, mean best-corrected visual acuity had improved from baseline in both groups ($p < 0.001$), with no difference between groups ($p = 0.20$). No serious systemic adverse events were reported.

Conclusion: Both approaches prevented a worsening of DME, showing a comparable visual outcome. Dexamethasone (DEX) implant given at the same time as cataract surgery provided a better anatomical outcome.

Key words: cataract surgery – dexamethasone implant – diabetes – diabetic macular oedema

Acta Ophthalmol.

© 2020 Acta Ophthalmologica Scandinavica Foundation. Published by John Wiley & Sons Ltd

doi: 10.1111/aos.14516

Introduction

The approach to cataract surgery in patients affected by diabetic macular oedema (DME) represents an issue of great clinical relevance, since the prevalence of cataract is higher in diabetic patients (Obrosova et al. 2010; Furino et al. 2017), and the surgery itself has been shown to increase the progression of DME (Romero-Aroca et al. 2006; Boscia et al. 2017; Denniston et al. 2017; Calvo et al. 2018).

The sustained-release 0.7 mg dexamethasone (DEX) intravitreal implant (Ozurdex®; Allergan, Inc., Irvine, CA, USA) proved effective in preventing a worsening of DME following cataract surgery.

A few studies have evaluated the effect of intravitreal DEX implant on the DME when administered at the same time of cataract surgery, showing encouraging functional and anatomical results (Agarwal et al. 2013; Furino et al. 2017; Panozzo et al. 2017; Calvo et al. 2018).

Similarly, intravitreal DEX implant administered 1 month before the cataract surgery has been reported to prevent an aggravation of the DME in the postoperative period. (Malclès et al. 2017).

Hitherto, no study has been conducted to compare different timings of DEX administration with regard to cataract surgery in patients with DME.

The purpose of this retrospective study was to report clinical outcomes of the use of intravitreal DEX implant in patients with DME scheduled for cataract surgery, comparing DEX implant administered 1 month before cataract surgery versus DEX implant combined to cataract surgery.

Materials and Methods

This retrospective, non-randomized, multicentre study was conducted at 10 clinical sites in Italy: the Eye Clinic of the University of Bari, the Ophthalmology Unit of Bussolengo General Hospital (Verona), the Eye Clinic of the University of Catania, the Eye Clinic of the University of Catanzaro, the Eye Clinic of the Scientific Institute San Raffaele (Milan), the Eye Clinic of the University of Naples ‘Federico II’, the Eye Clinic of the University of Palermo, the Eye Clinic of the University of Perugia, the Eye Clinic of Bietti Eye Foundation-IRCCS Rome and the

Eye Clinic of the University of Sassari; and 1 in France: the Department of Ophthalmology, Fondation Ophtalmologique A. De Rothschild, Paris. Institutional review board approval was obtained at the coordinating centre (University of Catania) and at each participating site. The study protocol and data collection adhered to the tenets of the Declaration of Helsinki.

All consecutive patients with centre-involved DME who received an intravitreal DEX implant 30 ± 7 days before cataract surgery or at the time of cataract surgery, between November 2016 and January 2019, were considered for eligibility. Central-involved DME was defined as a central subfield (CSF) thickness ≥ 310 µm on spectral-domain optical coherence tomography (SD-OCT) (Cirrus [Carl Zeiss Meditec], Spectralis [Heidelberg], or Optovue RTVue [Optovue]) (DRCR Network Authors/Writing Committee et al. 2013).

Inclusion criteria were as follows: uneventful cataract surgery consisting of phacoemulsification technique with in-bag intraocular lens implant; post-cataract follow-up ≥ 3 months including best-corrected visual acuity (BCVA) measurement and OCT imaging; complete ophthalmic examination and OCT scan performed at baseline, 1 month, 2 months and 3 months after cataract surgery. Baseline was considered to be the day of cataract surgery.

The following exclusion criteria were applied: age less than 18 years; proliferative diabetic retinopathy; presence of other macular or retinal diseases which may affect visual outcome; previous ocular surgery in the 6 months before cataract surgery; vitrectomized eye; previous macular laser; intravitreal

anti-VEGF injection in the 4 months before cataract surgery; DEX implant or intravitreal triamcinolone acetonide in the 6 months before cataract surgery; intravitreal treatment or macular laser performed throughout 3 months follow-up; and poor quality imaging. Patients not receiving postcataract non-steroidal anti-inflammatory drugs (NSAIDs) were also excluded.

The patient population was divided into two groups according to the timing of intravitreal DEX implant. In the first group, designated ‘precataract DEX’, consisted of patients who had undergone DEX implant 30 ± 7 days before cataract surgery. The second group, named ‘concomitant treatments’, was composed of patients who received intravitreal DEX implant simultaneously with cataract surgery, which was in all cases at the end of the procedure.

The complete ophthalmic examination included BCVA on Early Treatment Diabetic Retinopathy Study (ETDRS) charts, which was converted to the logarithm of the minimum angle of resolution (logMAR), intraocular pressure (IOP) measurement with Goldmann applanation tonometry, slit-lamp biomicroscopic examination, fundus examination and OCT imaging.

Patient demographics, diabetes duration, haemoglobin (Hb)A1c value, hypertension history, along with preoperative, operative and postoperative ophthalmic data were extracted from the electronic medical records. In each centre, 2 experienced investigators reviewed the charts of each patient independently. Chart reviewers were blinded with regard to the study objective.

Anatomical improvement was considered a decrease in CSF

Table 1. Baseline demographic and clinical characteristics in the two groups.

	Previous DEX implant (n = 136)	Concomitant DEX implant (n = 85)	p-value
Mean age, years ± SD	70 ± 7	69 ± 12	0.778
Gender, male no. (%)	82 (60.3)	48 (56.5)	0.578
Diabetes type 1, no. (%)	18 (13.2)	5 (5.9)	0.112
Mean HbA1c, %±SD	7.8 ± 1.0	7.6 ± 1.0	0.200
Diabetes duration, years ± SD	20.7 ± 10.9	18.6 ± 7.5	0.120
Arterial hypertension, no. (%)	82 (60.3)	50 (58.8)	0.888
Naive, no. (%)	31 (22.8)	25 (29.4)	0.340
Mean time from DEX implant to cataract surgery, days ± SD	27.4 ± 7.3	-	
Baseline BCVA, logMAR ± SD	0.70 ± 0.27	0.82 ± 0.26	0.001
Mean baseline CMT, µm	368 ± 38	480 ± 101	<0.001
Mean baseline IOP, mmHg	15.5 ± 3.0	14.4 ± 2.6	0.006

BCVA = best-corrected visual acuity, CMT = central macular thickness, DEX = dexamethasone implant, HbA1c = haemoglobin A1c, IOP = intraocular pressure, SD = standard deviation.

thickness $\geq 20\%$ compared to baseline. Anatomical worsening was considered an increase in CSF thickness $\geq 20\%$ from baseline. Stable central-involved DME was defined as a CSF thickness change $< 20\%$ (Bressler et al. 2012).

The primary objective of the study was to compare anatomical and functional outcomes between the two groups, looking at the difference in rate of patients showing anatomical improvement and worsening at 3 months from cataract surgery in the two groups, together with the mean change in CSF thickness and BCVA from baseline to 3 months after cataract surgery in the two groups. Secondary outcomes included the rate of adverse events, mean IOP change, postoperative IOP raise > 21 mmHg, subgroup analysis related to clinical variables, such as 'naïve' condition. Change in BCVA and CSF thickness at 1 month and two-month follow-up visit were also analysed as secondary outcomes.

The baseline parameters of the two groups were compared by the t-test or chi-square test.

In each group, the values of BCVA, CSF thickness and IOP detected at all time-points were compared by analysis of variance (ANOVA). If significant, multiple comparisons were made by the Tukey honestly significant difference (HSD) test.

Between the two groups, the values detected at each time-point were compared by unpaired t-test.

The rate of eyes with improved, stable or worsened CSF thickness at 3 months from cataract surgery was evaluated and compared between the two groups by the chi-square test.

p-Values lower than 0.05 were considered as statistically significant. The statistical analyses were performed by SPSS software (version 21.0).

Results

Baseline

Overall, 221 patients affected by DME were included in the study: 136 in the 'precataract DEX' group and 85

in the 'concomitant treatments' group. Baseline demographic and clinical characteristics are displayed in Table 1.

At baseline, mean BCVA in the 'precataract DEX' group was better than in the 'concomitant treatments' group (0.70 ± 0.27 logMAR versus 0.82 ± 0.26 logMAR, respectively; $p < 0.001$). Likewise, eyes in the 'precataract DEX' group showed a lower CSF thickness compared to the other group ($368 \pm 38 \mu\text{m}$ versus $480 \pm 101 \mu\text{m}$, $p < 0.001$) (Table 1).

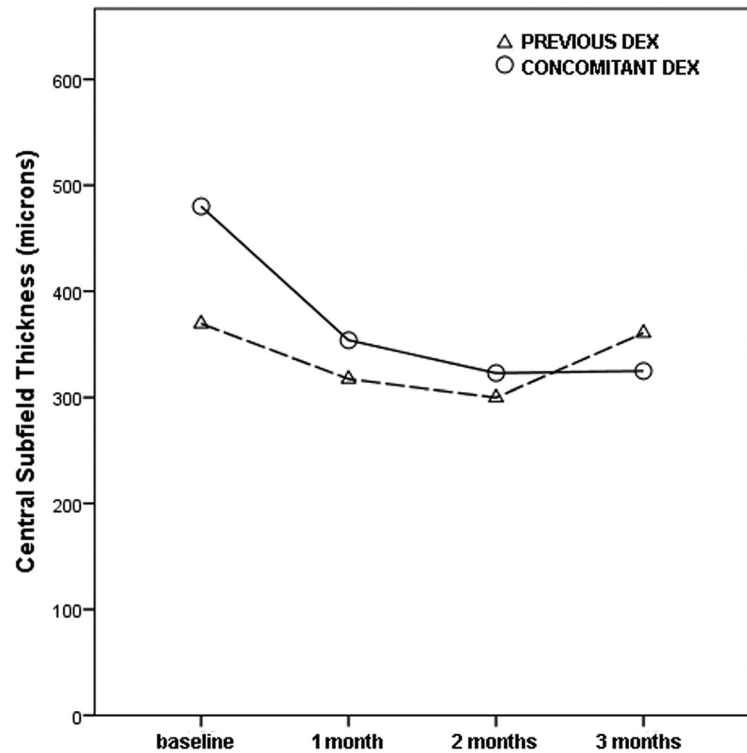


Fig. 2. Change in central subfield thickness over time in the two groups.

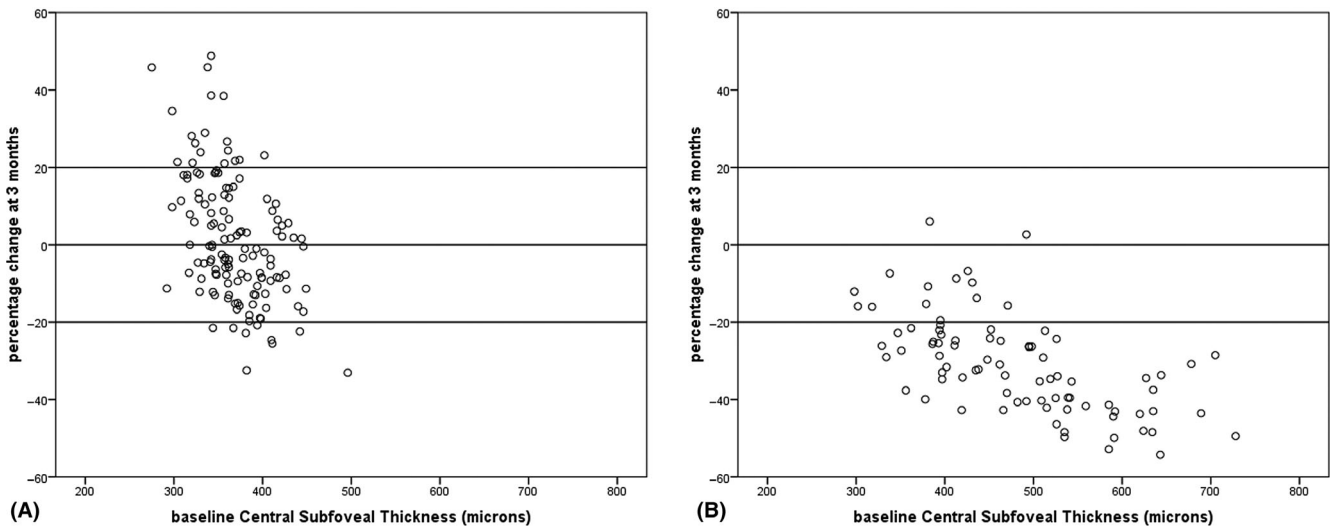


Fig. 1. Percentage change in central subfield thickness at 3 months: A shows 'precataract DEX group'; B shows the 'concomitant treatments' group.

Three-month results

At 3 months from cataract surgery, a CSF thickness reduction $\geq 20\%$ was found in 7.3% of eyes in the ‘precataract DEX group’ and in 83.5% of eyes in the ‘concomitant treatments’ group ($p < 0.001$) (Fig. 1). The mean CSF thickness was greater in the ‘precataract DEX group’ compared to the ‘concomitant treatments’ group ($371 \pm 52 \mu\text{m}$ versus $325 \pm 57 \mu\text{m}$, $p < 0.001$) and was lower than baseline only in the ‘concomitant treatments’ group ($p < 0.001$) (Fig. 2; Table 2).

Mean BCVA improved to $0.44 \pm 0.23 \text{ logMar}$ in the ‘precataract DEX group’ and to $0.40 \pm 0.25 \text{ logMar}$ in the ‘concomitant treatments’ group ($p < 0.001$ versus baseline), with no difference between the two groups ($p = 0.204$) (Fig. 3, Table 3).

Mean BCVA change and mean CSF thickness change throughout the 3-month follow-up is shown in Figs 2 and 3 and in Tables 2 and 3.

Naïve patients

A total of 31 and 25 eyes were naïve in the ‘precataract DEX group’ and ‘concomitant treatments’ group, respectively. Naïve patients showed better postoperative mean BCVA compared to non-naïve patients in both groups (Fig. 4; Table 3). In the ‘precataract DEX group’, 3-month mean CSF thickness in naïve eyes was lower than the baseline value ($328 \pm 32 \mu\text{m}$ versus $373 \pm 41 \mu\text{m}$, $p < 0.001$), whereas in non-naïve eyes it was greater than the baseline value ($383 \pm 50 \mu\text{m}$ versus 366 ± 38 , $p = 0.017$) (Fig. 5, Table 2).

Adverse events

No serious systemic adverse events were reported during the follow-up. Two patients (one per each group) experienced a mild vitreous haemorrhage following the DEX implant, which resolved spontaneously in both cases within 1 month. Postoperative mean

IOP was comparable between the two groups and with baseline values as well (Fig. 6). Eight patients in the ‘precataract DEX group’ and 10 in the ‘concomitant treatments’ group showed following intravitreal DEX an IOP value $> 21 \text{ mmHg}$, which was responsive to topical IOP-lowering therapy.

Discussion

This study demonstrated that intravitreal DEX administered both 1 month before and at the same time of cataract surgery, prevents the worsening of DME after the surgery with comparable visual outcome between the two different timings. However, a better anatomical outcome at the 3-month follow-up was found in patients receiving DEX at the time of cataract surgery.

A worsening of DME after cataract surgery has been reported in more than 20% of cases with history of DME

Table 2. Mean change in central subfield (CSF) thickness throughout the 3-month follow-up in the two groups.

OCT measurements, μm	n	Baseline	1 month	2 months	3 months	ANOVA	Tukey HSD versus baseline
Previous DEX implant	136	368 ± 38	316 ± 34^a	304 ± 44^a	371 ± 52	<0.001	$<0.001^a$
Concomitant DEX implant	85	480 ± 101	354 ± 65^a	323 ± 59^a	325 ± 57^a	<0.001	$<0.001^a$
p-value for the difference		<0.001	<0.001	0.014	<0.001		
Previous DEX implant: Naïve	31	373 ± 41	341 ± 38^a	309 ± 45^a	328 ± 32^a	<0.001	$<0.001^a$
Concomitant DEX implant: Naïve	25	470 ± 96	349 ± 55^a	315 ± 46^a	308 ± 50^a	<0.001	$<0.001^a$
P-value for the difference		<0.001	0.491	0.954	0.128		
Previous DEX implant: Non-naïve	105	366 ± 38	309 ± 30^a	303 ± 44^a	383 ± 50^b	<0.001	$<0.001^a, 0.017^b$
Concomitant DEX implant: Non-naïve	60	484 ± 104	356 ± 69^a	326 ± 64^a	332 ± 58^a	<0.001	$<0.001^a$
p-Value for the difference		<0.001	<0.001	0.021	<0.001		

DEX = dexamethasone implant, HSD = honestly significant difference, OCT = optical coherence tomography. Bold values is the p value for the difference between previous DEX implant group and concomitant DEX implant group. ^a represents p-value for the HSD compared to the baseline value a = <0.001 . ^b represents p-value for the HSD compared to the baseline value b = 0.017.

Table 3. Mean change in best-corrected visual acuity (BCVA) throughout the 3-month follow-up in the two groups.

logMAR \pm SD	No.	Baseline	1 month	2 months	3 months	ANOVA	Tukey HSD versus baseline
Previous DEX implant	136	0.70 ± 0.27	0.36 ± 0.22^a	0.35 ± 0.20^a	0.44 ± 0.23^a	<0.001	$<0.001^a$
Concomitant DEX implant	85	0.82 ± 0.26	0.47 ± 0.25^a	0.42 ± 0.25^a	0.40 ± 0.25^a	<0.001	$<0.001^a$
p-Value for the difference		<0.001	<0.001	0.027	0.204		
Previous DEX implant: Naïve	31	0.58 ± 0.27	0.22 ± 0.19^a	0.20 ± 0.15^a	0.32 ± 0.16^a	<0.001	$<0.001^a$
Concomitant DEX implant: Naïve	25	0.80 ± 0.35	0.36 ± 0.22^a	0.31 ± 0.25^a	0.31 ± 0.24^a	<0.001	$<0.001^a$
p-Value for the difference		0.001	<0.001	0.001	0.560		
Previous DEX implant: Non-naïve	105	0.73 ± 0.26	0.40 ± 0.21^a	0.39 ± 0.19^a	0.48 ± 0.24^a	<0.001	$<0.001^a$
Previous DEX implant: Non-naïve	60	0.83 ± 0.22	0.51 ± 0.25^a	0.46 ± 0.23^a	0.43 ± 0.25^a	<0.001	$<0.001^a$
P-value for the difference		0.047	0.010	0.068	0.469		

DEX = dexamethasone implant, HSD = honestly significant difference. Bold values is the p value for the difference between previous DEX implant group and concomitant DEX implant group. ^a refers to the p-value for the HSD compared to the baseline value a = <0.001 .

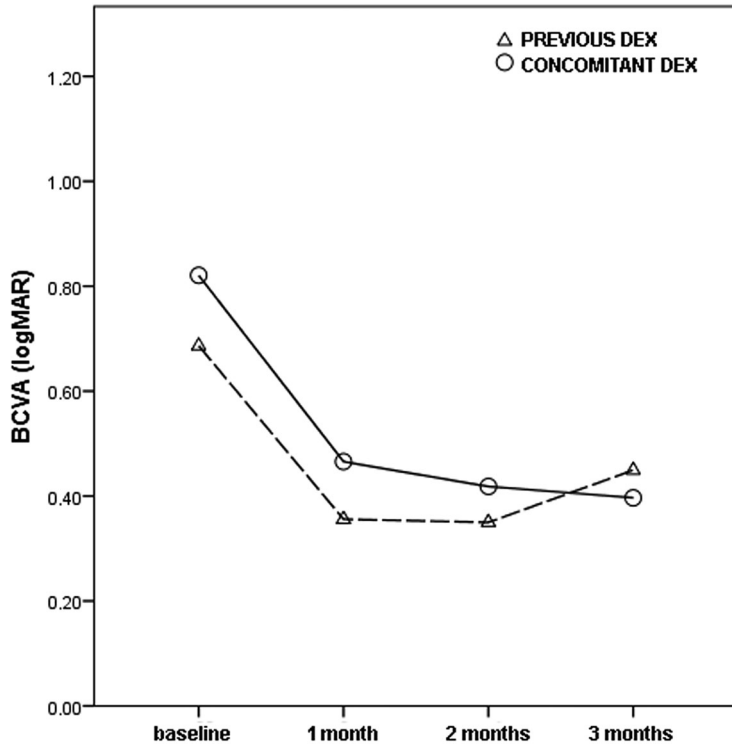


Fig. 3. Change in best-corrected visual acuity (BCVA) over time in the two groups.

treatment (DRCR Network Authors/ Writing Committee et al. 2013). A poor visual outcome has also been reported, with a postcataract surgery visual acuity < 6/12 in 33% of cases (DRCR Network Authors/Writing Committee et al. 2013). The pro-inflammatory condition triggered by the surgery promotes the release of pro-angiogenic and pro-inflammatory cytokines which

cause further damage to an already injured blood-retinal barrier, leading to increasing vascular permeability, and loss of endothelial cells and pericytes (Boscia et al. 2017; Denniston et al. 2017; Calvo et al. 2018). In these patients, a clear distinction between a progression of DME and the Irvine-Gass syndrome is challenging (Calvo et al. 2018), since the two diseases share

similar pathogenesis, and the risk of Irvin-Gass syndrome is fourfold higher in diabetic compared with non-diabetic patients (Chu et al. 2016).

In terms of timing, it is believed that the pro-inflammatory condition following cataract surgery has a short course, and macular oedema may occur even 1 month afterwards (Calvo et al. 2018). In fact, the onset of pseudophakic macular oedema is more likely between 4 and 12 weeks postoperatively, peaking at 4–6 weeks (Zur & Loewenstein 2017). A recent real-world study found the highest risk of a first episode of treatment-requiring DME between 3 and 6 months from cataract surgery (Denniston et al. 2017).

For these reasons, some authors have described the administration of intravitreal DEX implant at the same time of cataract surgery in patients affected by DME, showing both anatomical and visual improvements (Agarwal et al. 2013; Furino et al. 2017; Panozzo et al. 2017) or the avoidance of macular thickness increase (Calvo et al. 2018).

In contrast, a different option for the management of cataract surgery in patients with DME could be the administration of DEX implant 1 month before cataract surgery, as reported by the RELDEX study (Malclès et al. 2017). No visual impairment was recorded in the period following cataract surgery. The authors speculated that DEX implant reduced the level of DME on the cataract surgery day and, since the

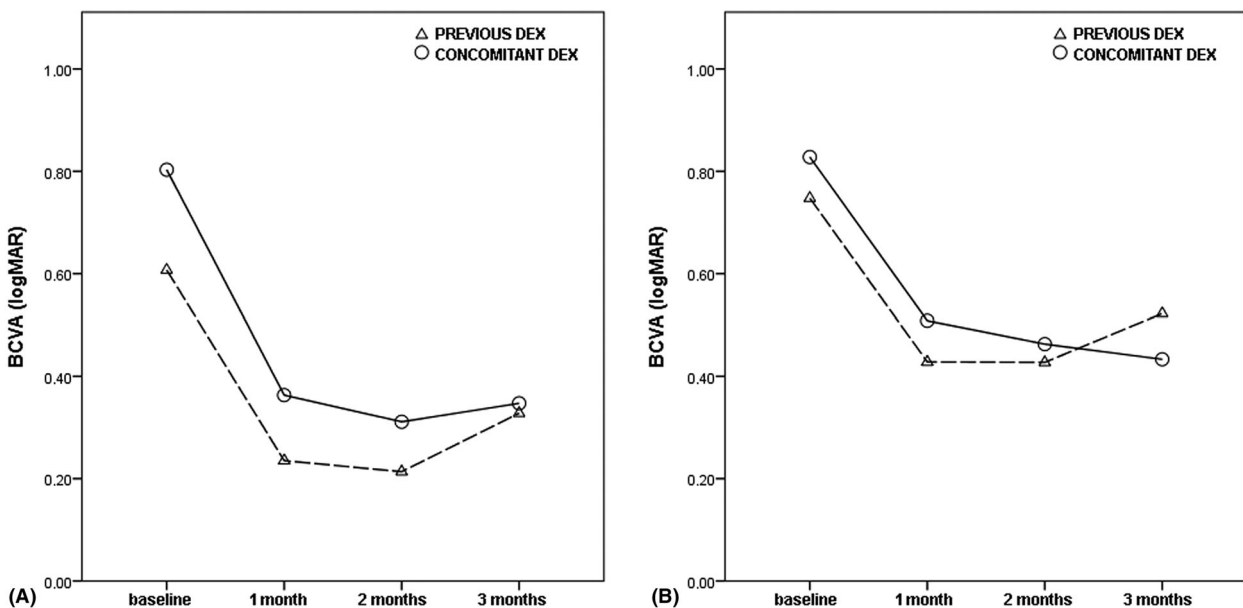


Fig. 4. Change in best-corrected visual acuity in the two groups: (A) naive patients and (B) non-naive patients.

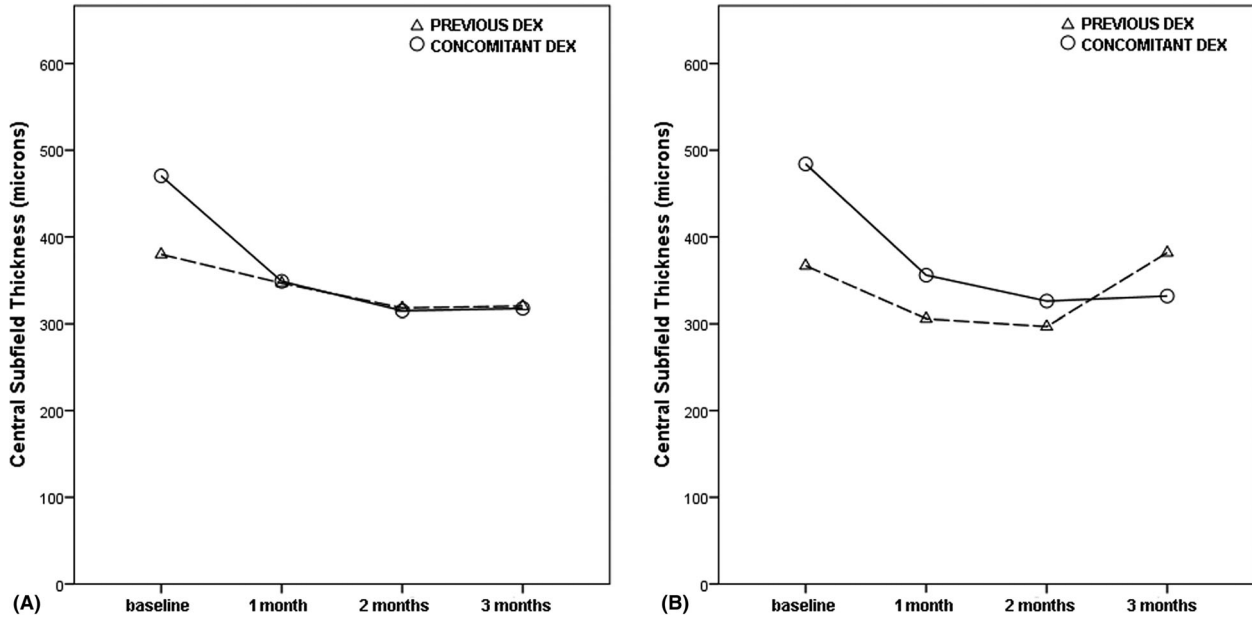


Fig. 5. Change in central subfield thickness in the two groups: (A) naïve patients and (B) non-naïve patients.

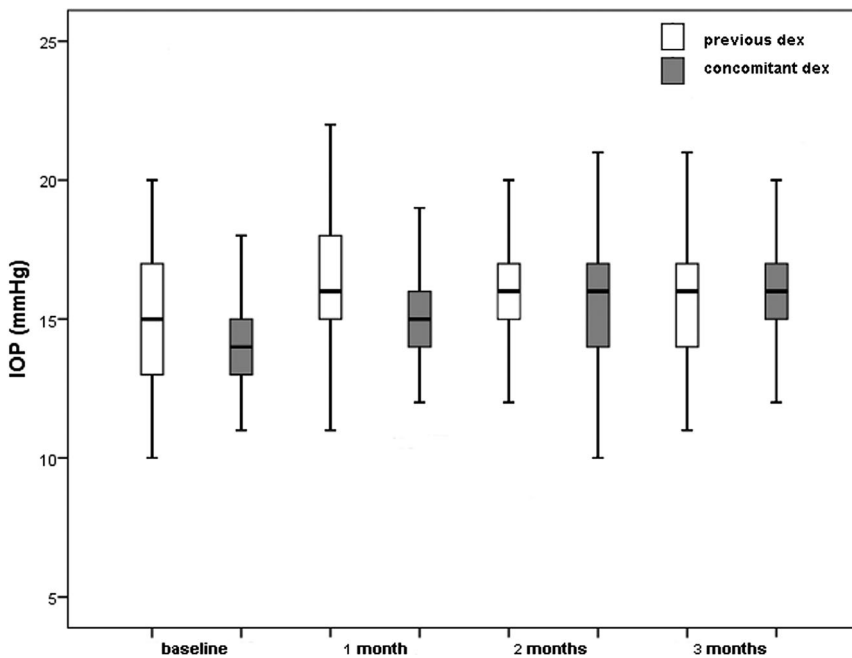


Fig. 6. Change in postoperative intraocular pressure (IOP) over time in the two groups.

DEX implant is supposed to maintain this effect for 2–3 months after the cataract surgery, the aggravation of the macular oedema could be prevented.

When comparing different timing of DEX administration in relation to cataract surgery, the visual outcome seems less sensitive than the anatomical outcome because a visual improvement is highly likely after cataract surgery. Our findings showed a visual improvement throughout the follow-up in both groups.

Looking at the 3-month anatomical result of this study, DEX combined with cataract surgery proved more effective than DEX 1 month before. In particular, patients receiving DEX 1 month before cataract surgery showed a decrease in CSF 1 month and 2 months after the cataract surgery, with better results compared to the ‘concomitant treatment’ group, but failed to maintain this improvement at 3 months. A possible explanation could be the loss of effectiveness of the DEX implant at 4 months

from its administration, which has been previously reported (Bonfiglio et al. 2017). On the other hand, DEX administered at the time of cataract surgery maintained its effectiveness in terms of the anatomical and visual outcome at a 3-month follow-up. It could be assumed that this concomitant treatment represents a suitable timing for having a match between the pro-inflammatory peak secondary to the surgery and the anti-inflammatory effect of DEX.

Naïve patients receiving DEX 1 month before the surgery also showed a reduction of CSF thickness at 3 months from cataract surgery. This might be explained by the longer effect of the implant in naïve eyes (Escobar-Barranco et al. 2015; Chhablani et al. 2016; Matonti et al. 2016). In particular, Chhablani et al. 2016 found a longer mean treatment-free interval in naïve patients compared to the previously treated ones (10.5 months versus 6.2 months, respectively). Likewise, better functional outcomes have been shown in naïve patients (Escobar-Barranco et al. 2015). This better response in naïve eyes seems to be related to both the early initiation of the treatment and the absence of a structural damage secondary to a long-standing inflammatory process (Escobar-Barranco et al. 2015; Igllicki et al. 2019).

Another relevant reason for preferring the combined approach rather than giving DEX implant 1 month before cataract surgery is the management of

the posterior capsule rupture, which might be a risk for implant migration in the anterior chamber, with subsequent endothelial damage and corneal oedema (Khurana et al. 2014).

The following limitations of this study are noted. First, the retrospective design represents a relevant shortcoming. The allocation to the different groups was not random, and there might have been an element of selection bias that could have affected the results.

Second, a longer follow-up would have allowed better evaluation and comparison of the findings in the two groups. Additionally, the BCVA change could have been influenced mainly by cataract extraction. For such a reason, we considered the anatomical outcome more reliable for assessing the effectiveness of the two approaches and both the rate of improvement/worsening and the mean CSF thickness change were investigated with this purpose in mind.

The strength of the study is its multicentre design and the inclusion of a large number of patients. Furthermore, the methodology was based on strict inclusion/exclusion criteria in order to reduce the risk of bias.

In conclusion, intravitreal DEX administered both 1 month before and at the same time of cataract surgery proved effective in preventing the worsening of DME. Even if a better anatomical outcome was found in patients receiving the concomitant treatment, further prospective randomized studies are needed to assess which is the optimal timing for DEX administration.

References

- Agarwal A, Gupta V, Ram J & Gupta A (2013): Dexamethasone intravitreal implant during phacoemulsification. *Ophthalmology* **120**: e211–e215.
- Bonfiglio V, Reibaldi M, Fallico M et al. (2017): Widening use of dexamethasone implant for the treatment of macular edema. *Drug Des Devel Ther* **11**: 2359–2372.
- Boscia F, Giampoli E, D'Amico Ricci G & Pinna A (2017): Management of macular oedema in diabetic patients undergoing cataract surgery. *Curr Opin Ophthalmol* **28**: 23–28.
- Bressler SB, Qin H, Beck RW, Chalam KV, Kim JE, Melia M & Wells JA 3rd; Diabetic Retinopathy Clinical Research Network. (2012). Factors associated with changes in visual acuity and central subfield thickness at 1 year after treatment for diabetic macular edema with ranibizumab. *Arch Ophthalmol* **130**: 1153–1161.
- Calvo P, Ferreras A, Al Adel F, Dangboon W & Brent MH (2018): Effect of an intravitreal dexamethasone implant on diabetic macular edema after cataract surgery. *Retina* **38**: 490–496.
- Chhablani J, Bansal P, Veritti D et al. (2016): Dexamethasone implant in diabetic macular edema in real-life situations. *Eye (Lond)* **30**: 426–430.
- Chu CJ, Johnston RL, Buscombe C, Sallam AB, Mohamed Q & Yang YC; United Kingdom Pseudophakic Macular Edema Study Group (2016): Risk factors and incidence of macular edema after cataract surgery: a database study of 81984 eyes. *Ophthalmology* **123**: 316–323.
- Denniston AK, Chakravarthy U, Zhu H et al. (2017): The UK Diabetic Retinopathy Electronic Medical Record (UK DR EMR) Users Group, Report 2: Real-world data for the impact of cataract surgery on diabetic macular oedema. *Br J Ophthalmol* **101**: 1673–1678.
- Diabetic Retinopathy Clinical Research Network Authors/Writing Committee, Baker CW, Almkhatar T, Bressler, NM et al. (2013). Macular edema after cataract surgery in eyes without preoperative central-involved diabetic macular edema. *JAMA Ophthalmol* **131**: 870–879.
- Escobar-Barranco JJ, Pina-Marin B & Fernandez-Bonet M (2015): Dexamethasone implants in patients with naive or refractory diffuse diabetic macular edema. *Ophthalmologica* **233**: 176–185.
- Furino C, Boscia F, Niro A, et al. (2017): Combined phacoemulsification and intravitreal dexamethasone implant (Ozurdex(R)) in diabetic patients with coexisting cataract and diabetic macular edema. *J Ophthalmol* **2017**: 4896036.
- Iglicki M, Busch C, Zur D et al. (2019). Dexamethasone implant for diabetic macular edema in naive compared with refractory eyes: The International Retina Group Real-Life 24-Month Multicenter Study. The IRGREL-DEX Study. *Retina* **39**(1): 44–51.
- Khurana RN, Appa SN, McCannel CA, Elman MJ, Wittenberg SE, Parks DJ, Ahmad S & Yeh S (2014): Dexamethasone implant anterior chamber migration: risk factors, complications, and management strategies. *Ophthalmology* **121**: 67–71.
- Malclès A, Dot C, Voirin N, Agard É, Vié AL, Bellocq D, Denis P & Kodjikian L (2017): Real-life study in diabetic macular edema treated with dexamethasone implant: The Reldex Study. *Retina* **37**: 753–760.
- Matonti F, Guigou S, Pommier S et al. (2016): Dexamethasone implants in patients with naive diabetic macular edema. *Ophthalmologica* **235**: 244.
- Obrosova IG, Chung SS & Kador PF (2010): Diabetic cataracts: Mechanisms and management. *Diabetes Metab Res Rev* **26**: 172–180.
- Panozzo GA, Gusson E, Panozzo G & Dalla Mura G (2017): Dexamethasone intravitreal implant at the time of cataract surgery in eyes with diabetic macular edema. *Eur J Ophthalmol* **27**: 433–437.
- Romero-Aroca P, Fernandez-Ballart J, Almena-Garcia M, Méndez-Marín I, Salvat-Serra M & Buil-Calvo JA (2006): Non-proliferative diabetic retinopathy and macular edema progression after phacoemulsification: prospective study. *J Cataract Refract Surg* **32**: 1438–1444.
- Zur D & Loewenstein A (2017): Postsurgical cystoid macular edema. *Dev Ophthalmol* **58**: 178–190.

Received on February 4th, 2020.

Accepted on May 26th, 2020.

Correspondence:

Michele Reibaldi
Department of Ophthalmology
University of Catania
Via Santa Sofia 78
Catania, 95124
Italy
Tel: +39 09 537 812 13
Fax: +39 09 537 812 88
Email: mreibaldi@libero.it

Editorial assistance in preparing the manuscript for submission was provided to the authors by Ray Hill, an independent medical writer, and funded by Allergan plc, Dublin, Ireland, at the request of the investigator. All authors met the ICMJE authorship criteria.

All authors made substantial contributions to conception, design, analysis and interpretation of data and contributed to writing the article and approved the current version.

Neither honoraria nor payments were made for authorship.

Francesco Bandello consultant for: Alcon (Fort Worth, TX, USA), Alimera Sciences (Alpharetta, GA, USA), Allergan Inc (Irvine, CA, USA), Farmila-Thea (Clermont-Ferrand, France), Bayer Schering-Pharma (Berlin, Germany), Bausch and Lomb (Rochester, NY, USA), Genentech (San Francisco, CA, USA), Hoffmann-La-Roche (Basel, Switzerland), Novagali Pharma (Évry, France), Novartis (Basel, Switzerland), Sanofi-Aventis (Paris, France), Thrombogenics (Heverlee, Belgium), Zeiss (Dublin, OH, USA). All other authors have no disclosures to declare.

Disclaimer: Allergan had no role in the design or conduction of this research.

Patient consent: Obtained.

Ethics approval: The study was approved by the Institutional review board at the coordinating centre (University of Catania) and at each participating site. The study protocol and data collection adhered to the tenets of the Declaration of Helsinki.

Data sharing statement: Unpublished data are available on contacting the corresponding author.