

## SHORT REPORT

# Endovascular Stent Grafts as a Safe Secondary Option for Paraanastomotic Abdominal Aortic Aneurysm

L. Di Tommaso,<sup>1\*</sup> M. Monaco,<sup>1</sup> F. Piscione,<sup>2</sup> G. Sarno<sup>2</sup> and G. Iannelli<sup>1</sup>

<sup>1</sup>Department of Cardiac Surgery, and <sup>2</sup>Department of Cardiology University "Federico II" of Naples, Italy

**Objective.** To describe our experience of endovascular repair of paraanastomotic aortic aneurysm.

**Methods and results.** From March 2001 to December 2004 we identified 6 patients with a paraanastomotic aortic aneurysms following previous open repair of abdominal aortic aneurysm. All patients were treated with endovascular surgery under epidural anaesthesia. There were no major complications, surgical conversions or deaths. Four patients received a bifurcated aortic stent-graft, and two an aorto-uniliac stent-graft followed by a femoro-femoral bypass. At follow-up (mean  $26.1 \pm 10.2$  months) there were no deaths, endoleaks or graft migrations observed.

**Conclusion.** Endovascular surgery, avoiding general anaesthesia and re-laparotomy, is the ideal technique for treatment of this complication resulting from failed primary conventional AAA repair.

**Keywords:** Endovascular surgery; Paraanastomotic aneurysm; Abdominal aorta.

### Introduction

Failure of standard repair of abdominal aortic aneurysm (AAA) occurs most commonly as a result of paraanastomotic aneurysm formation.<sup>1</sup> The occurrence rate is 1–3% during the initial months and years following the operation, increasing to 13.3% in series with longer follow-up.<sup>2</sup>

Causative factors include: anastomosis far below the renal arteries with an aneurysm formation in the infrarenal aortic wall; extensive thromboendarterectomy in the area of the anastomosis; infection leading to rupture of the anastomotic suture line. The mortality rate of patients treated conservatively is very high (more than 60%).<sup>3</sup> Open surgical repair is associated with a mortality of 8 to 17%<sup>4</sup> in elective cases and more than 66% in cases of rupture.<sup>2</sup> After our encouraging results with endovascular aortic repair (EVAR) for abdominal aortic aneurysm we extended this treatment to high risk patients with paraanastomotic aneurysm.

### Report

From January 2000 to December 2004, 161 consecutive patients with abdominal aortic aneurysm were admitted to our department. 54 patients were treated by conventional surgery and 107 underwent EVAR. Six of these patients had a history of previous conventional aortic surgery and had developed a new paraanastomotic aneurysm of the abdominal aorta (PAAA): four at the proximal site and two at the distal site of an infrarenal aorto-aortic graft. All these patients were treated by endovascular surgery. Symptoms (abdominal and/or back pain) were present in three patients (50%). Interval from the primary procedure ranged from 76 to 133 months (mean  $99.6 \pm 19.5$  months). Patient characteristics are showed in Table 1. None of the patients displayed any sign of infection. Preoperative tests included spiral CT scan, aortography and coronary angiography, to assess suitability for EVAR and for risk stratification. The diameter of the pseudoaneurysm ranged from 45 to 67 mm (mean  $55.2 \pm 8.2$  mm).

The endovascular procedure was performed in the catheterization laboratory under epidural anaesthesia. In all cases, access to both femoral or external iliac arteries was achieved by surgical dissection. For all patients the stent grafts were proximally and distally

\*Corresponding author. L. Di Tommaso, MD, Via V. Gemito, 33, 81100, Caserta – Italy.  
E-mail address: [lditommaso@tin.it](mailto:lditommaso@tin.it)

**Table 1. Patient clinical and operative characteristics**

	Sex	Age (yrs)	First procedure	Site	Stent graft	Interval (mo)	ASA class
1	m	73	Straight graft	Proximal	Bifurcated	94	IV
2	m	71	Straight graft	Proximal	Bifurcated	102	III
3	m	78	Straight graft	Distal	Aortouniliac	76	IV
4	m	82	Straight graft	Proximal	Aortouniliac	106	III
5	m	74	Straight graft	Distal	Bifurcated	87	III
6	m	63	Straight graft	Proximal	Bifurcated	133	III

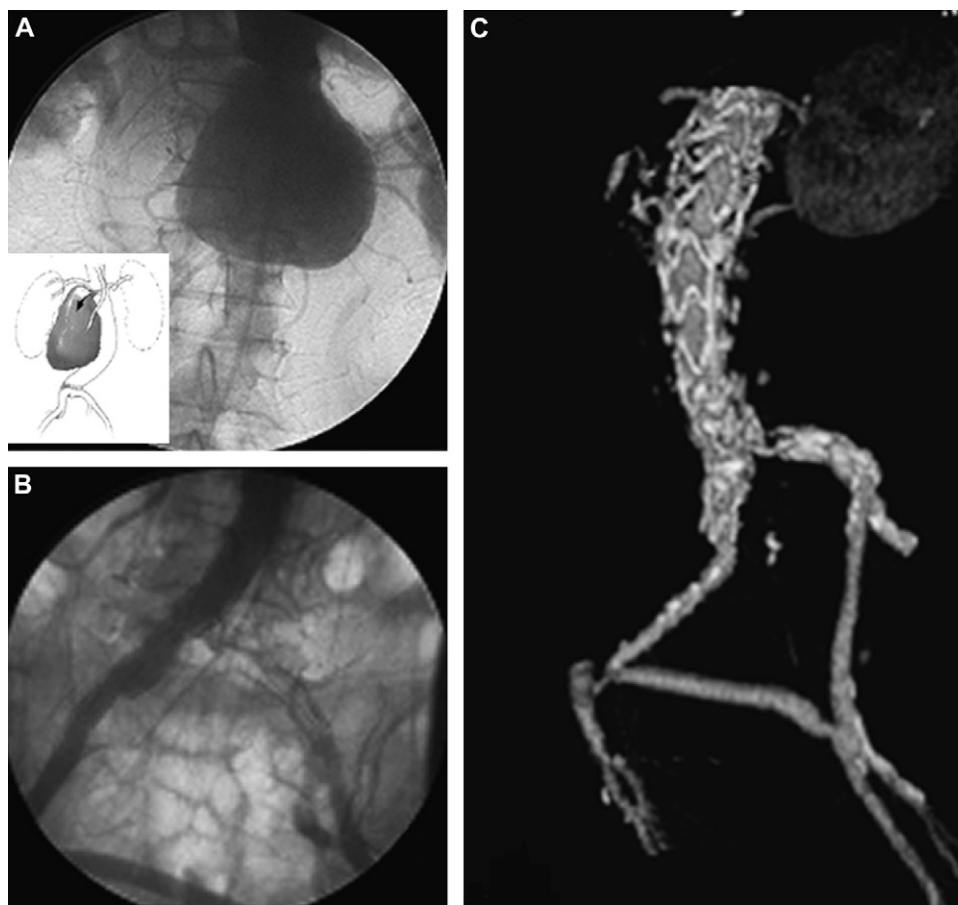
anchored at the aorta and iliac artery respectively. Following implantation of the aortouniliac stent-graft a femoro-femoral extra-anatomic crossover bypass with woven Dacron graft was performed to maintain contralateral pelvic and limb perfusion. For all patients the endovascular device was a self expanding endoprosthesis consisting of circumferential nitinol stent springs covered with a Dacron graft (Talent – Medtronic AVE, Santa Rosa, CA).

There were no major complications, surgical conversion or deaths.

Four patients received a bifurcated aortic stent-graft, while two had an aorto-uniliac stent-graft followed by a femoro-femoral crossover prosthetic bypass (Fig. 1).

All patients started mobilizing on the first postoperative day. One patient developed a superficial wound infection. To assess the presence of endoleaks, all patients underwent a spiral CT scan at 15 days and 3, 6 and 12 months after EVAR.

Follow-up for all patients ranged from 11 to 39 months (mean  $26.1 \pm 10.2$  months). During the entire



**Fig. 1.** A: Preoperative angiographic picture with schematic design of paraaortic aneurysm. B: Postoperative angiographic pictures with aortouniliac stent graft and a femoro-femoral crossover bypass; and C: VR-computed tomographic scan.

follow-up period there were no deaths, no patient required surgical conversion and no endoleaks or stent-graft dislocation or kinking were observed.

### Discussion

Conventional surgical repair of paraanastomotic aortic aneurysms requires relaparotomy, dissection of the abdominal aorta in the scarred retroperitoneum and suprarenal aortic clamping.<sup>2</sup> EVAR has a number of potential advantages. The relatively brief amount of time required for the procedure and the fact that there is no need for general anesthesia, re-laparotomy, dissection of the abdominal aorta and suprarenal aortic clamping makes endovascular surgery the ideal technique for treatment of complications resulting from failed primary conventional AAA repair procedures and has rapidly evolved as a valuable alternative to conventional surgery.<sup>1,5</sup>

The procedure is also indicated for patients who are likely to have more comorbidity or are otherwise considered unsuitable for conventional surgery. The only exclusion criteria is the presence of characteristics suggestive of infection of the previous prosthesis, such as clinical history, symptoms, leukocytosis and other inflammatory parameters. Our results for treatment of the paraanastomotic aortic aneurysm are

similar to the results achieved with primary abdominal aortic aneurysm.

We support elective repair of paraanastomotic aneurysm irrespective of the aortic diameter, to avoid the likely possibility of rupture. Under difficult morphologic conditions, the implantation of an aorto-uniliac stent-graft with a femoro-femoral crossover bypass provides a good therapeutic option.

### References

- 1 FARES PL, WON J, MORRISSEY NJ, BRIGGS VL, CADOT H, CARROCCIO A *et al.* Endovascular treatment of failed prior abdominal aortic aneurysm repair. *Ann Vasc Surg* 2003;**17**(1):43–48.
- 2 VAN HERWAARDEN JA, WAASDORP EJ, BENDERMACHER BL, VAN DEN BERG JC, TEIJINK JA, MOLL FL. Endovascular repair of paraanastomotic aneurysms after previous open aortic prosthetic reconstruction. *Ann Vasc Surg* 2004;**18**(3):280–286.
- 3 MULDER EJ, VAN BOCKEL JH, MAAS J, VAN DEN AKKER PJ, HERMANS J. Morbidity and mortality of reconstructive surgery of noninfected false aneurysms detected long after aortic prosthetic reconstruction. *Arch Surg* 1998 Jan;**133**(1):45–49.
- 4 COSELLI JS, LEMAIRE SA, BUKET S, BERZIN E. Subsequent proximal aortic operations in 123 patients with previous infrarenal abdominal aortic aneurysm surgery. *J Vasc Surg* 1995;**22**(1):59–67.
- 5 PEARCE BJ, BALDWIN Z, BASSIOUNY H, GEWERTZ BL, MCKINSEY JF. Endovascular solutions to complications of open aortic repair. *Vasc Endovasc Surg* 2005 May–Jun;**39**(3):221–228.

Accepted 8 May 2006

Available online 22 June 2006