

Systemic treatment of malignant gastrointestinal neuroectodermal tumour after childhood neuroblastoma: chemotherapy in malignant gastrointestinal neuroectodermal tumour

Margaret Ottaviano^{a,b}, Chiara Maddalena^a, Maria D'Armiento^c, Rossella Lauria^a, Vincenzo D'Alessandro^d, Marianna Tortora^b, Elide Matano^a, Vincenzo Di Lauro^a, Brigitta Mucci^a, Gabriella Ferraro^e, Sabino De Placido^{a,b}, Mario Giuliano^{a,b} and Giovannella Palmieri^b

Malignant gastrointestinal neuroectodermal tumour is an extremely rare neoplasm that arises in the wall of the small bowel, stomach or large bowel in young-aged and middle-aged adults. Histologically, it is generally characterized by monomorphic cells with clear cytoplasm, S-100 protein expression, and *EWSR1* gene translocation. To the best of our knowledge, we describe for the first time, the case of a young woman with a diagnosis of metastatic gastrointestinal neuroectodermal tumour arising from ileum, who had a childhood adrenal neuroblastoma with liver, bone and lymph nodes metastasis, treated with four cycles of chemotherapy with the schedule CADO-CVP (CADO: cyclophosphamide 300 mg/m²/day on days 1–5, vincristine 1.5 mg/m²/day on days 1 and 5, and doxorubicin 60 mg/m²/day on day 5; CVP: cisplatin 40 mg/m²/day on days 1–5 and etoposide 100 mg/m²/day on days 1–5) followed by right adrenal, kidney, lymph nodes and liver lesion resection, conditioning chemotherapy (melphalan-carmustine-teniposide), stem cells autologous transplantation and consecutively radiotherapy on the spine (T9 to L3) for a total of 30 Gy. For the second diagnosis of gastrointestinal neuroectodermal tumour with liver metastasis, she underwent ileal tumour resection and

platinum-anthracycline based chemotherapy with initial shrinkage of liver metastasis. Unfortunately, despite the initial response and the following delivered therapies, she died for rapid progressive disease. Taking into account the late effects of past therapeutic modalities, a long-term surveillance of young child treated for neuroblastoma, is required to appreciate their overall risks of second malignancies.

Anti-Cancer Drugs 30:959–963 Copyright © 2019 Wolters Kluwer Health, Inc. All rights reserved.

Anti-Cancer Drugs 2019, 30:959–963

Keywords: anthracyclines, cisplatin, clear cell sarcoma-like of the gastrointestinal tract, gene translocation, malignant gastrointestinal neuroectodermal tumour, neuroblastoma, radiotherapy

^aOncology Unit, Department of Clinical Medicine and Surgery, University Federico II of Naples, ^bOncology Unit, CRTR Rare Tumors Reference Center, AOU Federico II of Naples, ^cDepartment of Biomorphological and Functional Sciences, Section of Pathology, University of Naples 'Federico II', ^dOperative Unit of Kidney Transplantation and retroperitoneal pathologies, AOU Federico II of Naples, and ^eUFA Operative Unit, AOU Federico II of Naples, Naples, Italy

Correspondence to Margaret Ottaviano, Oncology Unit, Department of Clinical Medicine and Surgery, Università degli Studi di Napoli Federico II, Via Sergio Pansini 5, 80131 Naples, Italy
Tel: +39 3333759668, fax: +39 0817462114;
e-mail: margaretottaviano@gmail.com

Received 18 March 2019 Revised form accepted 25 April 2019

Introduction

Malignant gastrointestinal neuroectodermal tumour (GNET) is an extremely rare neoplasm that arises in the wall of the small bowel, stomach or large bowel in young-aged and middle-aged adults. Histologically, it is generally characterized by monomorphic cells with clear cytoplasm, S-100 protein expression, and *EWSR1* gene translocation, sharing these features with the more known entity, the clear cell sarcoma (CCS)-like of the gastrointestinal tract (CCSLGT), from which, however, differs for the evidence of neuroectodermal differentiation. The exact nosological relationship between these rare tumours is still matter of debate. Differently, from the CCS of soft tissue and of tendons and aponeuroses, which usually shows a less progressive and aggressive course and

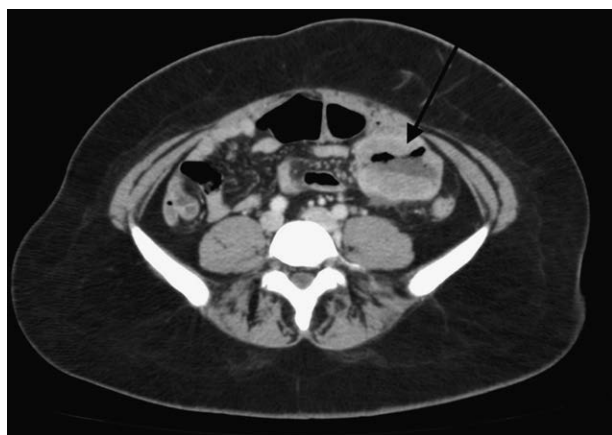presents the immuno-histochemical or ultrastructural melanocytic differentiation, GNET and CCSLGT clearly share a poor prognosis [1]. Because of the aggressive biological behaviour, GNET is diagnosed more often at metastatic stage, and, since no medical standard therapy has been approved as patients rapidly progress, the surgery remains the only available treatment. To the best of our knowledge, we describe, for the first time, the unique case of a 28-year-old female, with a previous diagnosis of childhood neuroblastoma, who achieved partial response of metastatic GNET with systemic chemotherapy.

Case report

In December 2014, after the onset of persistent anaemia, night sweats and hyperpyrexia, a 28-year-old white

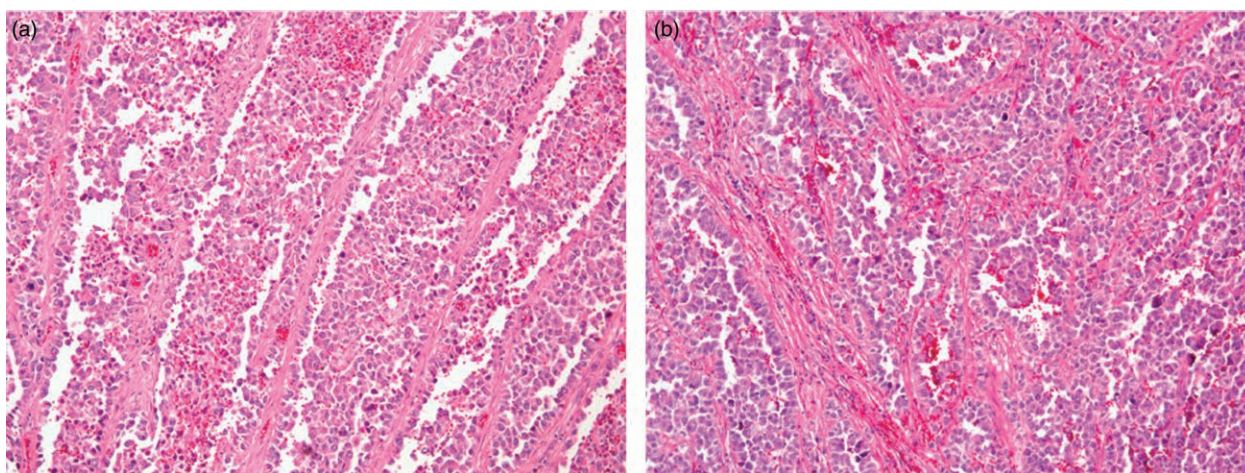
female underwent clinical and instrumental examinations that showed a small bowel mass and several suspicious liver lesions (Fig. 1). In March 2015, ileal resection with end-to-end anastomosis was performed to avoid the risk of intestinal sub-occlusion and considering the persistence of anaemia, hepatic metastasectomy was not performed, due to the number and size of liver lesions. A deeply histological exam was carried on. Microscopically the mass was composed of large nests of markedly atypical cells, which occasionally were disposed in a pseudoalveolar and pseudopapillary pattern (Fig. 2a and b). Mitoses were frequent, as well as cell cannibalism (Fig. 2b). A broad immunohistochemical (IHC) panel was performed: neoplastic cells were Cytokeratin, LCA,

Fig. 1



Contrast-enhanced abdomen CT scan: evidence of ileal mass. CT, computed tomography.

Fig. 2

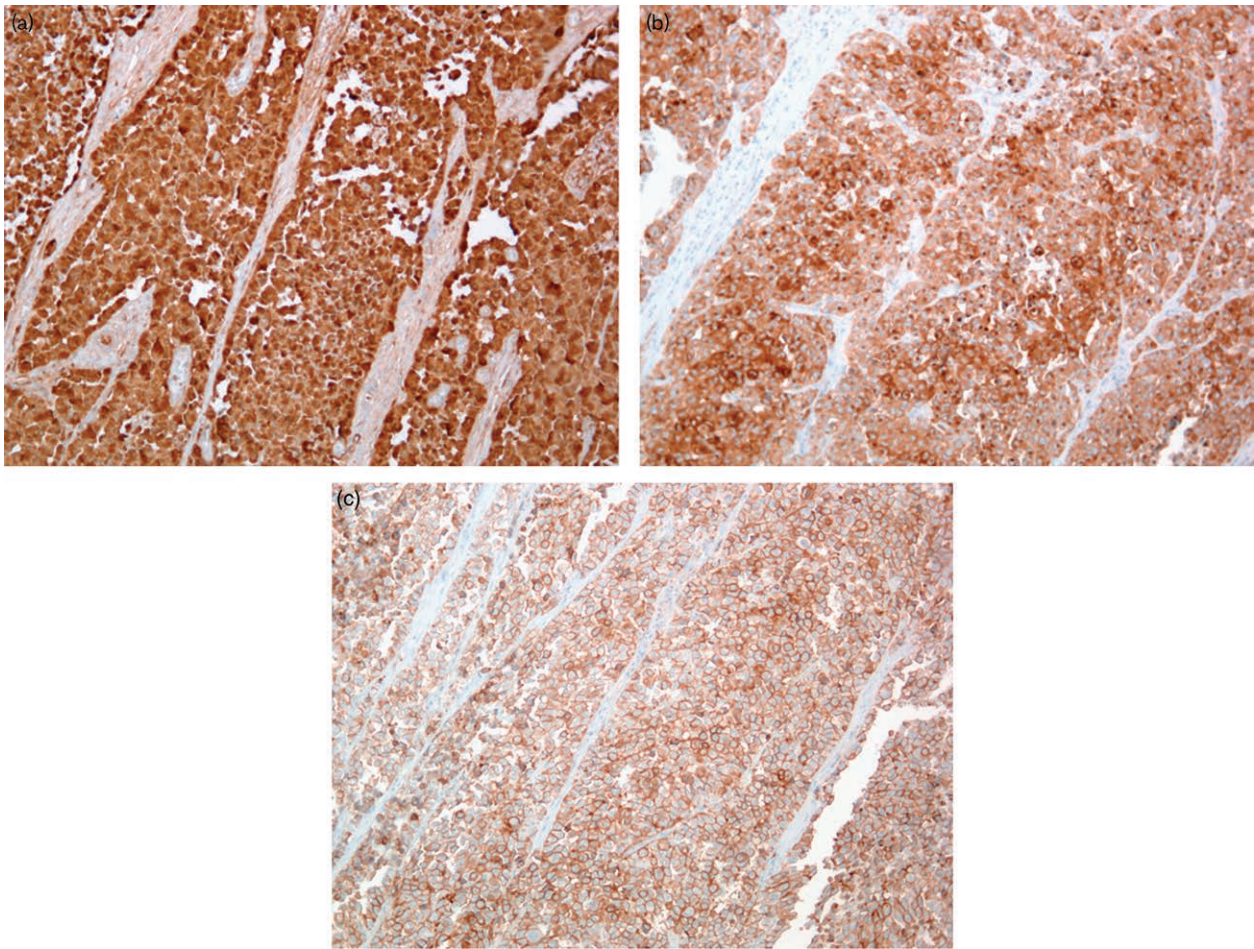


(a) Haematoxylin-eosin stain (100 \times), pseudopapillary pattern. (b) Haematoxylin-eosin stain (100 \times), pseudoalveolar pattern and large solid nests. There are distinctive cellular atypia and cell cannibalism.

NSE, HMB45, Melan-A, Chromogranine, Bcl2, CD34, CD99, EMA, CD117, Actin, Desmin, CD68 negative, but showed positivity for protein S-100 (Fig. 3a), CD56 (Fig. 3b), synaptophysin (Fig. 3c), Vimentin. Neither melanotic pigment was seen, nor histiocytic giant cells. All lymph nodes isolated from the perivisceral fat were metastatic. Fluorescent In Situ Hybridization analysis revealed EWSR1-CREB1 fusion, with disruptions of both EWSR1 (22q12) and CREB1 (2q33) demonstrated. The whole data were suggestive of malignant GNET.

The post-operative contrast-enhanced computed tomography (CT) scan confirmed unresectable multiple liver metastases, the symptoms of anaemia, night sweats and hyperpyrexia, were still present, the decision of starting systemic chemotherapy was made. The patient received three cycles of cisplatin 30 mg/m²; doxorubicin 20 mg/m² on days 1–3, with granulocyte-colony stimulating factor administration. Restaging scans showed a reduction in number and size of the known liver lesions (Fig. 4a and b). No further chemotherapy in according to that schedule was delivered, taking into account the cumulative dose of cytotoxic drugs previously administered for the diagnosis of childhood neuroblastoma. The patient, in fact, reported a history of adrenal neuroblastoma with liver, bone and lymph nodes metastasis at the age of 2 years old. A complete remission was achieved after four cycles of chemotherapy with the schedule CADO-CVP (CADO: cyclophosphamide 300 mg/m²/d on days 1–5, vincristine 1.5 mg/m²/day on days 1 and 5, and doxorubicin 60 mg/m²/day on day 5; CVP: cisplatin 40 mg/m²/day on days 1–5 and etoposide 100 mg/m²/day on days 1–5) followed by right adrenal, kidney, lymph nodes and liver lesions resection, conditioning chemotherapy (melphalan-carmustine-teniposide), stem cells autologous

Fig. 3



(a) Immunohistochemical stain (100×): S100 positive. (b) Immunohistochemical stain (100×): synaptophysin positive. (c) Immunohistochemical stain (100×): CD56 positive.

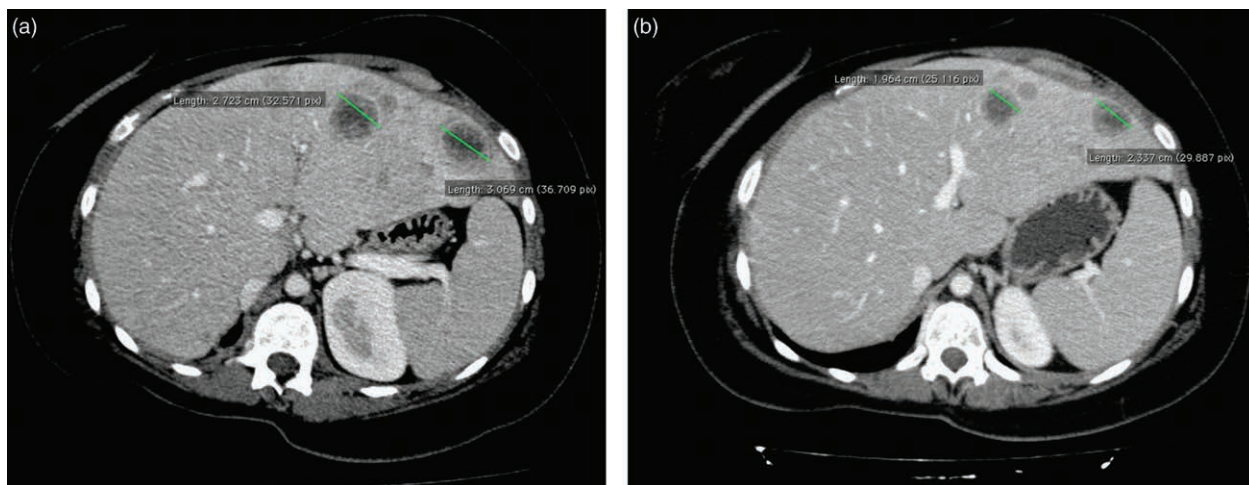
transplantation and consecutively radiotherapy on the spine (T9 to L3) for a total of 30 Gy. The patient remained free of disease, and at the age of 18 was discharged from periodical follow-up. In September 2015, after discontinuation of cisplatin-anthracycline based chemotherapy, a new CT scan showed local relapse and liver disease progression. Patient started treatment with sunitinib 37.5 mg daily, withdrawn after 1 month due to severe thrombocytopenia, anaemia and new onset of hyperpyrexia. Technetium-labelled erythrocyte scintigraphy showed uptake in the hepatic region. Selective arteriography and arterial embolization of right lumbar artery were performed, the following abdominal CT scan revealed blood dripping of a new hepatic lesion and further liver, peritoneal and nodal disease progression. The patient sadly died 4 weeks later.

Discussion

GNET is an extremely rare malignant neoplasm that occurs predominantly in young-aged and middle-aged

adults, with no sex preponderance noted [1]. As a new disease entity recently described, GNET develops mostly in the wall of the small bowel with a high rate of local recurrence, usually developing lymph nodes and liver metastases. Differently from any other primitive malignancies of the gastrointestinal tract, it shares morphological and molecular features with the CCSLGT like the absence of melanocytic differentiation, the chromosomal translocation involving *EWSR1-ATF1* (12;22) (q13;q12) and the symptomatic picture of abdominal pain, sub-occlusive syndrome, anorexia, weight loss, anaemia, lethargy, pyrexia and night sweats [1]. GNET might be considered a neuroectodermal tumour with aggressive behaviour and poor prognosis in contrast to the longer survival of patients with conventional CCS [2]. Firstly described by Enzinger in 1965, CCS is a deep soft tissue tumour associated with tendons and aponeuroses [3]. In 1993, the first visceral case of CCS in the duodenum was reported [4], and due to the lack evidence of melanocytic differentiation of the CCS occurring in the gastrointestinal

Fig. 4



(a) Contrast-enhanced abdomen CT scan: liver lesion before chemotherapy. (b) Contrast-enhanced abdomen CT scan: liver lesion after chemotherapy. CT, computed tomography.

tract, some authors proposed the definition of CCS-like tumour of the gastrointestinal tract CCSLTGT. First described by Zambrano *et al.* in 2003 [5], this new entity is composed, histologically, of relatively monomorphic ovoid or round cells with clear to eosinophilic cytoplasm, arranged in sheets or more ill-defined nests and sometimes it presents papillary or alveolar architectures [5,6], often with occasionally osteoclast-like giant cells in variable numbers [5,7–9]. CCSLTGT is focally positive for S100 protein, but does not express melanocytic markers such as HMB45 or Melan-A. In case of neuroendocrine markers expression, such as synaptophysin, chromogranin, NSE or CD56, it has been proposed that CCSLTGT might be re-designated as gastrointestinal neuroectodermal tumour (GNET) [2,10]. In fact, very recently, Stockman *et al.* [2] described 16 cases of gastrointestinal malignancies with morphologic and molecular features similar to those described in CCSLTGT with a primitive neural phenotype for the IHC profile: positivity for S100, SOX10, NSE, synaptophysin, CD56 and NB84 and negativity for HMB45, melan-A, tyrosinase. Since this rare entity do not have a normal cellular counterpart, and an origin from a gastrointestinal neuroectodermal precursor cell has been postulated, the designation of Malignant GNET has been approved [2]. We describe a unique case of GNET, arising in the ileum of a 28-year-old white female, who previously underwent high dose chemotherapy and radiation therapy for a childhood adrenal neuroblastoma. No standard medical treatment is available for GNET due to the poor prognosis and short survival. In this exposed case, taking into account the clinical stability, the young age of the patient and the available literature data, we decided to deliver

platinum-anthracycline- systemic chemotherapy. Jones *et al.* reported the Memorial Sloan-Kettering Cancer Center experience of 24 CCS patients treated with palliative first-line chemotherapy. With a median progression-free survival of 11 weeks [95% confidence interval (CI), 3–20 weeks] and a median overall survival of 39 weeks (95% CI, 34–45 weeks), the best tumour control was reached with anthracycline-based schedules [11], as well as in The Japanese Musculoskeletal Oncology Group report of 30 adult with metastatic CCS, the best outcome of partial response was achieved in seven of these patients treated with cisplatin-based chemotherapy [12]. In our case, after the combination of cisplatin and anthracycline-based chemotherapy a liver metastasis reduction was obtained, as well as a symptomatic relief was observed with disappearance of fever, night sweats and anaemia. Unfortunately, taking into account the cumulative dose of cytotoxic drugs previously administered for the diagnosis of childhood neuroblastoma, the decision of stopping chemotherapy was made, and at further progression sunitinib was prescribed. However, in contrast with some literature data [13] she reported a rapid disease progression.

Although reported cases of CCSLTGT have occurred as second malignancies following irradiation and chemotherapy for neuroblastoma (two cases) [14,15] and hepatoblastoma [16], to the best of our knowledge, no case of GNET after childhood neuroblastoma has been reported. We envision our case might help to shed on light on the etiology of this rare neoplasm, suggesting that previous treatments in childhood can be possible precipitating factors for GNET development later in life. Rubino *et al.* analysed data of 544 childhood survivors of neuroblastoma

and found 13-second malignant neoplasms (SMNs). The median time from diagnosis of neuroblastoma and occurrence of a SMN was 19.5 years (range 5–37 years). The most common SMNs included thyroid, breast and leukemia. Twelve of 13 patients with SMN received radiotherapy, while only three received chemotherapy. Five of those receiving radiotherapy developed a SMN within the radiation field, suggesting that irradiation may be an important risk factor [17]. Although no case of gastrointestinal sarcoma has been reported in this series, and the impact of chemo and radiotherapy combination in our patient is difficult to determine, the time and the anatomic region of SMN may highlight a link of cause-effect.

Conclusion

GNET is a rare malignant neoplasm with very poor prognosis. Conventional chemotherapy has little role in the treatment of this entity; further experience is awaited to define optimal treatment strategies for GNET and to evaluate the role of platinum and anthracycline-based therapy. The development of second malignancies many years after neuroblastoma emphasizes the necessity of long-term surveillance in childhood cancer survivors and highlights the potential impact of therapeutic decisions.

Acknowledgements

Conflicts of interest

There are no conflicts of interest.

References

- Green C, Spagnolo DV, Robbins PD, Fermoye S, Wong DD. Clear cell sarcoma of the gastrointestinal tract and malignant gastrointestinal neuroectodermal tumour: distinct or related entities? A review. *Pathology* 2018; **50**:490–498.
- Stockman DL, Miettinen M, Suster S, Spagnolo D, Dominguez-Malagon H, Hornick JL, *et al.* Malignant gastrointestinal neuroectodermal tumor: clinicopathologic, immunohistochemical, ultrastructural, and molecular analysis of 16 cases with a reappraisal of clear cell sarcoma-like tumors of the gastrointestinal tract. *Am J Surg Pathol* 2012; **36**:857–868.
- Chung EB, Enzinger FM. Malignant melanoma of soft parts. A reassessment of clear cell sarcoma. *Am J Surg Pathol* 1983; **7**:405–413.
- Ekfors TO, Kujari H, Isomäki M. Clear cell sarcoma of tendons and aponeuroses (malignant melanoma of soft parts) in the duodenum: the first visceral case. *Histopathology* 1993; **22**:255–259.
- Zambrano E, Reyes-Mugica M, Franchi A, Rosai J. An osteoclast-rich tumor of the gastrointestinal tract with features resembling clear cell sarcoma of soft parts: reports of 6 cases of a GIST simulator. *Int J Surg Pathol* 2003; **11**:75–81.
- Antonescu CR, Nafa K, Segal NH, Dal Cin P, Ladanyi M. EWS-CREB1: a recurrent variant fusion in clear cell sarcoma—association with gastrointestinal location and absence of melanocytic differentiation. *Clin Cancer Res* 2006; **12**:5356–5362.
- Friedrichs N, Testi MA, Moiraghi L, Modena P, Paggen E, Plötner A, *et al.* Clear cell sarcoma-like tumor with osteoclast-like giant cells in the small bowel: further evidence for a new tumor entity. *Int J Surg Pathol* 2005; **13**:313–318.
- Kosemehmetoglu K, Folpe AL. Clear cell sarcoma of tendons and aponeuroses, and osteoclast-rich tumour of the gastrointestinal tract with features resembling clear cell sarcoma of soft parts: a review and update. *J Clin Pathol* 2010; **63**:416–423.
- Huang W, Zhang X, Li D, Chen J, Meng K, Wang Y, *et al.* Osteoclast-rich tumor of the gastrointestinal tract with features resembling those of clear cell sarcoma of soft parts. *Virchows Arch* 2006; **448**:200–203.
- Wang J, Thway K. Clear cell sarcoma-like tumor of the gastrointestinal tract: an evolving entity. *Arch Pathol Lab Med* 2015; **139**:407–412.
- Jones RL, Constantinidou A, Thway K, Ashley S, Scurr M, Al-Muderis O, *et al.* Chemotherapy in clear cell sarcoma. *Med Oncol* 2011; **28**:859–863.
- Kawai A, Hosono A, Nakayama R, Matsumine A, Matsumoto S, Ueda T, *et al.*; Japanese Musculoskeletal Oncology Group. Clear cell sarcoma of tendons and aponeuroses: a study of 75 patients. *Cancer* 2007; **109**:109–116.
- Tazzari M, Palassini E, Vergani B, Villa A, Rini F, Negri T, *et al.* Melan-A/MART-1 immunity in a EWS-ATF1 translocated clear cell sarcoma patient treated with sunitinib: a case report. *BMC Cancer* 2015; **15**:58.
- Balkaransingh P, Saad SA, Govil SC, Thind PK, Ballance CM, Weiss AR. Clear cell sarcoma of the gastrointestinal tract presenting as a second malignant neoplasm following neuroblastoma in infancy. *Pediatr Blood Cancer* 2012; **58**:481–482.
- Yang JC, Chou AJ, Oeffinger KC, La Quaglia MP, Wolden SL. Clear cell sarcoma of the gastrointestinal tract after very low-dose therapeutic radiation therapy: a case report. *J Pediatr Surg* 2012; **47**:1943–1945.
- Thway K, Judson I, Fisher C. Clear cell sarcoma-like tumor of the gastrointestinal tract, presenting as a second malignancy after childhood hepatoblastoma. *Case Rep Med* 2014; **2014**:984369.
- Rubino C, Adjadj E, Guérin S, Guibout C, Shamsaldin A, Dondon MG, *et al.* Long-term risk of second malignant neoplasms after neuroblastoma in childhood: role of treatment. *Int J Cancer* 2003; **107**:791–796.