



Contents lists available at ScienceDirect

Journal of Cranio-Maxillo-Facial Surgery

journal homepage: www.jcmfs.com

Levator alae nasi muscle V–Y island flap for nasal tip reconstruction

Simone La Padula ^{a,*}, Vincenzo Abbate ^b, Gianluca Di Monta ^c, Fabrizio Schonauer ^d^a Department of Plastic and Reconstructive Surgery, University of Naples Federico II, Via Pansini 5, 80131 Napoli, Italy^b Department of Maxillofacial Surgery, A.O.U. Federico II, 80131 Naples, Italy^c Department of Surgery "Melanoma, Soft Tissues, Head and Neck, Skin Cancers", Istituto Nazionale dei Tumori Fondazione Pascale Napoli, 80131 Naples, Italy^d Department of Plastic and Reconstructive Surgery, A.O.U. Federico II, 80131 Naples, Italy

ARTICLE INFO

Article history:

Paper received 7 September 2016

Accepted 15 December 2016

Available online 21 December 2016

Keywords:

Nasal tip reconstruction

V–Y advancement flap

Island flap

Nasal tip skin cancers

Basal cells carcinoma

Levator alae nasi muscle

ABSTRACT

Nasal tip reconstruction can be very challenging. It requires close attention to skin texture, colour and thickness matching, with the respect of the nasal aesthetic units and symmetry. Flaps are usually preferred to skin grafts where possible. Based on different donor areas, various flaps have been described for reconstruction of this region. Here we present a new V–Y myocutaneous island flap based on the levator alae nasi muscle (LAN muscle) blood supply. This flap may represent an alternative to the nasalis myocutaneous sliding V–Y flap previously described by Rybka. As its pivot point it is located more cranially than the nasalis flap, and it can advance more medially than the Rybka flap, with the possibility of covering larger defects of the nasal tip area, up to 1.8 cm in diameter. Over the past 5 years, 24 patients received nasal tip reconstruction with this flap following the resection of basal cell carcinomas. Good tip projection was maintained, and the aesthetic outcome was satisfactory, with well healed scars. We recommend this technique as an alternative to other flaps for nasal tip defects, especially if paramedian.

© 2016 European Association for Cranio-Maxillo-Facial Surgery. Published by Elsevier Ltd. All rights reserved.

1. Introduction

Soft tissue reconstruction of the nasal tip can be challenging. Aesthetic nasal reconstruction requires close attention to skin texture, colour and thickness matching with respect to nasal aesthetic units and symmetry (Raschke et al., 2012; Arginelli et al., 2016). Flaps are usually preferred to skin grafts where possible. Various flaps have been described for reconstruction of this region, based on different donor areas (Zimany, 1953; Rieger, 1967; Rintala and Asko-Seljavaara, 1969). Most recently Guo et al. developed a simple algorithm on flap choice for the management of nasal defects. Different techniques can often be used interchangeably, but certain flaps work better in different areas; the choice may be guided by orientation of the defect (horizontal defects are better closed with flaps that move down vertically such as glabellar flap or Rintala flap, while vertical defects are better managed with advancement flaps or nasolabial flaps) (Guo et al., 2008). Here we present a V–Y musculo-cutaneous island flap based on the levator alae nasi muscle (LAN muscle) blood supply. It should be

preferentially used for paramedian nasal tip defects. This technique has been used in 24 patients to restore skin defects of the tip area, after skin tumor excision. The flap has shown reliability in terms of blood supply, range of movement and donor site closure.

2. Materials and methods

The V–Y musculo-cutaneous island flap based on the levator alae nasi muscle was used in 24 patients to restore skin defects of the tip area, after skin tumor excision. Digital photographs were taken at baseline and 12 months after surgery to assess the clinical outcomes.

Written informed consent for research publication of patient-related data was obtained from each patient. Our study protocol conformed to the ethical guidelines of the 1975 Declaration of Helsinki as reflected in approval by the institution's or an independent human research review committee.

2.1. Anatomy

The LAN muscle (part of the levator labii superioris alaeque nasi) is a paired tubular muscle of the nose and is part of the nasal SMAS. This muscle originates from the medial part of the orbicularis oculi

* Corresponding author. Fax: +39 081 7462843.

E-mail address: drsimonelpadula@gmail.com (S. La Padula).

muscle and frontal process of the maxilla, and inserts into the lateral part of the ala nasi. Its medial nasal fascicles cover the origin of the transverse portion of the nasalis. This muscle elevates the ala nasi and widens the nostril in conjunction with the alar part of the nasalis (Letourneau and Daniel, 1988; Wee et al., 1990). Branches from the angular artery and vein provide its vascularisation.

2.2. Technique

After the expected defect was outlined, the LAN muscle was detected, asking the patient to move upward the ala nasi, and marked. Just lateral to the defect a triangular-shaped island flap was planned, centering the island on the distal insertion of the LAN muscle (Fig. 1). Surgery was performed under local anaesthetic with lidocaine with adrenaline 1:100,000. After the excision was performed, the maximum length of the defect was measured. Flap dissection was performed following two different surgical planes. After skin incision at the periphery of the flap, at its caudal edge, dissection was carried out in a submuscular plane, above the alar and triangular cartilage perichondrium. The under-surface of the LAN muscle was dissected up to its cranial origin, which remained intact. The muscle fibres were then laterally released from the insertion on the homolateral orbicularis oris and freed from the lateral portion of the nasalis muscle (Fig. 2). The cranial skin edge of the flap island was dissected in a subcutaneous plane for about 2–3 cm on the top of the LAN muscle (Fig. 3). When

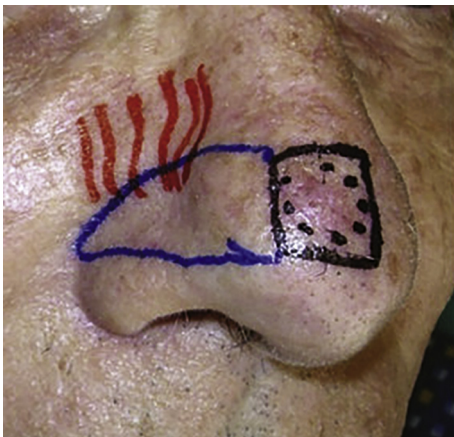

Fig. 1. Planning of the flap.

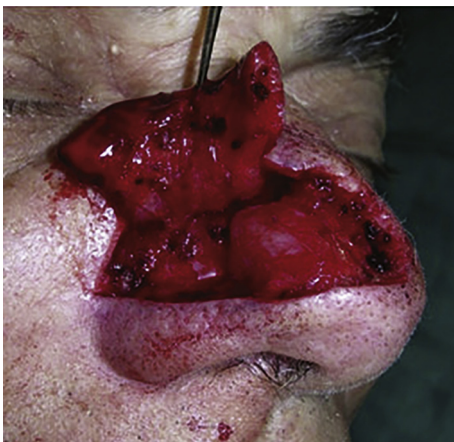

Fig. 2. Flap lifted upwards; plane dissected under the muscle.

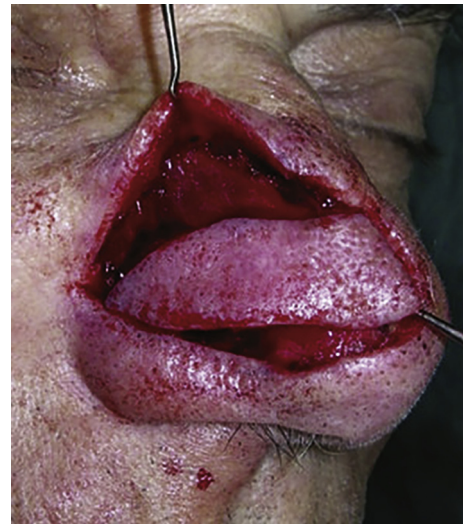

Fig. 3. Dissected subcutaneous plane above the levator alae nasi (LAN) muscle and flap advancement.

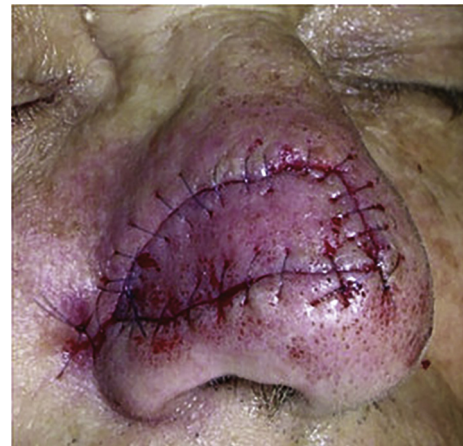

Fig. 4. Flap advanced in the defect and final closure.

Table 1
Patient data.

Patient	Age	Gender	Defect location	Defect size (cm)
1	36	M	Nasal tip (paramedian)	1.8 × 1.2
2	44	M	Domal-alar groove	0.9 × 1.2
3	38	M	Nasal tip (midline)	1.3 × 1.8
4	65	M	Nasal tip (paramedian)	1.8 × 1.1
5	45	M	Nasal tip (midline)	1.2 × 0.5
6	68	M	Nasal tip (midline)	1.8 × 1.3
7	71	M	Nasal tip (midline)	1.8 × 1.5
8	75	M	Nasal tip (midline)	2.6 × 1.6
9	43	M	Nasal tip (midline)	1.7 × 1.5
10	55	M	Nasal tip (midline)	1.5 × 1.8
11	52	M	Nasal tip (paramedian)	1.8 × 1.2
12	49	M	Nasal tip (paramedian)	1.3 × 1.5
13	55	M	Nasal tip (paramedian)	1.7 × 1.3
14	47	M	Nasal tip (paramedian)	1.8 × 1.5
15	50	M	Nasal tip (midline)	1.8 × 1.3
16	73	F	Nasal tip (midline)	1.3 × 1.2
17	58	F	Nasal tip (midline)	1.5 × 1.4
18	67	F	Nasal tip (midline)	1.6 × 1.0
19	51	F	Nasal tip (midline)	1.3 × 1.6
20	65	F	Nasal tip (paramedian)	1.3 × 1.2
21	49	F	Nasal tip (paramedian)	1.5 × 1.0
22	59	F	Nasal tip (paramedian)	1.7 × 0.9
23	56	F	Nasal tip (midline)	1.8 × 0.9
24	75	F	Nasal tip (midline)	1.7 × 1.2

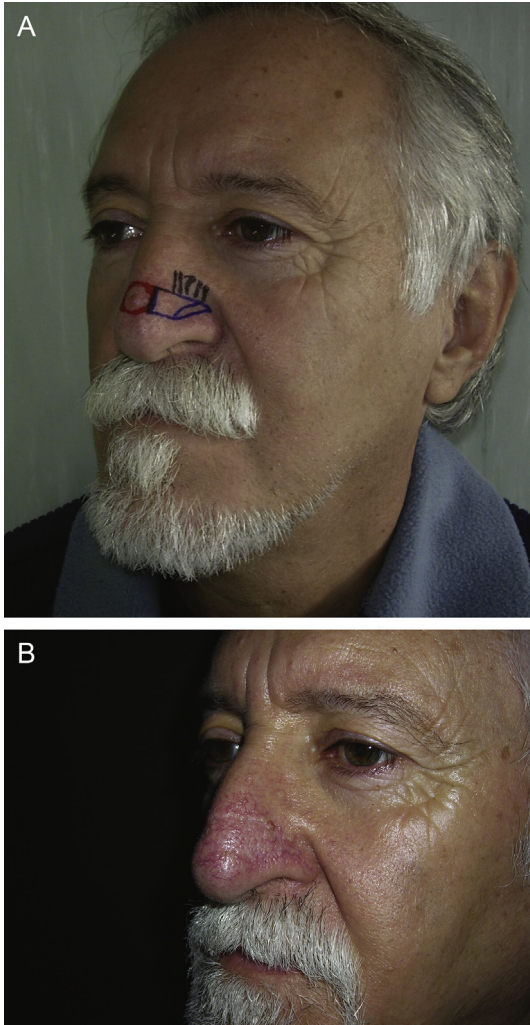


Fig. 5. (A) Patient with a midline basal cell carcinoma of the nasal tip. (B) The same patient at 12-month follow-up.

dissection was complete, the flap was free to swing towards the tip of the nose, having the cranial origin of the LAN muscle as its pivot point. 5/0 Monocryl and 6/0 Ethilon were used for flap inseting (Fig. 4).

3. Results

Between 2006 and 2011, a total of 24 patients underwent nasal tip reconstruction with this flap (15 male and 9 female, aged 36–75 years) (Table 1). The majority of the defects followed the excision of a basal cell carcinoma, resected with 3- to 5-mm margins. The maximum diameter of the defect, reconstructed with a single flap, was 1.8 cm. A defect of 2.6 cm × 1.6 cm was reconstructed with a bilateral V–Y LAN muscle flap. In 8 patients, the tumour involved only skin and subcutaneous tissue; in 2 patients the excision included a portion of the underlying cartilage. No major complication was recorded.

Flaps survived in all of the reported cases. In one patient, a heavy smoker, the flap developed a marginal superficial necrosis, which healed with conservative treatment.

Histology showed complete excision of the tumour in all cases. No patient showed recurrence at a mean 14-month follow-up. Good tip projection was maintained and aesthetic outcome was judged to be satisfactory by all of the patients with well healed scars (Figs. 5 and 6).

4. Discussion

The use of flaps from the nasal ala has aesthetic advantages over vertical flaps such as the Rintala or Rieger flap in respecting the natural crease line leading to the nasal tip (Wee et al., 1990) and avoiding both redundant tissue (dog ears) and chronic edema. This is true even considering that most nasal tip lesions are not exactly located on the midline but slightly paramedian. Furthermore, most surgical procedures are directed towards restoration of nasal aesthetic subunits (Burget and Menick, 1985).

In 1983, Rybka presented a V–Y myocutaneous sliding flap, based on the lower portion of the nasalis muscle, which was used to cover nasal tip defects up to 1.5 cm in diameter (Rybka, 1983).

Several authors have described various modifications in recent decades (Staaahl, 1986; Doermann et al., 1989; Wee et al., 1990; Constantine, 1991; Jourdain et al., 1999; Hunt, 2000; Asgari and Odland, 2005).

In 1989, Sakai et al. described a small nasalis musculocutaneous flap used to close the upper part of a nasolabial flap donor site defect. The flap was laterally pedicled on the nasalis muscle (Sakai et al., 1989).

Papadopoulos et al. and Willey et al. recently presented modifications of the technique to achieve additional flap mobility (Papadopoulos et al., 2002; Willey et al., 2008).

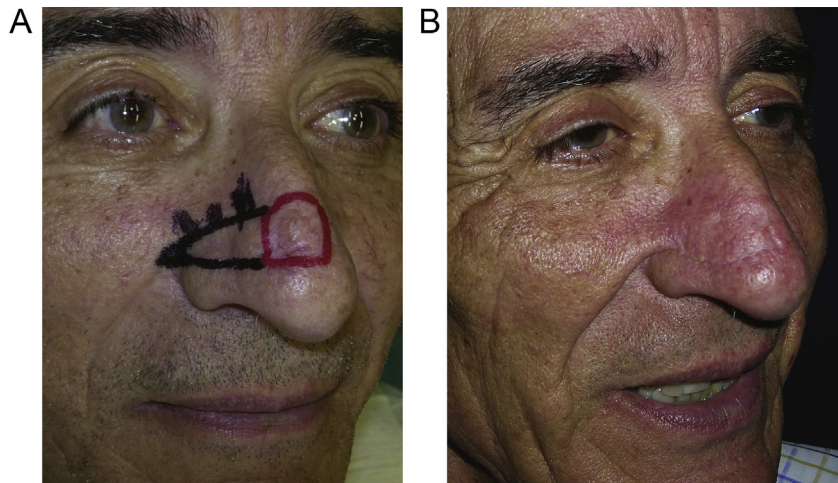


Fig. 6. (A) Patient with a paramedian basal cell carcinoma of the nasal dorsum. (B) The same patient at 12-month follow-up.

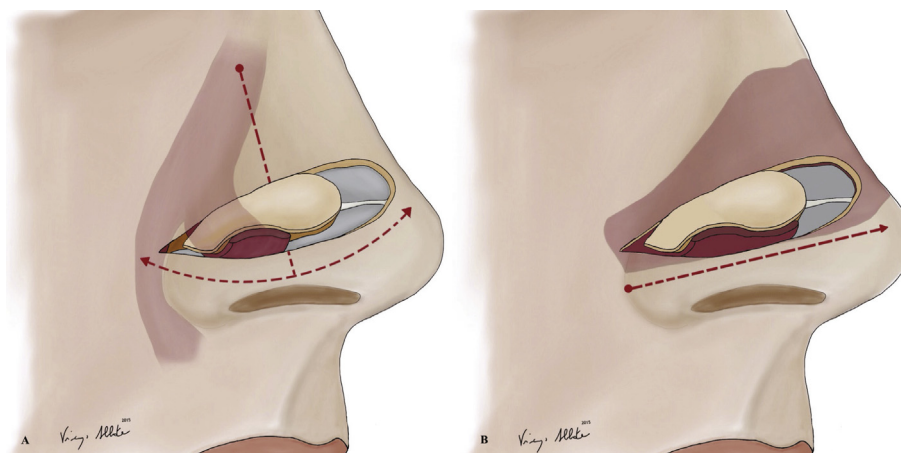


Fig. 7. Difference between the flap described by the authors and the Rybka flap. In the V–Y sliding flap based on the LAN muscle (A), described by the authors, the pivot point is located more cranially than the nasalis flap described by Rybka (B); this leads to a greater mobility of the flap.

Again the flap described was based on the nasalis muscle blood supply.

To date there has been no report describing the use of the LAN muscle myocutaneous flap for nasal tip repair.

In the V–Y sliding flap based on the LAN muscle, described by the authors, the skin island is very similar, whereas the pivot point is located more cranially than the nasalis flap described by Rybka. This leads to a greater mobility of the flap: it can advance more medially than the nasalis flap, with the possibility of covering larger defects of the nasal tip area, up to 1.8 cm in diameter (Fig. 7). Bilateral flaps can be used to close wider defects.

5. Conclusion

The LAN muscle V–Y island flap provides excellent colour, texture and thickness match with the adjacent skin. Its versatility and the reliability of its blood supply make it a good flap alternative in the reconstruction of midline or paramedian nasal tip defects. The procedure is safe and easy to perform.

We advocate this approach for reconstructing suitable defects of the tip of the nose.

Conflict of interest statement

The authors declare that they have no conflict of interest.

References

Arginelli F, Salgarelli AC, Ferrari B, Losi A, Bellini P, Magnoni C: Crescentic flap for the reconstruction of the nose after skin cancer resection. *J Craniomaxillofac Surg* 44: 703–707, 2016

- Asgari M, Odland P: Nasalis island pedicle flap in nasal ala reconstruction. *Dermatol Surg* 31: 448–452, 2005
- Burget GC, Menick FJ: The subunit principle in nasal reconstruction. *Plast Reconstr Surg* 76: 239–247, 1985
- Constantine VS: Nasalis myocutaneous sliding flap: repair of nasal supratip defects. *J Dermatol Surg Oncol* 17: 439–444, 1991
- Doermann A, Hauter D, Zook EG, Russell RC: V-Y advancement flaps for closure of nasal defects. *Plast Reconstr Surg* 84: 916–920, 1989
- Guo L, Pribaz JR, Pribaz JJ: Nasal reconstruction with local flaps: a simple algorithm for management of small defects. *Plast Reconstr Surg* 122: 130–139, 2008
- Hunt MJ: Reconstruction of the nasal tip using a nasalis myocutaneous flap. *Australas J Dermatol* 41: 52–54, 2000
- Jourdain A, Germain M, Demers G: Musculocutaneous flap of the transverse nasalis muscle in repair of nasal-tip skin carcinoma. *J Otolaryngol* 28: 37–42, 1999
- Letourneau A, Daniel RK: The superficial musculoaponeurotic system of the nose. *Plast Reconstr Surg* 82: 48–57, 1988
- Papadopoulos DJ, Pharis DB, Munavalli GS, Trinei F, Hantzakos AG: Nasalis myocutaneous island pedicle flap with bilevel undermining for repair of lateral nasal defects. *Dermatol Surg* 28: 190–194, 2002
- Raschke GF, Rieger UM, Bader RD, Kirschbaum M, Eckardt N, Schultze-Mosgau S: Evaluation of nasal reconstruction procedures results. *J Craniomaxillofac Surg* 40: 743–749, 2012
- Rieger RA: A local flap for repair of the nasal tip. *Plast Reconstr Surg* 40: 147–149, 1967
- Rintala AE, Asko-Seljavaara S: Reconstruction of midline skin defects of the nose. *Scand J Plast Reconstr Surg* 3: 105–108, 1969
- Rybka FJ: Reconstruction of the nasal tip using nasalis myocutaneous sliding flaps. *Plast Reconstr Surg* 71: 40–44, 1983
- Sakai S, Soeda S, Okabe N: The nasalis musculocutaneous flap; a report of three cases. *Br J Plast Surg* 42: 695–699, 1989
- Staahl TE: Nasalis myocutaneous flap for nasal reconstruction. *Arch Otolaryngol Head Neck Surg* 112: 302–305, 1986
- Wee SS, Hruza GJ, Mustoe TA: Refinements of nasalis myocutaneous flap. *Ann Plast Surg* 25: 271–278, 1990
- Wiley A, Papadopoulos DJ, Swanson NA, Lee KK: Modified single-sling myocutaneous island pedicle flap: series of 61 reconstructions. *Dermatol Surg* 34: 1527–1535, 2008
- Zimany A: The bi-lobed flap. *Plast Reconstr Surg* 11: 424–434, 1953