



Contents lists available at ScienceDirect

Journal of Cranio-Maxillo-Facial Surgery

journal homepage: www.jcmfs.com

Reanimation of the paralyzed lids by cross-face nerve graft and platysma transfer

Federico Biglioli ^{a,1}, Matteo Zago ^{b,d,1}, Fabiana Allevi ^{a,1}, Daniela Ciprandi ^{b,1},
Giovanni Dell'Aversana Orabona ^{c,1}, Valentina Pucciarelli ^{b,1}, Dimitri Rabbiosi ^{a,1},
Ilaria Pacifici ^{b,1}, Filippo Tarabbia ^{c,1}, Chiarella Sforza ^{b,*,1}

^a Maxillo-Facial Surgical Unit, Ospedale San Paolo, Dipartimento di Scienze della Salute, (Director, professor Stefano Centanni), Facoltà di Medicina e Chirurgia, Università degli Studi di Milano, Italy

^b Functional Anatomy Research Center (FARC), Laboratorio di Anatomia Funzionale dell'Apparato Stomatognatico (LAFAS), Laboratorio di Anatomia Funzionale dell'Apparato Locomotore (LAFAL), Dipartimento di Scienze Biomediche per la Salute, (Director, professor Francesco Auxilia), Facoltà di Medicina e Chirurgia, Università degli Studi di Milano, via Mangiagalli 31, I-20133 Milano, Italy

^c Department of Neurosciences, (Director Professor Luigi Califano), Reproductive and Odontostomatological Sciences, Division of Maxillofacial Surgery, University of Naples "Federico II", Naples, Italy

^d Department of Electronics, Information and Bioengineering (DEIB), (Director, professor Stefano Tubaro), Politecnico di Milano, Milano, Italy

ARTICLE INFO

Article history:

Paper received 23 July 2017

Accepted 18 December 2017

Available online xxx

Keywords:

Eyelids
Facial nerve paresis
Mimetics
Photography
Platysma

ABSTRACT

Alterations of facial muscles may critically hamper patients' quality of life. One of the worst conditions is the reduction or abolition of eye blinking. To prevent these adverse effects, surgical rehabilitation of eyelid function is the current treatment choice. In the present paper, we present a modification of the technique devised by Nassif to recover lids from long-standing paralysis. In our modification, the upper lid is rehabilitated by a platysma graft innervated by the contralateral facial nerve branches using a cross-face sural nerve graft. The lower lid is pulled upward by a fascia lata string suspension. Fourteen patients with unilateral facial paralysis were operated on consecutively. For each patient, two sets of frontal photographs with open and closed eyes were available, before and after the surgical rehabilitation. On average, eyelid lumen with closed eyes decreased by 2.6 mm (SD 2.4) after surgical rehabilitation (37% of the initial value). With open eyes, the decrement was 1.5 mm (SD 1.6, 15%). The modifications were highly significant ($p < 0.01$), with very large effect sizes. Reanimation of the paralyzed eye by mean of cross-face nerve graft followed by platysma neurotization can restore natural eyelid closure and blink reflex.

© 2018 European Association for Cranio-Maxillo-Facial Surgery. Published by Elsevier Ltd. All rights reserved.

1. Introduction

Facial paralysis entails morphological, psychological and functional deficits. Among the last ones, coverage of the cornea and its lubrication is the main one, because its deficit leads to inflammations, lesions, ulcerations, up to loss of vision because of deep ophthalmitis (Allevi et al., 2014).

Normal health of the cornea is due to its coverage by voluntary closure of the eyelids and involuntary blinking up to 10–19 times per minute (Sforza et al., 2008), the last being influenced by many

variables. The goal of blinking is leading the tear fluid produced by the lacrimal gland superolaterally in the orbit to the lacrimal points, medially located, in order to shed it over the cornea.

If the orbicularis oculi muscle is paralyzed for a long time (more than 18–24 months), its neurotization by neurotomy to a new motor nerve is not suitable because of its irreversible atrophy and new technical solutions must be undertaken (Biglioli, 2015a). Those may be subdivided into the following: mechanical means: mainly lid weights or palpebral springs (Demirci and Frueh, 2009; Yu et al., 2011; Bianchi et al., 2014); static surgical procedures: tarsorrhaphy, fascia lata suspensions, levator muscle elongation (Guillou-Jamard et al., 2011); and dynamic surgical procedures: rotation of temporalis flaps, muscle grafting, free flaps transposition (Deutinger and Freilinger, 1991; Frey et al., 2004).

Those procedures aim to restore voluntary eyelid closure, but two main problems remain open. All techniques other than those

* Corresponding author. Department of Biomedical Sciences for Health, Università degli Studi di Milano, via Mangiagalli 31, 20133 Milan, Italy. Fax: +39 0250315387.

E-mail address: Chiarella.sforza@unimi.it (C. Sforza).

¹ The authors received no grants for the investigation.

utilizing a cross-face nerve graft fail to have a natural stimulus to eyelid closure. That means that the patient has to think about what to do in order to obtain the desired movement (for example, relaxing the tone of the levator palpebrae in order to allow the weight set into the upper lid to descent while being in an upward position). All this is tiring for the patient, who consequently does not use much that function.

The second problem is that, being those procedures based on a voluntary stimulus, involuntary blink reflex and consequent lubrication of the cornea are highly reduced.

Only procedures based on contralateral healthy facial nerve stimulus, carried by a cross-face nerve graft coupled with a free-flap or a muscle graft, may re-establish a successful voluntary and spontaneous blinking. Results are variable, however, because quantities of axons growing through long nerve grafts are variable.

At the International Facial Nerve Symposium in Rome in 2009, Dr. Nassif proposed a technique to recover lids from paralysis based on platysma grafts transposition to the upper and lower lids, innervated by the contralateral facial nerve branches by mean of two cross-face sural nerve grafts.

In the current study, the authors present a modification of this technique, rehabilitating only the upper lid by platysma graft plus a cross-face sural nerve graft. The lower lid is pulled upward by a simple fascia lata string suspension.

Treatment planning in facial palsy and patient follow-up need a thorough clinical assessment that should be supplemented by objective, quantitative evaluations to be shared among treatment centers, allowing the comparison of the various techniques and the identification of the best treatment choices. Currently, facial palsy is clinically assessed by various scales, as recently reviewed by [Fattah et al. \(2015\)](#), while quantitative information about the movements of selected facial landmarks is provided by optical motion capture systems ([Sforza et al., 2008, 2015, 2012](#); [Tzou et al., 2012](#)). Unfortunately, these instruments are not widespread, and their use is often limited to research centers. In some occasions, quantitative evaluations can be performed using simple and low-cost methods such as photography, provided that a well-defined and repeatable protocol is provided ([Driessen et al., 2011](#); [Riml et al., 2011](#); [Choi and Eo, 2014](#); [Snyder-Warwick et al., 2015](#); [Pavese et al., 2016](#)).

In particular, the correction of eyelid motion and the reduction of lagophthalmos can be quantitatively assessed by post-treatment frontal facial photographs, one of the most widely diffused clinical records, to be compared to pre-treatment images. In our laboratory, we developed a standardized photographic technique that allows a quantitative assessment of eyelid position and lagophthalmos ([Zago et al., 2017](#)). The method employs the constancy of iris diameter to standardize facial dimensions ([Spörri et al., 2004](#); [Driessen et al., 2011](#)).

In the current investigation, we present the clinical and objective quantitative results of the modified surgical technique for the rehabilitation of paralyzed eyelids.

2. Materials and methods

2.1. Surgical technique

The following are a two-part surgical procedure.

2.1.1. First operation

A 20/25-cm tract of the sural nerve is harvested, traditionally in the leg. Contemporarily, on the healthy side of the face, a second surgical team makes a face-lift type of incision, extended 6–8 cm into the temporalis region to a few centimeters backward to the earlobe. The skin is elevated into a subcutaneous plane of dissection up to 2 cm medial to the anterior margin of the parotid gland. A few

millimeters ahead of the anterior margin of the parotid gland, immediately underneath the zygomatic arch, the superficial muscular aponeurotic system (SMAS) is opened up by dissecting the plane with the tips of the forceps parallel to the course of facial nerve branches, at a slight angle from inferolateral to supramedial. One or more white branches of the facial nerve, running over the red masseter background, are identified. Those are tested to ensure the activation of the upper half of the orbicularis oculi muscle. If the branch is too tiny or if it activates other parts of the facial mimetic musculature, surgical exposure of another branch must be done. The last step is repeated until a suitable branch of the facial nerve, with a proper caliber (at least 1-mm) is isolated. Now the harvested sural nerve graft is set into the face in a reverse position, its distal end joining the identified facial nerve branch and the proximal end reaching the paralyzed upper lid. Reverse grafting of the sural nerve is chosen in order to reduce axonal sprouting and loss from collateral branches during regrowth through the sural nerve. An epineural end-to-end anastomosis with 11/0 Prolene stitches is accomplished. The free end of the sural nerve is pulled subcutaneously to the paralyzed upper eyelid by a specific instrument. Here, through a small cutaneous incision in the upper lid sulcus, the nerve end is secured to the deeper layers by a non-absorbable 5/0 stitch.

Patients are tested by Tinel's sign 6 months after the first operation ([Moldaver, 1978](#)). If that is positive, the second operation takes place. If Tinel's sign is negative, the test is repeated every 2 months until it becomes positive. The second operation is carried out even in case of negative Tinel's sign 12 months after the first operation.

2.1.2. Second operation

A subcutaneous pocket is prepared in the upper paralyzed lid extending the incision of the previous operation into all the sulcus. The subcutaneous tissue of the lid is exposed for all its horizontal length and 2.5 cm of height.

The previously grafted sural nerve is identified and traced for 2–3 cm, freshening the free end by scissors. Care is taken to accomplish an accurate hemostasis.

Moving into the healthy side, a mid-neck skin crease is chosen to expose the platysma. Attention must be paid to coagulate as little as possible in order to maintain muscle fiber quality. Isolating first the superficial surface and then the deep one, a 5 × 2-cm rectangle of the muscle is harvested. At this point, a complete hemostasis is carried out. The rectangle is cut out in order to obtain a trapezium, with the minor base that will be secured to the upper lid margin and the major base that traces elliptically the upper half of the orbital margin, from the lateral canthus to the medial one.

A few 5/0 stitches of reabsorbable monofilament suture secure the graft in place.

Under an operating microscope, the free end of the nerve is subdivided into 2–4 fascicles, directly fixed into the platysma graft by 8/0 single stitches in order to neurotize it directly. Skin suture is accomplished in a standard way ([Fig. 1](#)).

2.2. Case series

Fourteen patients (7 men and 7 women; age range at time of surgery 18–67 years, mean 42 years, SD 14) were operated on consecutively by the senior surgeon (F.B.) between November 2009 and April 2012. All patients were affected by unilateral facial paralysis; 9 patients had a left-sided palsy, and 5 a right-sided one. The etiology of the palsy was oncological surgery (71%) and trauma (29%). Details are provided in [Table 1](#).

Before surgery, the patients underwent conventional clinical evaluations of their facial palsy, comprising facial photographs. They were re-assessed on average 9.3 months (SD 3; range 6–18

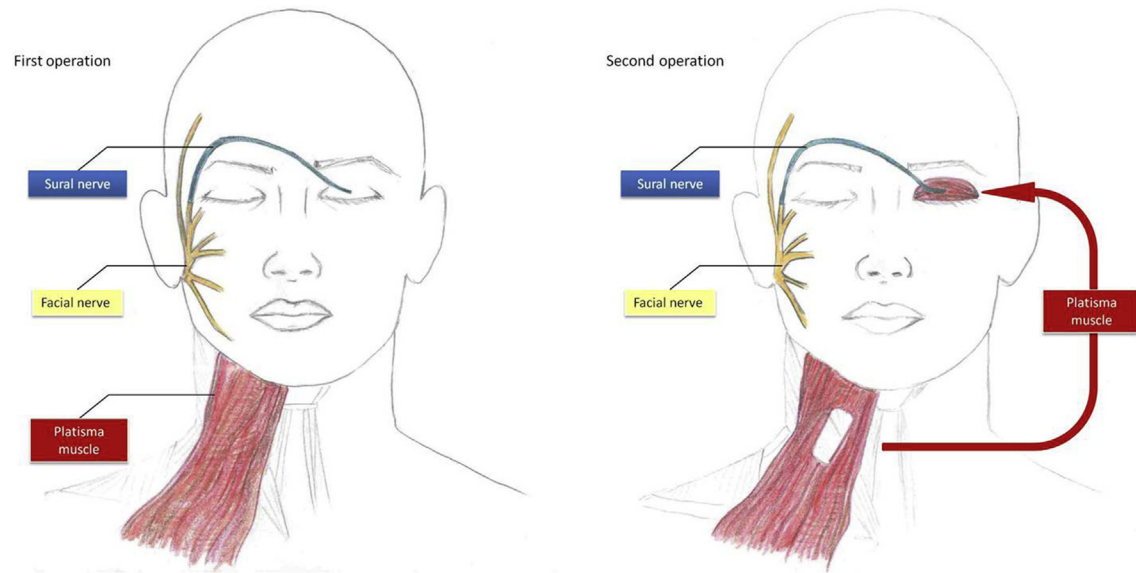


Fig. 1. First operation: The sural nerve graft (blue) is neurotrophied proximally to the facial nerve branch (yellow) and distally is set into the paralyzed upper lid. Second operation: The platysma rectangle is cut out and is set into the upper lid; the free end of the sural nerve is directly fixed into the platysma graft. Right: healthy side; left: paralyzed side.

months) after the second surgical intervention, when they detected a satisfactorily functional recovery, and a second set of frontal facial photographs was taken.

Patients were also asked to subjectively report the grade of discomfort that they had postoperatively compared to preoperatively (quantity of artificial tears still necessary, necessity to wear sunglasses, ability to stay outside on a windy day).

2.3. Data collection

For each patient, 2 sets of frontal photographs were available, before and after treatment. All pictures were obtained using a digital Nikon D80 camera with a 10.2-M pixel resolution. The measurement protocol is detailed by Zago et al. (2017). In brief, the patients were asked to look ahead in the direction of the camera; one picture was taken with open eyes, and one with closed eyes.

The photographs were analyzed using Adobe Photoshop CS3 (Adobe Systems Inc, San Jose, CA, USA). At first, the diameter in pixels of the iris was measured on the pre-surgical photograph as the maximum horizontal distance between both edges of the

transition between the white margin of the corneal limbus and the colored iris (Miot et al., 2009; Driessen et al., 2011). Subsequently, the distances between the interchantal line and the limits of the superior and inferior eyelids were measured, and eyelid lumen obtained as their sum (Zago et al., 2017). The measurements were performed on all photographs, with open or closed eyes, pre- and post-surgery (Fig. 2) in pixels, and subsequently converted into millimeters using the dimension of the maximum iris diameter (11.7 mm) (Driessen et al., 2011; Hashemi et al., 2015).

Palpebral closure was clinically classified as follows: a) complete closure of the lids upon voluntary stimulus; b) almost complete closure (up to 3 mm of residual open palpebral rim) upon voluntary closure; and c) insufficient closure (over 3 mm of residual open palpebral rim) upon voluntary closure.

2.4. Statistical analysis

Normality of data distribution was verified by the Jarque–Bera test; descriptive statistics (mean, SD) were computed for each condition (open and closed eyes).

Table 1
Analyzed patients and eyelid lumen variations.

| Patient no./ sex | Age at time of surgery (yr) | Etiology (year) | Surgical delay | Positive Tinell's sign (mo) | Eyelid lumen variation (mm) | | | |
|------------------|-----------------------------|--|----------------|-----------------------------|-----------------------------|-------|-------------|--------|
| | | | | | Open eyes | | Closed eyes | |
| | | | | | (mm) | (%) | (mm) | (%) |
| 1-M | 60 | Acoustic neuroma removal (2007) | 4 yr; 2 mo | 10 | -1.0 | -13.0 | 1.2 | 100.0 |
| 2-F | 47 | Acoustic neuroma removal (2010) | 9 mo | 6 | -2.2 | -17.9 | -5.4 | -61.4 |
| 3-F | 30 | Acoustic neuroma removal (2010) | 1 yr | 8 | -1.3 | -11.8 | -0.3 | -6.1 |
| 4-M | 48 | Facial trauma (2009) | 1 yr; 11 mo | 8 | 1.2 | -20.8 | 0.3 | 6.3 |
| 5-M | 57 | Acoustic neuroma removal (2007) | 2 yr; 4 mo | 6 | -2.2 | 5.6 | -1.7 | -71.4 |
| 6-M | 43 | Facial trauma (2009) | 12 mo | 6 | -1.4 | -13.2 | -2.4 | -56.7 |
| 7-F | 18 | Brainstem pilocytic astrocytoma (1996) | 13 yr; 7 mo | 10 | -1.4 | -14.8 | -1.4 | -44.4 |
| 8-F | 41 | Acoustic neuroma removal (2010) | 1 yr; 2 mo | 6 | -3.1 | -34.0 | -0.7 | -22.2 |
| 9-M | 33 | Facial trauma (2007) | 2 yr; 8 mo | 8 | 1.1 | 12.5 | -3.7 | -67.5 |
| 10-F | 20 | Cerebellar cavernous emangioma (1998) | 11 yr; 3 mo | 8 | -1.5 | -14.3 | -2.0 | -28.9 |
| 11-F | 67 | Acoustic neuroma removal (2009) | 1 yr; 10 mo | 6 | -5.1 | -45.7 | -8.2 | -100.0 |
| 12-F | 47 | Acoustic neuroma removal (2009) | 1 yr; 2 mo | 8 | -0.2 | -2.2 | -5.2 | -72.5 |
| 13-M | 40 | Facial trauma (2009) | 1 yr; 2 mo | 8 | -0.8 | -7.5 | -3.8 | -57.7 |
| 14-M | 38 | Middle ear cholesteatoma (2007) | 2 yr; 1 mo | 8 | -2.8 | -29.4 | -3.6 | -41.4 |

Surgical delay is the time between the beginning of the problem and the first surgical intervention. Negative variations in eyelid lumen indicate a post-surgical reduction.

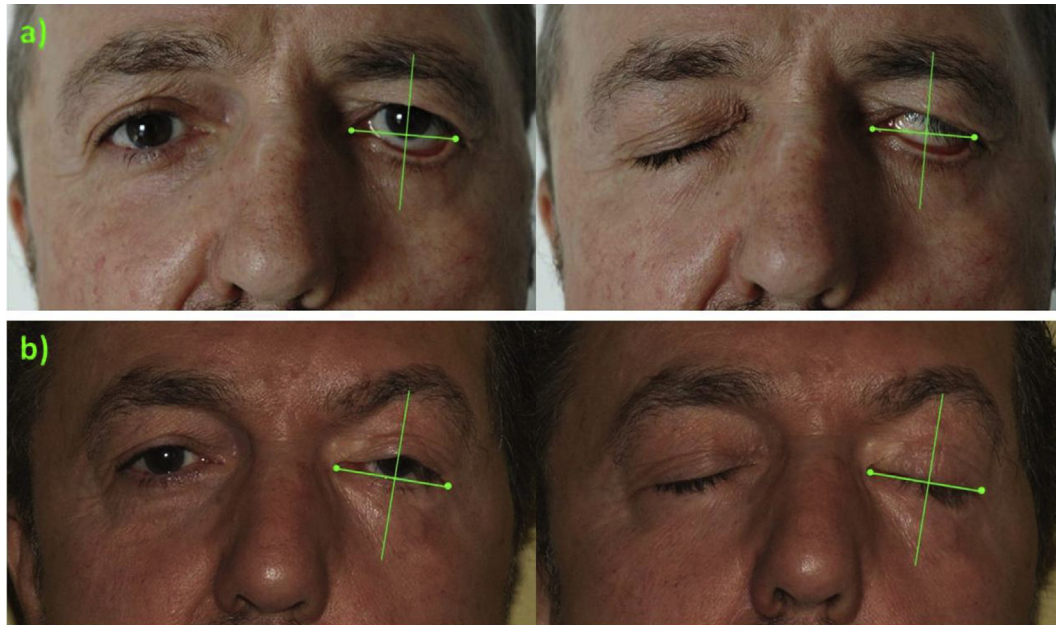


Fig. 2. Eyelid measurement: a) before surgical treatment; b) after surgical treatment.

Absolute and percentage (relative to the pre-treatment values) variations of the eyelid lumen were computed for all patients in both conditions. Pre- and post-treatment data in both conditions were compared using the Student *t*-tests for paired samples; a *p* value of 0.05 or less was considered significant. Cohen's *d* value was computed to estimate the effect size of the differences: the effect size was considered low for $d \leq 0.2$, moderate between 0.5 and 0.8, and large for $d > 0.8$ (Cohen, 1969).

3. Results

The mean operating time was 75 min for the first operation and 70 min for the second one. On average, the timing between first and second surgery was 9 months (between 7 and 11 months). The beginning of platysma contraction was observed at a median of 45 days postoperatively (range 30–55 days).

Palpebral closure upon voluntary closure was clinically classified as complete in 1 patient (7%), almost complete in 7 patients (50%), and insufficient in the other 6 patients (43%).

Table 1 reports the absolute and percentage variations of eyelid lumen in the open and closed eye conditions; negative values indicate a reduction of eyelid lumen after surgical treatment. The photographic assessment of eyelid lumen showed that the surgical procedure was successful for both eye conditions in 11 patients (79%), unsuccessful in 1 patient (7%), and partially successful in 2 patients (14%) who had a reduction of the eyelid lumen only in 1 condition each.

Fig. 3 shows the descriptive statistics of the eyelid lumen in the analyzed conditions. On average, eyelid lumen in the closed eyes condition decreased by 2.6 mm (SD 2.4), after surgical rehabilitation, corresponding to 37% (SD 47) of the initial value. In the open eye condition, the decrement was of 1.5 mm (SD 1.6), equivalent to 15% (SD 13). The modifications were highly significant both with open ($p = 0.005$, Student *t* for paired samples) and closed ($p = 0.002$) eyes, with very large effect sizes (Cohen's $d = 0.973$ for the open eyes condition; Cohen's $d = 1.03$ for the closed eye condition).

Subjectively, all patients except 1 reported a high satisfaction for the improved lubrication of their eye. Of the patients 57% reported

that they did not need artificial tears anymore. The remaining patients, except for the sole unsuccessful case patient, reduced greatly the numbers of time that they used to apply artificial tears. All patients still wore sunglasses on sunny days and avoided eye exposure during windy days. All reported less eye suffering than prior to reconstructive surgery.

According to the ophthalmologist report, no corneal lesion could be detected in any patient except for the patient who experienced failure of the procedure. Later, this patient underwent a successful intervention of split temporalis flap rotation (Deutinger and Freilinger, 1991) to improve eyelid closure. Blinking comparable to healthy side could not be achieved by that surgery.

Esthetics of the upper lid was partially burdened by the procedure, with a visible thickening of it and lower position of the lid at rest in vertical position (1–2 mm) in 5 (36%) patients.

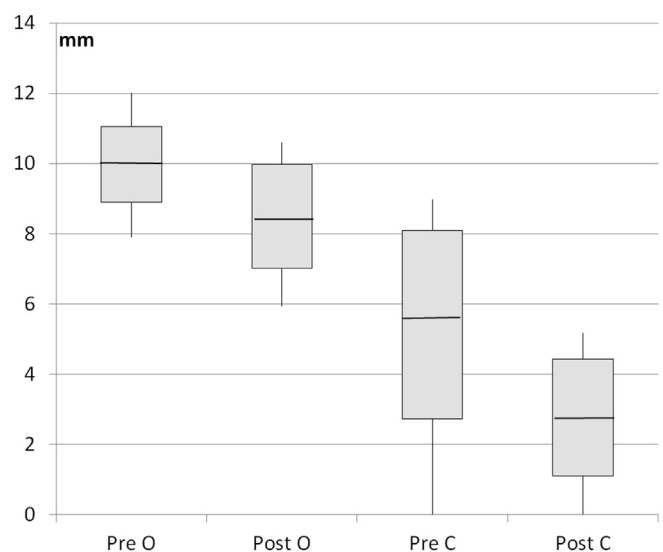


Fig. 3. Box plots of the eyelid lumen before and after surgical rehabilitation with open (O) and closed (C) eyes.

There was a complication in 1 patient (7%), who suffered of a perioperative graft infection evident on day 15, which was cured by antibiotic treatment (amoxicillin + clavulanic acid, 1-g tablets every 8 h for 2 weeks). Healing led to a partial closure of the eyelid, which was cured by secondary refinement surgery under local anesthesia.

Irreversible edema of the lid was observed in 1 patient (7%), leading to a surgical revision under local anesthesia after 12 months. Temporary weakening of the orbicularis oculi function on the healthy side was observed in 1 patient (7%) and resolved spontaneously within 3 months (online Video 1).

Supplementary video related to this article can be found at <https://doi.org/10.1016/j.jcms.2017.12.022>.

4. Discussion

Most popular techniques used to achieve eyelid closure in facial palsy patients do not utilize the natural facial nerve stimulus but, rather, completely different action systems. That generally leads to an underuse of the lid closure system. Following is an analysis of the 2 most widely used techniques. Insertion of lid weights (May, 1987) is an easy solution with the advantage of being feasible under local anesthesia. Its efficacy, however, is due to a complex series of actions to be accomplished by the patient: the levator palpebrae muscle, innervated by the third cranial nerve, must lose its tone and relax while the patient is in an upright position in order to let the upper lid descend and cover the eye. Achievement of those conditions is stressful and tiring for these patients, who generally do not apply them as much as necessary. Also, the foreign body often bothers the patients, is aesthetically unpleasant, and it is associated with a high percentage of extrusions through the skin over time (Biglioli, 2015b).

Temporalis flap rotation (Deutinger and Freilinger, 1991) allows patients to close the eyelids while intentionally chewing hard. Fortunately it is rare to close the eyelids unintentionally while eating, although not impossible. The patients gets bored quickly of this unnatural stimulus. The consequent low use of the muscle leads to only partial amelioration of the corneal health.

In order to protect the cornea, the blinking reflex is at least as important as spontaneous closure of the eyelids. It consists of the automatic closure of the eyelids controlled by the facial nerve that activates the orbicularis oculi function as a reflex of a stimulus applied over the cornea, eyelashes, lids, periorbital and frontal areas. Those are transduced by short and long ciliary nerves, supratrochlear and supraorbital nerves to the ciliary and trigeminal ganglions. From those, nuclei of III, V and VII nerves lead to the activation of ipsilateral and contralateral facial nerve branches to the orbicularis oculi muscles.

Frequency of blinking is impressive, with a median of 10–19 times per minute, depending on sex, age, external conditions, and activity of the patient in that specific moment (Sforza et al., 2008). The absence of blinking due to facial paralysis leads to serious clinical problems such as corneal abrasions and ulcers, exposure keratopathy, epiphora and, for the most severe lesions, loss of vision.

According to those concepts, the most complete reconstructive techniques to restore the mechanism of eyelid closure tend also to restore blinking. Those are cross-face facial nerve grafting followed by a neurotomy to the facial nerve branch for the orbicularis oculi in the case of recent paralysis (Biglioli et al., 2017) or to a motor nerve of a free muscle transfers in the case of long-standing paralysis (Frey et al., 2004), or direct neurotization of the orbicularis oculi muscle to treat paresis (Terzis and Anesti, 2012). The common denominator in all techniques is a stimulus arising from the contralateral healthy branch of the facial nerve for the orbicularis oculi muscle. That is the only nerve branch that allows an individual to voluntarily close the eyelids while thinking about doing it

(and not clenching the teeth, relaxing the levator palpebrae muscle or other substitutive actions) and to restore the lost blink reflex.

Before attempting cross-face rehabilitation of the orbicularis oculi muscle is absolutely necessary that the muscle itself maintained a residual ability to contract. That is the case with recent facial paralyzes (up to 24 months) and pareses. An electromyographic (EMG) evaluation assesses the presence of fibrillations of the orbicularis oculi. In case patients are affected by a complete palsy lasting longer than 24 months, when no fibrillations are detectable at EMG, new musculature must be grafted into the lids in place of the orbicularis oculi. Frey et al. proposed in 2004 to use a regionally differentiated part of a free gracilis muscle flap transplanted to also recover smiling. The method seemed highly functional but it had at least 2 negative aspects due to the power and the mass of the muscle: the excessive bulk of the lids after surgery and excessive strength of eyelids closure.

Terzis and Karypidis (2010) suggested using a free flap of platysma muscle. Although the technique proved to be very reliable, a similar result is achievable by a much easier platysma graft. That muscle is very thin, and neovascularization takes place in a few days.

Taking those considerations into account and getting ideas from the first attempts to transpose muscle grafts into the paralyzed face introduced by Thompson in 1976 to restore smiling, Nassif proposed, at the 2009 International Facial Nerve Symposium in Rome, to replace the entire orbicularis oculi muscle by a platysma graft harvested contralaterally. Innervation was provided by 2 cross-face nerves grafted in a previous operation and anastomized contralaterally to a facial nerve branch for the upper lid and one for the lower lid. Clinical results shown at the conference were impressive.

We choose to substitute only the upper part of the orbicularis oculi muscle, as the branch for the lower lid is very close to the one for the great zygomatic muscle. That one is routinely co-opted by the authors by another cross-face nerve graft to ensure natural smiling both voluntarily and in response to humorous situations (Sforza et al., 2015). In fact, the distal end of the graft is anastomized end-to-side to the contralateral branch for the great zygomatic muscle while making a masseteric-to-facial nerve anastomosis for recent paralyzes. For those patients with long-standing facial paralysis, the distal end of the cross-face nerve graft is anastomized end-to-side to the obturator nerve of a gracilis free flap also for the same purpose. Cutting 3 close branches of the healthy nerve (one for the upper lid, one for the lower lid, one for the great zygomatic muscle) could lead to a partial paralysis as a residual from surgery. Consequently the proposed solution is to perform the following: 1) a cross-face nerve graft for the upper lid, followed by a platysma graft 9 months later to reanimate the upper lid; 2) a lower lid suspension by a fascia lata string graft (Rose, 2005), avoiding cutting the healthy median nervous branch providing the lower lid.

A 2-time reconstructive technique involves a longer amount of time before obtaining results, more stress for the patient, and higher health care costs. The reason for not doing the reconstruction all in one operation is the high possibility of the grafted muscle to atrophy irreversibly before neurotization takes place. By cross-facing the nerve first, waiting for the axonal ingrowth to reach the free-end of the graft, neurotization of the platysma takes place immediately, and function of the muscle is evident after 45 days. It is likely that the quick functional recovery depends also on a rapid process of vascularization of the thin platysma graft.

The second operation is carried out even in cases of negative Tinel's sign 12 months after the first operation, because the reliability of negative Tinel's sign is not absolute, and it is highly likely that axonal ingrowth has already occurred at the end of the nerve graft.

A few patients have been followed up for 3 years. As Terzis and Karypidis (2010, 2011) already reported, clinical observations of videos lead to the impression that functional recovery increases as time passes.

In spite of all those considerations, the proposed technique does not lead to constant positive results. That could be due to several factors: 1) a paucity of axons growing through a cross-face nerve graft; 2) a weak axonal source (in fact, the tiny healthy facial nerve branch chosen as a motor source may not provide sufficient axonal ingrowth; conversely, a larger branch sacrifice could lead to an iatrogenic eyelid palsy; 3) it is well known that long nerve grafting is not completely reliable to carry on neural regrowth; and 4) direct neurotization is not as effective as end-to-end neurotization to the motor nerve proper of a specific muscle segment.

Considering the necessity to document objectively the results of the described surgical procedure, we introduced a quantitative photographic assessment. Indeed, photographic images are among the most widely used objective clinical records, but they are seldom employed for a quantitative assessment of the effects of treatment. Indeed, even small deviations in head positioning (flexion/extension) and camera angles can cause significant shortening or elongations of facial structures, thus making the measurements meaningless (Riml et al., 2011). Also, clinicians seldom include a scale in the photograph, and the quantitative comparison of longitudinal records is almost impossible (Spörri et al., 2004; Driessen et al., 2011).

To overcome the problems of image magnification, allowing the use of even pre-existing photographs, we devised a measurement protocol that employs the well-known constancy of iris diameter to standardize facial dimensions (Spörri et al., 2004; Driessen et al., 2011; Snyder-Warwick et al., 2015; Zago et al., 2017). The use of image calibrations based on the iris has been proposed since 2004, but, to the best of our knowledge, it has not previously been used for the assessment of lagophthalmos and eyelid position before our technical record. These structures are in the same coronal plane as the iris, and therefore do not need additional corrections for their anterior-posterior position (Driessen et al., 2011). In addition, slightly different head flexion and extension seem not to influence the values significantly (Riml et al., 2011).

5. Conclusion

Reanimation of the paralyzed eye by mean of cross-face nerve grafting followed by platysma neurotization seems to be a logical procedure to restore natural eyelid closure and blink reflex. A standardized photographic assessment can provide quantitative data for an objective evaluation of the procedure without additional costs or complex instrumentation.

Funding

The authors declare they received no funding for the current study.

Conflicts of interest

The authors declare they have no competing interests.

References

- Allevi F, Fogagnolo P, Rossetti L, Biglioli F: Eyelid reanimation, neurotisation, and transplantation of the cornea in a patient with facial palsy. *BMJ Case Rep* 19. <https://doi.org/10.1136/bcr-2014-205372>, 2014
- Bianchi B, Ferri A, Leporati M, Ferrari S, Lanfranco D, Ferri T, et al: Upper eyelid platinum chain placement for treating paralytic lagophthalmos. *J Craniomaxillofac Surg* 42: 2045–2048. <https://doi.org/10.1016/j.jcms.2014.09.012>, 2014
- Biglioli F: Facial reanimations: part I—recent paralyses. *Br J Oral Maxillofac Surg* 53: 901–906. <https://doi.org/10.1016/j.bjoms.2015.06.023>, 2015a

- Biglioli F: Facial reanimations: part II—long-standing paralyses. *Br J Oral Maxillofac Surg* 53: 907–912. <https://doi.org/10.1016/j.bjoms.2015.07.001>, 2015b
- Biglioli F, Colombo V, Rabbiosi D, Tarabbia F, Giovanditto F, Lozza A, et al: Masseteric-facial nerve neurotization: results of a case series. *J Neurosurg* 126: 312–318. <https://doi.org/10.3171/2015.12.JNS14601>, 2017
- Choi Y, Eo S: Two-dimensional analysis of palpebral opening in blepharoptosis: visual iris-pupil complex percentage by digital photography. *Ann Plast Surg* 72: 375–380. <https://doi.org/10.1097/SAP.0b013e318269e4c9>, 2014
- Cohen J: *Statistical power analysis for the behavioral sciences*. New York, NY: Academic Press, 1969
- Demirci H, Frueh BR: Palpebral spring in the management of lagophthalmos and exposure keratopathy secondary to facial nerve palsy. *Ophthalmic Plast Reconstr Surg* 25: 270–275. <https://doi.org/10.1097/IOP.0b013e3181ab6f08>, 2009
- Deutinger M, Freilinger G: Transfer of the temporal muscle for lagophthalmos according to Gillies. *Scand J Plast Reconstr Surg Hand Surg* 25: 151–154, 1991
- Driessen JP, Vuyk H, Borgstein J: New insights into facial anthropometry in digital photographs using iris dependent calibration. *Int J Pediatr Otorhinolaryngol* 75: 579–584. <https://doi.org/10.1016/j.ijporl.2011.01.023>, 2011
- Fattah AY, Gurusinghe AD, Gavilan J, Hadlock TA, Marcus JR, Marres H, et al, Sir Charles Bell Society: Facial nerve grading instruments: systematic review of the literature and suggestion for uniformity. *Plast Reconstr Surg* 135: 569–579, 2015
- Frey M, Giovanoli P, Tzou CH, Kropf N, Friedl S: Dynamic reconstruction of eye closure by muscle transposition or functional muscle transplantation in facial palsy. *Plast Reconstr Surg* 114: 865–875, 2004
- Guillou-Jamard MR, Labbé D, Bardot J, Benateau H: Paul Tessier's technique in the treatment of paralytic lagophthalmos by lengthening of the levator muscle: evaluation of 29 cases. *Ann Plast Surg* 67: S31–S35. <https://doi.org/10.1097/SAP.0b013e318218360b>, 2011
- Hashemi H, Khabazkhoob M, Emamian MH, Shariati M, Yekta A, Fotouhi A: White-to-white corneal diameter distribution in an adult population. *J Curr Ophthalmol* 27: 21–24. <https://doi.org/10.1016/j.joco.2015.09.001>, 2015
- May M: Gold weight and wire spring implants as alternatives to tarsorrhaphy. *Arch Otolaryngol Head Neck Surg* 113: 656–660, 1987
- Miot HA, Fernandes LPS, Jorge EN, Pivotto DR, Nogueira CR, Mazeto GMFS: Comparative evaluation of oculometric variables in graves' ophthalmopathy. *Clinics* 64: 885–889. <https://doi.org/10.1590/S1807-59322009000900009>, 2009
- Moldaver J: Tinel's sign. Its characteristics and significance. *J Bone Jt Surg Am* 60: 412–414, 1978
- Pavese C, Cecini M, Lozza A, Biglioli F, Lisi C, Bejor M, et al: Rehabilitation and functional recovery after masseteric-facial nerve anastomosis. *Eur J Phys Rehabil Med* 52: 379–388, 2016
- Riml S, Piontke A, Larcher L, Kompatscher P: Quantification of faults resulting from disregard of standardised facial photography. *J Plast Reconstr Aesthet Surg* 64: 898–901. <https://doi.org/10.1016/j.bjps.2010.11.005>, 2011
- Rose EH: Autogenous fascia lata grafts: clinical applications in reanimation of the totally or partially paralyzed face. *Plast Reconstr Surg* 116: 20–32, 2005 discussion 33–5
- Sforza C, Rango M, Galante D, Bresolin N, Ferrario VF: Spontaneous blinking in healthy persons: an optoelectronic study of eyelid motion. *Ophthalmic Physiol Opt* 28: 345–353. <https://doi.org/10.1111/j.1475-1313.2008.00577.x>, 2008
- Sforza C, Frigerio A, Mapelli A, Mandelli F, Sidequersky FV, Colombo V, et al: Facial movement before and after masseteric-facial nerves anastomosis: a three-dimensional optoelectronic pilot study. *J Craniomaxillofac Surg* 40: 473–479. <https://doi.org/10.1016/j.jcms.2011.07.004>, 2012
- Sforza C, Frigerio A, Mapelli A, Tarabbia F, Annoni I, Colombo V, et al: Double-powered free gracilis muscle transfer for smile reanimation: a longitudinal optoelectronic study. *J Plast Reconstr Aesthet Surg* 68: 930–939. <https://doi.org/10.1016/j.bjps.2015.03.029>, 2015
- Snyder-Warwick AK, Fattah AY, Zive L, Halliday W, Borschel GH, Zuker RM: The degree of facial movement following microvascular muscle transfer in pediatric facial reanimation depends on donor motor nerve axonal density. *Plast Reconstr Surg* 135: 370e–381e. <https://doi.org/10.1097/PRS.00000000000000860>, 2015
- Spörri S, Simmen D, Briner HR, Jones N: Objective assessment of tip projection and the nasolabial angle in rhinoplasty. *Arch Facial Plast Surg* 6: 295–298, 2004
- Terzis JK, Karypidis D: Blink restoration in adult facial paralysis. *Plast Reconstr Surg* 126: 126–139. <https://doi.org/10.1097/PRS.0b013e3181dbbf34>, 2010
- Terzis JK, Karypidis D: Outcomes of direct muscle neurotisation in adult facial paralysis. *J Plast Reconstr Aesthet Surg* 64: 174–184. <https://doi.org/10.1016/j.bjps.2010.04.045>, 2011
- Terzis JK, Anesti K: Experience with developmental facial paralysis: part II. Outcomes of reconstruction. *Plast Reconstr Surg* 129: 66e–80e. <https://doi.org/10.1097/PRS.0b013e3182362122>, 2012
- Tzou CH, Pona I, Placheta E, Hold A, Michaelidou M, Artner N, et al: Evolution of the 3-dimensional video system for facial motion analysis: ten years' experiences and recent developments. *Ann Plast Surg* 69: 173–185. <https://doi.org/10.1097/SAP.0b013e3182223d96>, 2012
- Yu Y, Sun J, Chen L, Liu L: Lid loading for treatment of paralytic lagophthalmos. *Aesthet Plast Surg* 35: 1165–1171. <https://doi.org/10.1007/s00266-011-9740-x>, 2011
- Zago M, Tarabbia F, Bassetti L, Biglioli F, Sforza C: Photographic technique for the quantitative assessment of lagophthalmos and eyelid position in patients with facial palsy. *Br J Oral Maxillofac Surg* 55: 548–550. <https://doi.org/10.1016/j.bjoms.2017.01.019>, 2017