


Accepted Manuscript

Sinonasal mucosal melanoma extended to nose bridge: a one-time reconstruction treatment report

Antonio Romano, Antonio Pansini, Vincenzo Abbate, Giovanni Salzano, Giovanni Dell'Aversana Orabona, Giorgio Iaconetta, Luigi Califano



PII: S2214-5419(17)30025-1
DOI: 10.1016/j.omsc.2017.11.001
Reference: OMSC 48
To appear in: *Oral and Maxillofacial Surgery Cases*
Received Date: 24 July 2017
Revised Date: 03 November 2017
Accepted Date: 07 November 2017

Please cite this article as: Antonio Romano, Antonio Pansini, Vincenzo Abbate, Giovanni Salzano, Giovanni Dell'Aversana Orabona, Giorgio Iaconetta, Luigi Califano, Sinonasal mucosal melanoma extended to nose bridge: a one-time reconstruction treatment report, *Oral and Maxillofacial Surgery Cases* (2017), doi: 10.1016/j.omsc.2017.11.001

This is a PDF file of an unedited manuscript that has been accepted for publication. As a service to our customers we are providing this early version of the manuscript. The manuscript will undergo copyediting, typesetting, and review of the resulting proof before it is published in its final form. Please note that during the production process errors may be discovered which could affect the content, and all legal disclaimers that apply to the journal pertain.

Sinonasal mucosal melanoma extended to nose bridge: a one-time reconstruction treatment report

Antonio Romano, Assistant Professor, Department of Maxillofacial Surgery, University of Naples Federico II, Naples, Italy,

Antonio Pansini, Resident , Department of Maxillofacial Surgery, University of Naples Federico II, Naples, Italy,

Vincenzo Abbate, Assistant Professor , Department of Maxillofacial Surgery, University of Naples Federico II , Naples, Italy

Giovanni Salzano, Resident , Department of Maxillofacial Surgery, University of Naples Federico II, Naples, Italy,

Giovanni Dell'Aversana Orabona, Assistant Professor , Department of Maxillofacial Surgery, University of Naples Federico II , Naples, Italy

Giorgio Iaconetta, Full Professor , Department of Neurosurgery, University of Salerno, Salerno, Italy,

Luigi Califano, Full Professor, Department of Maxillofacial Surgery, University of Naples Federico II, Naples, Italy,

Correspondence author:

Antonio Pansini MD,

Department of Maxillofacial Surgery, University of Naples Federico II, Naples, Italy.

Email: a.pansini86@gmail.com

Institutional address: via Pansini 5, Naples, Italy. Postal code: 80131 Telephone: 00390817462176

Fax number: 00390817462190 Mobile: 00393490890281

Running title

Sinonasal mucosal melanoma extended to nose bridge: a one-time reconstruction treatment report

Sinonasal mucosal melanoma extended to nose bridge: a one-time reconstruction treatment report

Highlights:

Sinonasal mucosal melanoma is defined as a rare and highly aggressive tumour, often carrying a poor prognosis because of local invasion and early distant metastasis.

Sinonasal mucosal melanoma needs to be considered in the differential diagnosis of sinonasal malignancies.

In our case report, a one-time reconstruction treatment and endoscopic approach are described.

One-time reconstruction shortened patient's hospitalization, improved patient's quality of life, if not survival, and allowed him to benefit immunotherapeutic treatment as soon as possible after tumour's surgical resection

Sinonasal mucosal melanoma extended to nose bridge: a one-time reconstruction treatment report

Abstract:

Sinonasal mucosal melanoma is a rare and highly aggressive tumour. This tumour often carries a poor prognosis because of local invasion and early distant metastasis. It's, in fact, an aggressive, fortunately rare, disease. It's more common among population in their seventies, with a prolonged course due to innocuous symptoms. We report a case of sinonasal mucosal melanoma in a 56-years old male who presented with a brownish sinonasal mass involving right nasal fossa, swelling and spontaneous epistaxis. We report this case for the one-time reconstruction treatment performed by our team.

Introduction:

Sinonasal mucosal melanoma are rare tumours that need to be considered in the differential diagnosis of sinonasal malignancies, like carcinoma, lymphoma, sarcoma and olfactory neuroblastoma. Incidence is 0.2–1 per million^[1,2] with a poor prognosis of 5-years overall survival rate, ranging between 20-43%^[3,4] that can be attributed to various factors: delayed diagnosis due to asymptomatic early stages; non-specific presenting complaint; lack of overt visibility; later stage presentation with locally advanced disease; aggressive nature of the disease, showed by local recurrence, cervical lymphadenopathy and distant metastases, making it difficult to identify the best treatment; proximity to vital neurovascular structures, which makes radical surgery rarely feasible due to close relation with important vascular and nervous structures^[5-7]. All these factors make surgical management of sinonasal cancer challenging, without considering the multiple histopathological types of tumours found, and above all, late diagnosis^[8,9]. This tumour is poorly radiosensitive, and surgical resection is preferred for localized disease. Advanced age, tumour size, nodal status, and distant metastasis status, have been identified as independent predictors of poorer survival.

Case report:

A 56-years old male presented on August 2016 to our Department of Maxillofacial Surgery for evaluation of a 3x2 cm nasal swelling without erythema, nasal obstruction and epistaxis since June 2016. The patient didn't lament cranial nerves dysfunction. CT scan showed a 55x15mm neof ormation in the right nasal fossa, extending to the tail of the medium inferior turbinate, to the nose bridge skin and to some right ethmoidal cells. Biopsy resulted in a right nasal fossa melanoma. Tumour was then staged as T4a for the ethmoidonasal localization, maxillary sinus mucosal invasion, and nose bridge skin involvement. The patient, after a surgical plan agreed between Maxillofacial, Neurosurgical, Pathologic, Oncologic and Radiotherapeutic teams, was then surgically treated with a one-time reconstruction consisting in a frontal rotation flap over right supraorbital artery. After performing an endoscopically assisted removal of the mass and bilateral Draf 3-ethmoidectomy, a right medial maxillectomy, the removal of the septum, a whole-thickness 4x4 removal of the external skin of the nasal pyramid and a peripheral frozen section exam, reconstruction by frontal flap was performed. The Neurosurgical team contributed to the treatment,

performing the reconstruction of the anterior cranial base with dural membrane and double-layer fibrin glue.

Intraoperative frozen section analysis performed by the Pathologists resulted in an invasive melanoma with mitotic index $>1\text{mm}^2$ (hotspot to 6 mitosis/ mm^2), tumoral necrosis and osteochondrilaginous tissue involvement, involving perichondrium of right nasal pyramid, with focal infiltration of bone tissue of nasal dorsum.

The Oncology consultant prescribed esophagogastroduodenoscopy, colonoscopy and total-body PET, that showed multiple lymphadenopathies in the celiac area, at the hepatic hilum and in the mesenteric fat tissue without pathological captation of the tracer. The patient was finally discharged after a 25-days hospitalization, after the endoscopic treatment of a left liquoral fistula, with Neurosurgical team's contribution, and negative esophagogastroduodenoscopy and colonoscopy, prescribed by the Oncologist. PET-CT scan showed no pathological captation of the tracer. Our patient is currently being treated with Ipilimumab 3mg/kg every 3 weeks.

Discussion:

In literature^[4], sinonasal melanoma is mostly T3 e T4, and in our case we defined it a T4a for cartilage, bone and overlying skin involvement. As no lymph nodes were involved, and no metastases were found, we defined it a T4A N0 M0 (Stage IV A).

A general consensus has been reached to consider surgery as a first-line treatment^[6,18,19] and, as might be expected, it is demonstrated that patients who did not have surgery had a poorer outcome^[10]. The tumour must be widely resected with 1,5-2 cm negative surgical margins (≥ 5 mm on definitive histological examination of the operative specimen). Failure to achieve local control is associated with an increased risk of distant disease and leads to significantly decreased overall survival. However, more than 50% of patients will develop distant metastases despite having good local tumour control^[11].

In our experience, endoscopic approach was preferred for melanoma's localization, our team's experience and the collaboration with the Neurosurgery team. The one-time reconstruction was added to grant a shorter hospitalization, and a quicker discharge of the patient to allow him to start his immunotherapeutic treatment, and to improve patient's quality of life, if not survival, by reconstructing as soon as possible his aesthetic features. Our patient isn't undergoing radiotherapy as external beam radiotherapy has a questionable survival benefit^[12] as patients tend to do poorly regardless of adjuvant radiation status. Given the added morbidity of radiation to the nasal cavity and the skull base and the lack of data supporting a survival benefit, patients may best be served by undergoing aggressive surgical resection and close monitoring or palliative resection, in cases where negative margins cannot be reached.^[13] Endoscopic procedure's major postoperative complications include cerebrospinal fluid leak. Minor complications include fever. As previously described, we observed liquoral fistula complication in our case. Overall, complications were observed in 10.3% of the patients in Lombardi's et al. work^[14]

Elective neck dissection (END) is not usually performed in Patients with sinonasal disease, although the incidence of nodal disease is higher in patients with oral cavity mucosal melanoma^[6, 15]. The majority of studies have recommended a conservative approach to neck management is needed but some have suggested routine conservative END, often to include levels I-V.^[15]

The role of chemotherapy in the management of mucosal melanoma is considered to be limited.

Under most circumstances, it is considered to be palliative at best. There is some evidence to suggest prolonged survival with the addition of chemotherapy. Therapy may include dacarbazine, platinum analogues, nitrosureas, and microtubular toxins.^[16] Our patient is currently being treated with Ipilimumab 3mg/kg every 3 weeks. Although monoclonal antibodies targeting immune checkpoint proteins (include Ipilimumab and PD-1/PD-L1 antibodies) have elicited long-lasting anti-cancer response in metastatic melanoma, randomized clinical trials on checkpoint inhibitors in

patients with metastatic MM are limited. It is expected that the role of checkpoint inhibitors in patients with metastatic MM will be further clarified after results of more prospective studies are ultimately available in future. In case of metastazation considered inoperable targeted therapies and immunotherapies with checkpoint inhibitors can be considered. PD-1 inhibitors or their combination with ipilimumab appear to show the highest response rates and longest progression-free survival. In case of a KIT mutation, additional analysis of NRAS is recommended before treating with a KIT-inhibitor. In the rare event of a BRAF V600 mutation, targeted therapy analogous to cutaneous melanomas is recommended. ^[20]

Conclusion:

Sinonasal melanoma is an aggressive disease, best treated with primary tumour resection. In our experience, treating our patient with a one-time reconstruction, given the extent of the tumour resected, shortened his hospitalization, allowing him to benefit the immunotherapeutic treatment as soon as possible after tumour's surgical resection, that is considered as a first-line treatment. One-time reconstruction improved, by reconstructing his aesthetic features, patient's quality of life, if not survival.

Conflict of interest:

The authors declare that they have no competing interest.

References:

- [1] Marcus DM, et al. Rising incidence of mucosal melanoma of the head and neck in the United States. *J Skin Cancer* 2012;2012:231693.
- [2] Jangard M, Hansson J, Ragnarsson-Olding B. Primary sinonasal malignant melanoma: a nationwide study of the Swedish population, 1960–2000. *Rhinology* 2013;51(1):22–30.
- [3] Tas, F. Keskin S: Mucosal melanoma in the head and neck region: different clinical features and same outcome to cutaneous melanoma. *ISRN Dermatol* 2013, 2013;5. Article ID:586915
- [4] Koivunen P, Back L, Pukkila M, Laranne J, Kinnunen I, Grenman R, Maikitie AA: Accuracy of current TNM classification in predicting survival in patients with sinonasal mucosal melanoma. *Laryngoscope* 2012, 122: 1734-1738
- [5] Seetharamu N, Ott PA, Pavlick AC. Mucosal melanomas: a case-based review of the literature. *Oncologist*. 2010;15:772–781.
- [6] Chan RC, Chan JY, Wei WI. Mucosal melanoma of the head and neck: 32-year experience in a tertiary referral hospital. *Laryngoscope*. 2012;122:2749–2753. *Oncol* 2008; 31: 43-8
- [7] Khan MN, Kanumuri VV, Raikundalia MD, et al. Sinonasal melanoma: survival and prognostic implications based on site of involvement. *Int Forum Allergy Rhinol*. 2014;4:151–155.
- [8] Maghami E, Kraus DH. Cancer of the nasal cavity and paranasal sinuses, *Expert Rev Anticancer Ther* 2004; 4: 411-424

- [9] Dulguerov P, Jacobsen M, Allal A, Lehmann W, Calcaterra T, Nasal and paranasal sinus carcinoma: are we making progress? A series of 220 patients and systematic review. *Cancer* 2001; 92: 3012-3029
- [10] Jethanamest D, Vila PM, Sikora AG, Morris LG. Predictors of survival in mucosal melanoma of the head and neck. *Ann Surg Oncol* 2011; 18: 2748–56.
- [11] Manolidis S, Donald PJ. Malignant mucosal melanoma of the head and neck: review of the literature and report of 14 patients. *Cancer* 1997; 80: 1373–86.
- [12] Samstein RM, Carvajal RD, Postow MA, et al. Localised sinonasal mucosal melanoma: outcomes and associations with stage, radiotherapy and positron emission tomography response. *Head Neck* 2016; 38: 1310–7.
- [13] Konuthula N, Khan MN, Parasher, A, et al. The Presentation and Outcomes of Mucosal Melanoma in 695 Patients. *Int Forum Allergy Rhinol* 2017;7:99–105.
- [14] Davide Lombardi et al. Sinonasal mucosal melanoma: A 12-year experience of 58 cases. *Head and neck* 2016, April 2016; 1737 – 1745.
- [15] Wu Y, Zhong Y, Li C, et al. Neck dissection for oral mucosal melanoma: caution of nodular lesion. *Oral Oncol* 2014; 50: 319–24.
- [16] Lengyel E, Glide K, Remenar E, Esik O. Malignant mucosal melanoma of the head and neck. *Path Oncol Res* 2003;9:7–12.
- [17] Krenegli M, Masini L, Kaanders JH, et al. Radiotherapy in the treatment of mucosal melanoma of the upper aerodigestive tract: analysis of 74 cases. A Rare Cancer Network study. *Int J Radiat Oncol Biol Phys.* 2006;65:751–759.
- [18] Patrick RJ, Fenske NA, Messina JL. Primary mucosal melanoma. *J Am Acad Dermatol* 2007; 56: 828-34
- [19] M. Wagner, C.G. Morris, J.W. Werning, et al. Mucosal melanoma of the head and neck *Am J Clin Oncol*, 31 (2008), pp. 43-48
- [20] Lian B, Guo J. Checkpoint inhibitors in treatment of metastatic mucosal melanoma. *Chin Clin Oncol.* 2014 Sep;3(3):37. doi: 10.3978/j.issn.2304-3865.2014.07.05.

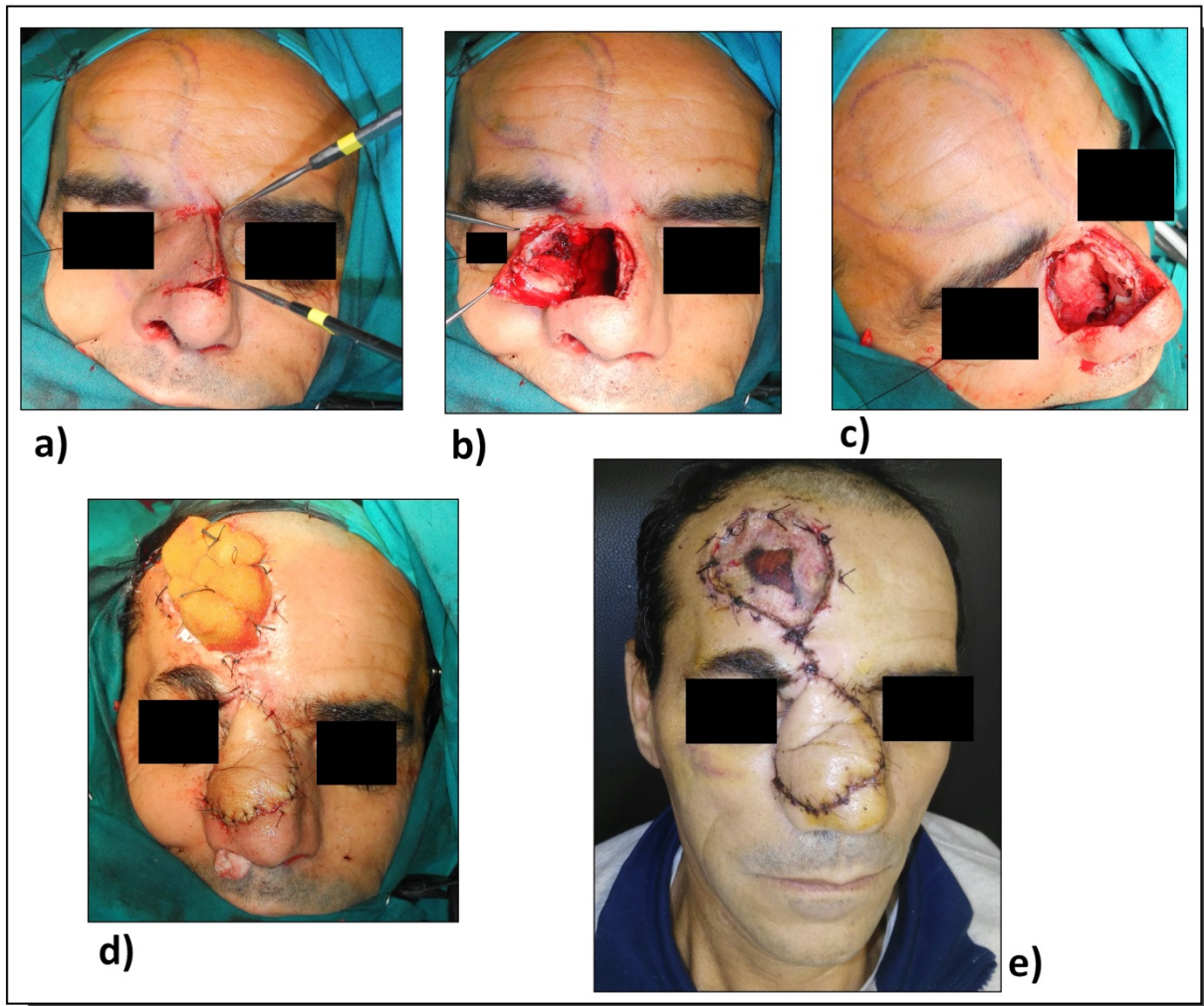


Figure 1 – A,b,c) Removal of the septum d) Frontal flap e) 1 month later

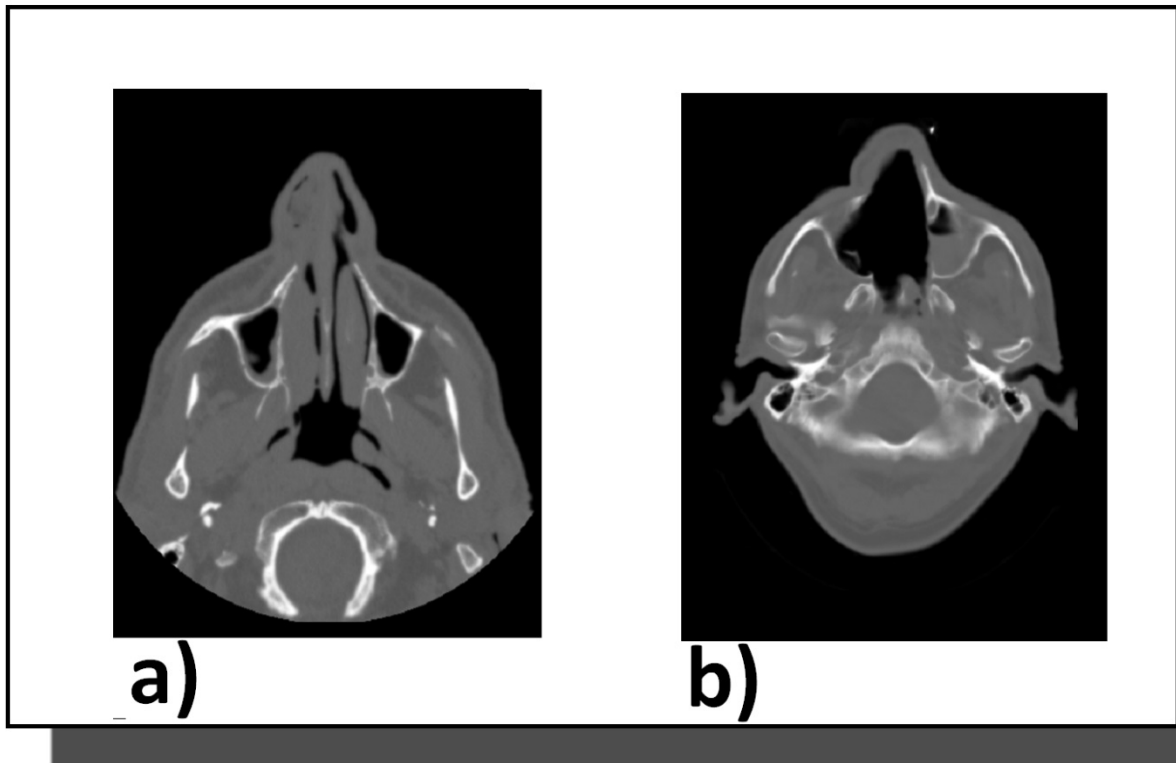


Figure 2 – CT scans before (a) and after surgery (b) Draf III procedure involves removal of the inferior portion of the interfrontal septum, the superior part of the nasal septum, and the frontal sinus floor to the orbit laterally. The lamina papyracea and posterior walls of the frontal sinus remain intact. Postoperatively, a wide opening into both frontal sinuses can be seen. The surgical defect in the superior nasal septum should not be mistaken for an unintended postoperative septal perforation.

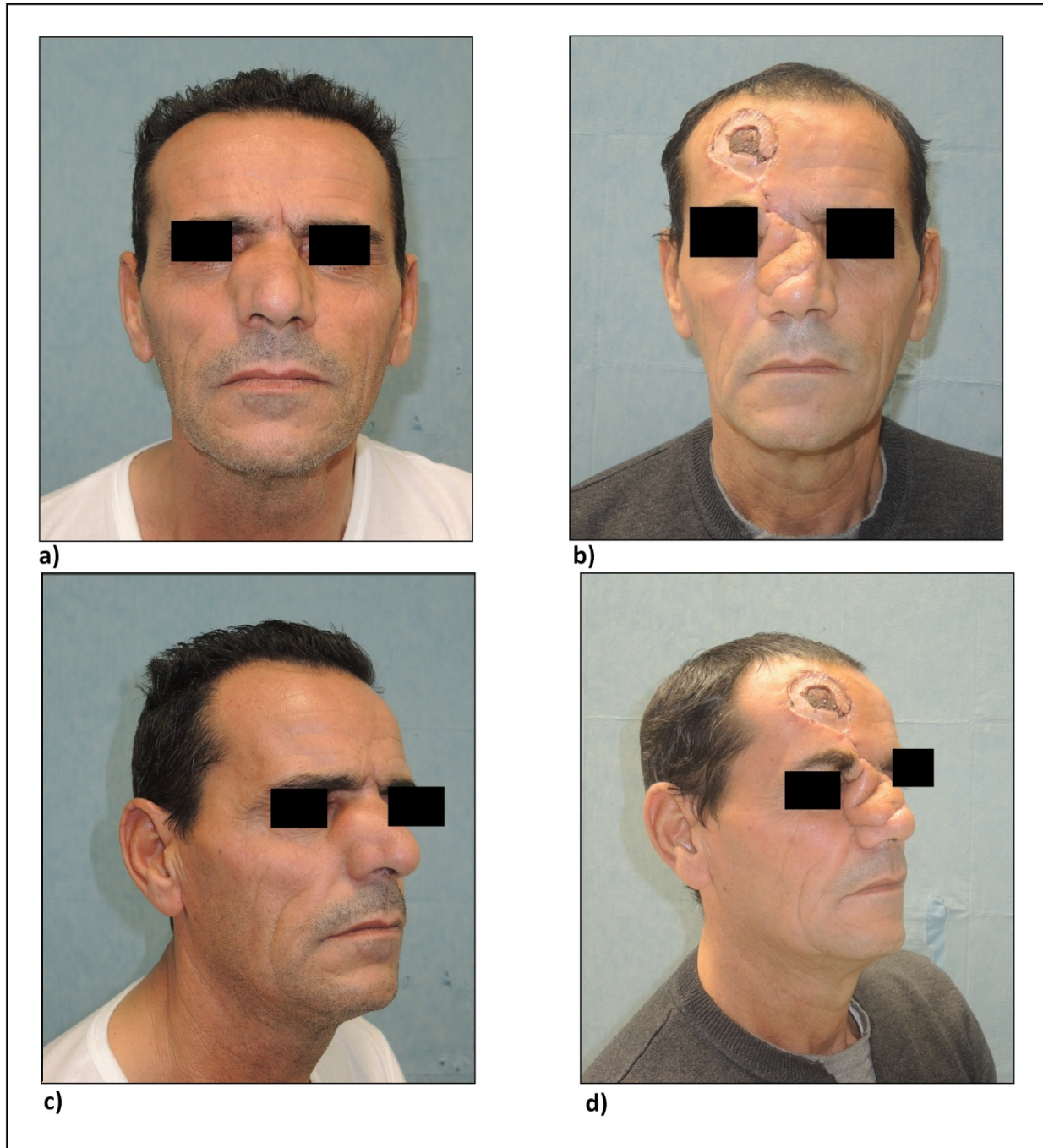

Figure 3 – Before (a,c) and after surgery (b,d)

Table 1.

American Joint Committee on cancer staging mucosal melanoma of the head and the neck, 7th edition.

Primary tumour (T)

TX	Primary tumour cannot be assessed
T3	Mucosal disease
T4a	Moderately advanced disease : tumour involving deep soft tissue, cartilage, bone, or overlying skin
T4b	Very advanced disease : tumour involving brain, dura, skull base, lower cranial nerves (IX, X, XI, XII), masticator space, carotid artery, prevertebral space, or mediastinal structures

Regional lymph nodes (N)

NX	Regional lymph nodes cannot be assessed
N0	No regional lymph node metastases
N1	Regional lymph node metastases present

Distant metastasis (M)

M0	No distant metastasis
M1	Distant metastasis present

Staging

Stage III	T3, N0, M0
Stage IV A	T4a, N0, M0
Stage IV B	T3-T4a, N1, M0
Stage IV C	T4b, any N, M0
Stage IV D	Any T, any N, M1