



Tumor model for surgical simulation to assess a minimally invasive endoscopic approach for midcheek mass removal



Giovanni Dell' Aversana Orabona ^a, Antonio Romano ^a, Paola Bonavolontà ^{a,*},
Vincenzo Abbate ^a, Alfonso Manfuso ^a, Giorgio Iaconetta ^b, Bernhard Hirt ^c, Luigi Califano ^a

^a Department of Maxillofacial Surgery, University of Naples "Federico II", Naples, Italy

^b Department of Neurosurgery, University of Salerno, Salerno, Italy

^c Department of Head and Neck Surgery, University of Tübingen Medical Center, Tübingen, Germany

ARTICLE INFO

Article history:

Received 21 February 2017

Received in revised form

10 May 2017

Accepted 24 May 2017

Keywords:

Surgical training

Midcheek mass

Minimally invasive endoscopic approach

ABSTRACT

Introduction: The midcheek is considered one of the most important facial area due to its involvement in mimic expression and communication. Pathology of this district is complex due to the variety of soft tissue belonging to the face. We propose a surgical simulation, to assess the feasibility of a new minimally invasive endoscopic approach for midcheek mass removal.

Technical report: This study was performed on four cadavers, at the Anatomy Laboratory of the University of Tübingen. In all the cadavers 3 cm³ of Acquasil Dent Sply Ultra were injected via trans-cutaneous along the nasolabial fold to simulate a midcheek mass. Three incisions in concealed areas were performed to create an access to reach the anterior compartment of the face. By using the Optical Dissector with distal spatula and a 30° endoscope we provided a wide surgical window and a greater exposure to isolate, dissect and remove the midcheek tumor model safely.

Conclusion: The proposed endoscopic technique allowed us to visualize and preserve all the key anatomic structures of the midcheek region. Due to its nature, the suggested material may provide a valid tumor model for surgical training also in other districts.

© 2017 Elsevier Ltd. All rights reserved.

1. Introduction

The midcheek is considered one of the most important facial area due to its involvement in mimic expression and communication [1].

This area has a trapezoidal shape, comprehended between the lower eyelid above and the upper lip below; limited laterally by a line extending from the lateral canthus of the orbit to the labial commissure, medially by a line extending from the internal canthus to nasolabial fold. In this small area there are many important structures such as the Zygomatic nerve, the Buccal nerve, the Accessory parotid Gland, the Stensen's duct (Fig. 1).

Pathology of this district is complex due to the variety of soft tissue belonging to the face, including skin, lymphatic, adnexal, neurogenic, and salivary structures [2]. The lesions arising from the midcheek area are rare and usually arise from the accessory parotid

gland [3].

For all these reasons is very important to choose the best surgical approach to remove the soft tissue masses avoiding major complications, such as hemorrhages, facial paralysis, laceration of Stensen's duct and unaesthetic scars.

In literature different approaches to remove midcheek masses are proposed. Most common approaches are: the intraoral, external (Blair's incision or Face-lift incision), direct skin incision [4,5]. Nevertheless none of them can be considered reliable for the complete excision of tumor from midcheek with a very low morbidity, acceptable scare and preservation of the key anatomical structures. Thus the best surgical approach to this area should consider both: clinical outcome and aesthetic; the endoscopic surgery could be a good alternative to the standard procedures. A recent paper described the endoscopic anatomy of the midcheek region emphasizing the role of the facial retaining ligaments (FRL) and in particular of the transverse facial artery (TFA) to guide the endoscopic dissection to this district safely [6]. Basing to this study we propose a surgical simulation on cadaver, to assess the feasibility of a new minimally invasive endoscopic approach for

* Corresponding author. Department of Maxillofacial surgery, University of Naples "Federico II", Via Pansini 5, 80131, Naples, Italy.

E-mail address: p.bonav@gmail.com (P. Bonavolontà).

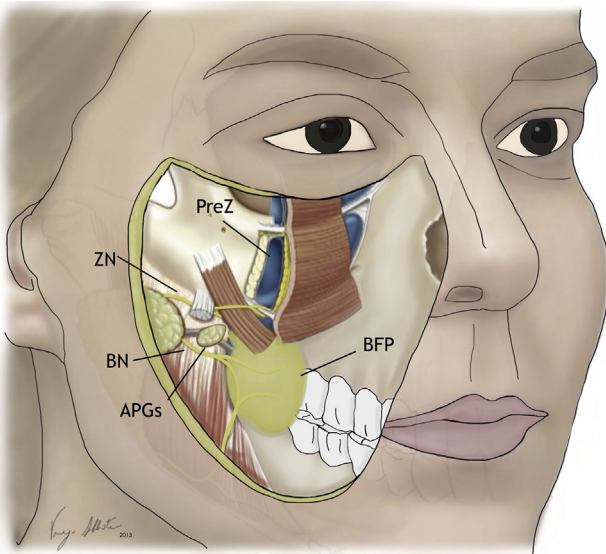


Fig. 1. Midcheek area: PreZ, prezygomatic space; ZN, zygomatic nerve; BN, buccal nerve; APGs, accessory parotid glands; BFP, buccal fat pad.

midcheek mass removal, using a tumor training model.

2. Technical report

This study was performed on four cadavers, prepared with intravascular injection of colored silicone, at the Anatomy Laboratory of the University of Tübingen Medical Center, once approval of the local ethical institutional board was obtained. Eight procedures were performed; the dissection was bilateral on each cadaver's side. There were 3 male and 1 female, the age ranged between 64 and 76 years old, with mean age, 71. The only inclusion criteria was the age of death, nobody over 80 years old, due to the age related changes occurring in the midcheek area.

2.1. Preoperative preparations

The head position was placed in lateral rotation. The first procedure was the design of the different areas (Fig. 2).

Before the dissection, in all the cadavers on each side of the face 3 cubic centimeters of Acquasil Dent Sply Ultra LV (Light Viscosity) (Milford, DE)[®] were injected via trans-cutaneous along the nasolabial fold.

All the procedures have been performed with the aid of 4 mm diameter, 18 cm length rigid, rod lens endoscopes with a 30° vision, angulation coupled to a high definition camera and monitors (Karl Storz, Tuttlingen Germany). Optical dissector (50200 ES), with distal spatula, fenestrated, large, sharp, to be used with HOPKINS II telescope; RHINOFORCE II nasal scissors (449201), and BLAKESLAY nasal Forceps (456000) were adopted to perform all the procedures (Karl Storz). All dissections were documented by high definition camera and AIDA recording system (Karl Storz).

2.2. Surgical dissection procedure

For each side, the head was placed in lateral rotation. Three incisions in concealed area were required: the first with a length of 1.5 to 2 cm at the margin of the tragus, the second incision was performed along the postauricular crease, and the third incision was made on the temporal scalp above the hairline.

Incisions were made across tissues to the upper face of the

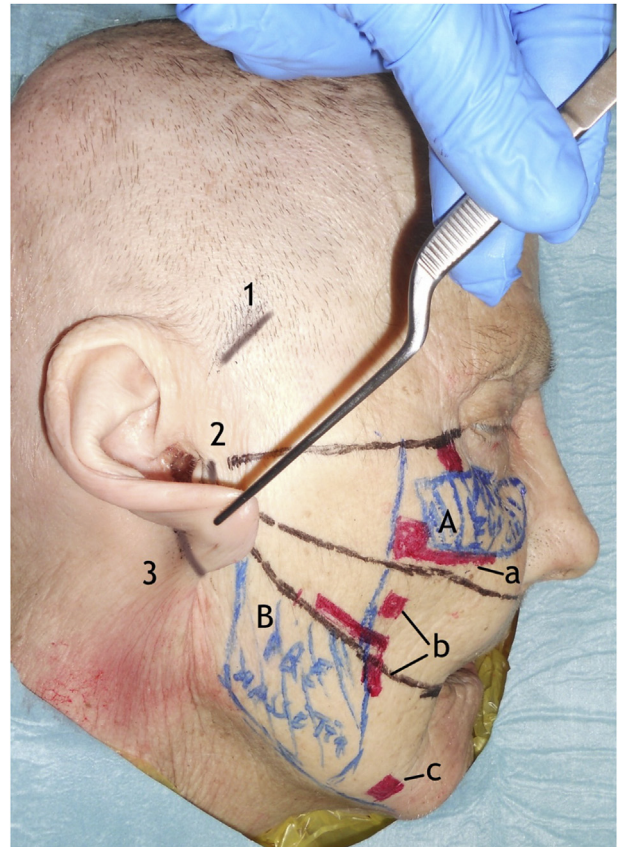


Fig. 2. 1-2-3 = Skin incisions. A = Prezygomatic space and B = premasseteric space cutaneous projection; a = zygomatic; b = upper masseteric; and c = mandibular retaining ligament's cutaneous projection.

superficial musculoaponeurotic system (SMAS) and its continuation, the superficial temporal fascia, in the temporal region, preserving the latter.

This small initial dissection allowed the insertion of the optical dissector with the distal spatula. Under 30° endoscopic view, through the tragal incision, the first structure encountered were the parotid cutaneous ligaments. These ligaments appeared lax and easily undergo a blunt dissection by endoscopic scissors.

An about 3.5–4 cm from the tragal access the superior branch of the transverse facial artery (TFA) was highlighted along a line led from the tragus to the ala nasi.

This artery comes out of the parenchyma and through the endoscopic field of the view, vertically.

Smooth dissection led cranially to this anatomic landmark, letting the operators visualize the zygomatic retaining ligaments and the zygomatic branch of the facial nerve.

Keeping the transverse facial artery as the fundamental endoscopic landmark, under endoscopic view, we were able to visualize and preserve: the zygomatic retaining ligaments (FRL) and the zygomatic branch of the facial nerve. After the initial dissection we reached the prezygomatic space. We continued with a smooth dissection through the premasseter space, and the masseter muscle was easily visualized. In this space there were key anatomic structures: the parotid duct, the Accessory parotid glands (inconstant), the upper masseteric ligaments and the upper buccal trunk of the facial nerve (Fig. 3). The midcheek tumor model appeared as a colored mass causing displacement of surrounding neural and vascular structures. Due to its nonadhesive nature, the model afforded us a dissection plane very similar to a real tumor. We were

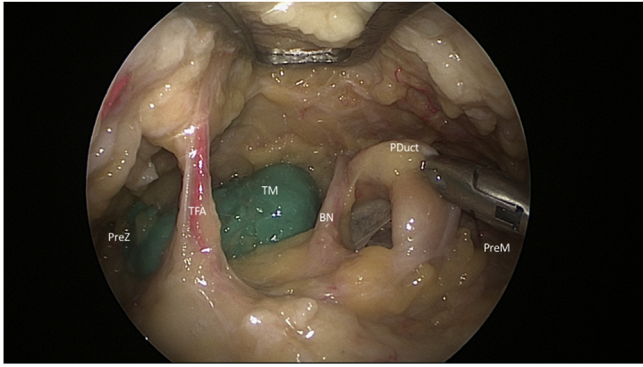


Fig. 3. Key anatomic structures of the midcheek area: P Duct Parotid duct; TFA Transverse Facial artery; BN Buccal trunk of facial nerve; Pre Z Prezygomatic space; Pre M premasseteric space; Tumor model TM.

able to isolate, dissect and remove the midcheek tumor model in safety trough the tragal incision (Fig. 2. Incision n°2) (Video).

Supplementary video related to this article can be found at <http://dx.doi.org/10.1016/j.suronc.2017.05.005>.

3. Results

By using the Optical Dissector with a 30° endoscope we provided a wide surgical window and a greater exposure. We were able to identify and preserve the key anatomic structures of the midcheek area: the superior branch of the TFA; the zygomatic retaining ligament; the zygomatic branch of facial nerve; the Stensen's duct; the upper masseteric ligaments and the upper buccal trunk of the facial nerve; the prezygomatic and premasseter spaces, and the buccal fat pad (Fig. 1).

In all the cadavers the midcheek tumor model was easily identified, dissected and removed.

4. Discussion

The lesions arising from the midcheek area are uncommon, few cases are reported in literature [4,5,7,8]. Beyond aesthetics, the midcheek area contains key anatomic structures that may be interested by benign or malignant neoplasms. Incidentally, lesions occurring in this district are infrequent and often benign [4,5].

The Accessory Parotid Gland is the most common site of origin of the tumors in the midcheek area and account 1–8% of all parotid lesions [4,5,7].

Clinically they appear as progressive enlarging and painless mass. Diagnosis is made by CT scan or MRI and is confirmed by FNAC biopsy. Differential diagnosis must exclude: vascular malformations (VMs), benign or malignant lymphadenopathy, masseter muscle hypertrophy, lipomas, neurofibromas, schwannoma, neurilemmomas, fibromas, malignant tumor arising from the muscles or buccal fat pad, sialoceles and sialolithiasis [3,8].

The gold standard treatment for removal of midcheek mass is represented by open surgery, followed by intraoral approach [2–5]. This approaches are not free from complications: high incidence of vascular and nerve injury, Stensen's duct lesion and unaesthetic scar were usually reported. The superficial parotidectomy with a Blair's incision or a Face lift are the most used incisions [4]. The intra-oral approach is an alternative procedure described in literature [5] but is not recommended because it provides inadequate

Table 1
Minimally invasive endoscopic approach to midcheek mass: Pros and cons.

Pros	Cons
Best aesthetic result	Long learning curve
Magnification of the key anatomical structures	Not indicated in malignant neoplasms
Invisible scars	Long operative times
Careful bimanual dissection	Bleeding control

exposure for bleeding control and high risk of facial nerve injury. Because of the particular features of the district, the best surgical management should consider both, aesthetic and clinical outcomes.

The endoscopic procedure can be considered a good approach to conciliate both needs. This approach could be very helpful for the removal of small benign neoplasms arising from midcheek region such as VMs, lipomas or pleomorphic adenoma area [9–11] (Table 1).

Xie et al. [12], 2012 first described the results of minimally invasive endoscopic approach for resection of a benign tumor in the accessory parotid gland. Later, Li et al. [13], 2013 evaluated the feasibility of a modified endoscopic approach with minimal, and concealed, incisions for the resection of benign tumors in the accessory parotid gland.

Despite the originality of the endoscopic approaches proposed none of them has provided an optimal technical description.

Thus We propose a cadaveric tested study to assess a new minimally invasive endoscopic approach to midcheek.

Inspired by an idea of Gragnaniello et al. [14,15] we describe for the first time in the literature, the use of silicon injection, (Acquasil Dent Sply Ultra Light Viscosity)[®] to simulate a lesion in the midcheek area. Various materials have been tested to find the most similar to real tumor.

Aquasil Ultra LV is a quadrafunctional hydrophilic addition reaction silicon, light body, with excellent hydrophilic properties, dimensional accuracy, high tear strength and resistance to permanent deformation. This silicon has an important characteristic; the similar consistency of the tumor, and it causes displacement of surrounding structures with non-adhesive nature. This leaves the surgical corridor undisturbed for performing the dissection.

This silicon presents a unique viscoelastic characteristics: liquid, initially and than it expands when injected, forming a solid tumor like structure, which allowed us to easily identify the tumor under endoscopic guidance, and remove easily, preserving the noble structures.

5. Conclusion

In comparison to established techniques the major difference of the proposed procedures is the small incision accompanied with a great surgical windows that allowed the surgeon to see and preserve the key anatomic structures. The surgical protocol presented comprises three advantages: minimal skin incision compared with the open surgery. Through the use of the endoscope it was possible to see the noble structures and so not to damage them during the removal of the tumor.

With the help of the transcutaneous injection of silicone, we were able to simulate a tumor mass in the midcheek compartment and its removal through endoscopy. Finally, thanks to this protocol it's possible to train young surgeons during the anatomic dissections and, give the opportunity to become familiar with the

endoscopic technique for the removal of midcheek mass.

Further clinical applications are required in order to assess advantages and/or limitations of this procedure.

Conflict of interest

Authors introduced the injection of Acquasil Dent Sply Ultra LV (Light Viscosity) (Milford, DE)[®] for the surgical simulation. Despite this, the authors declare no conflict of interest.

References

- [1] B.C. Mendelson, S.R. Jacobson, Surgical anatomy of the midcheek: facial layers, spaces, and the midcheek segments, *Clin. Plast. Surg.* 35 (2008) 395–404.
- [2] D.A. Klotz, J.U. Coniglio, Prudent management of the mid-cheek mass: revisiting the accessory parotid gland tumor, *Laryngoscope* 110 (2000) 1627–1632.
- [3] G. Dell' Aversana Orabona, V. Abbate, P. Piombino, G. Iaconetta, L. Califano, Midcheek mass: 10 year of clinical experience, *J. Craniomaxillofac Surg.* 42 (2014) 353–358.
- [4] G. De Riu, S.M. Meloni, O. Massarelli, A. Tullio, Management of midcheek masses and tumors of the accessory parotid gland, *Oral Surg. Oral Med. Oral Pathol. Oral Radiol. Endod.* 111 (2011) 5–11.
- [5] J.1 Schmutzhard, I.M. Schwentner, J. Andrlé, A.R. Gunkel, G.M. Sprinzl, Resection of accessory parotid gland tumors through a peroral approach with facial nerve monitoring, *J. Craniofac Surg.* 18 (2007) 1419–1421.
- [6] V. Abbate, A. Romano, A. AlQahtani, A. Manfuso, B. Hirt, P. Castelnuovo, L. Califano, Midcheek endoscopic anatomy, *Head. Neck* 38 (2016) 268–273.
- [7] A. Lewkowicz, Y. Levy, R. Zeltser, A. Zagury, O. Nahlieli, Accessory parotid gland masses, *Oral Surg. Oral Med. Oral Pathol. Oral Radiol. Endod.* 89 (2000) 610–612.
- [8] I. Luksić, M. Virag, S. Manojlović, D. Macan, Salivary gland tumours: 25 years of experience from a single institution in Croatia, *J. Craniomaxillofac Surg.* 40 (2012) 75–81.
- [9] P. Cappabianca, L.M. Cavallo, F. Esposito, O. De Divitiis, A. Messina, E. De Divitiis, Extended endoscopic endonasal approach to the midline skull base: the evolving role of transsphenoidal surgery, *Adv. Tech. Stand Neurosurg.* 33 (2008) 151–199.
- [10] D. Solari, C. Chiaramonte, A. Di Somma, G. Dell'Aversana Orabona, M. de Notaris, F.F. Angileri, L.M. Cavallo, S. Montagnani, M. Tschabitscher, P. Cappabianca, Endoscopic anatomy of the skull base explored through the nose, *World Neurosurg.* 82 (6 Suppl) (2014) S164–S170, <http://dx.doi.org/10.1016/j.wneu.2014.08.005>. PubMed PMID: 25496629.
- [11] L.M. Cavallo, A. Di Somma, M. de Notaris, A. Prats-Galino, S. Aydin, G. Catapano, D. Solari, O. de Divitiis, T. Somma, P. Cappabianca, Extended endoscopic endonasal approach to the third ventricle: multimodal anatomical study with surgical implications, *World Neurosurg.* 84 (2) (2015 Aug) 267–278.
- [12] L. Xie, D. Zhang, M.M. Lu, B.M. Gao, Minimally invasive endoscopic- assisted resection of benign tumors in the accessory parotid gland: 5 case studies, *Head. Neck* 34 (2012) 1194–1197.
- [13] B. Li, L. Zhang, Z. Zhao, G. Shen, X. Wang, Minimally invasive endoscopic resection of benign tumours of the accessory parotid gland: an updated approach, *Br. J. Oral Maxillofac. Surg.* 51 (2013) 342–346.
- [14] C. Gagnaniello, R. Nader, T. van Doormaal, M. Kamel, E.H. Voormolen, G. Lasio, E. Aboud, L. Regli, C.A. Tulleken, O. Al-Mefty, Skull base tumor model, *J. Neurosurg.* 113 (2010) 1106–1111.
- [15] C. Gagnaniello, F. Gagliardi, A.M. Chau, R. Nader, A. Siu, Z. Litvack, B.D. Luca, K. Seex, P. Mortini, A.J. Caputy, O. Al-Mefty, Intracranial injectable tumor model: technical advancements, *J. Neurol. Surg. B Skull Base* 75 (2014) 301–308.