



Clinical heterogeneity of dominant chronic mucocutaneous candidiasis disease: presenting as treatment-resistant candidiasis and chronic lung disease



Laura Dotta ^{a,*}, Omar Scomodoni ^{a,1}, Rita Padoan ^b, Silvia Timpano ^b, Alessandro Plebani ^a, Annarosa Soresina ^a, Vassilios Lougaris ^a, Daniela Concolino ^c, Angela Nicoletti ^c, Giuliana Giardino ^d, Amelia Licari ^e, Gianluigi Marseglia ^e, Claudio Pignata ^d, Nicola Tamassia ^f, Fabio Facchetti ^g, Donatella Vairo ^h, Raffaele Badolato ^a

^a Department of Clinical and Experimental Sciences, Institute of Molecular Medicine "Angelo Nocivelli", University of Brescia, Brescia, Italy

^b Unit of Paediatric Pneumology, Spedali Civili of Brescia, Brescia, Italy

^c Department of Paediatrics, University of Catanzaro, Catanzaro, Italy

^d Department of Translational Medical Sciences, Federico II University, Naples, Italy

^e Department of Paediatrics, Foundation IRCCS Policlinico San Matteo, University of Pavia, Pavia, Italy

^f Department of Medicine, General Pathology Unit, University of Verona, Verona, Italy

^g Department of Molecular and Translational Medicine, Pathology Unit, University of Brescia, Brescia, Italy

^h Department of Molecular and Translational Medicine, University of Brescia, Brescia, Italy

ARTICLE INFO

Article history:

Received 7 September 2015

Received in revised form 14 December 2015

accepted with revision 23 December 2015

Available online 28 December 2015

Keywords:

Gain of function STAT1

Chronic mucocutaneous candidiasis

Chronic lung disease

Bronchiectasis

Autoimmunity

Lymphopenia

ABSTRACT

In gain-of-function *STAT1* mutations, chronic mucocutaneous candidiasis disease (CMCD) represents the phenotypic manifestation of a complex immunodeficiency characterized by clinical and immunological heterogeneity. We aimed to study clinical manifestations, long-term complications, molecular basis, and immune profile of patients with dominant CMCD. We identified nine patients with heterozygous mutations in *STAT1*, including novel amino acid substitutions (L283M, L351F, L400V). High risk of azole-resistance was observed, particularly when intermittent regimens of antifungal treatment or use of suboptimal dosage occurs. We report a case of Cryptococcosis and various bacterial and viral infections. Risk of developing bronchiectasis in early childhood or gradually evolving to chronic lung disease in adolescent or adult ages emerges. Lymphopenia is variable, likely progressing by adulthood. We conclude that continuous antifungal prophylaxis associated to drug monitoring might prevent resistance to treatment; prompt diagnosis and therapy of lung disease might control long-term progression; careful monitoring of lymphopenia-related infections might improve prognosis.

© 2016 Elsevier Inc. All rights reserved.

Abbreviations: GOF, Gain-of-function; STAT1, Signal transducer and activator of transcription 1; CMCD, Chronic mucocutaneous candidiasis disease; CCD, Coiled-coiled domain; DBD, DNA-binding domain; LOF, Loss-of-function; AR, Autosomal recessive; AD, Autosomal dominant; CMC, Chronic mucocutaneous candidiasis; IPEX, Immune dysregulation, polyendocrinopathy, enteropathy, X-linked; WES, Whole exome sequencing; IFN, Interferon; pSTAT1, phosphorylated signal transducer and activator of transcription 1; ISRE(s), Interferon-stimulated response element(s); AIRE, Autoimmune regulator; PBMCs, Peripheral blood mononuclear Cells; EBV, Epstein-Barr virus; GAS, γ -Activated Sequence; MIC, Minimal inhibitory concentration; TSH, Thyroid-stimulating hormone; SLE, Systemic lupus erythematosus; TRECS, T-cell receptor excision circles; CT, Computed-tomography; PEP, Positive expiratory pressure; FEV1, Forced expiratory volume in 1 s; FEF 25–75%, Interval 25–75% of the forced vital capacity; G-CSF, Granulocyte-colony stimulating factor; GM-CSF, Granulocyte monocyte-colony stimulating factor; HSCT, Hematopoietic stem cell transplantation; MFI, Mean intensity fluorescence; HD, Healthy donor.

* Corresponding author at: Istituto di Medicina Molecolare "Angelo Nocivelli", Clinica Pediatrica c/o Spedali Civili, Università degli Studi di Brescia, P.le Spedali Civili, 1, 25123 Brescia, Italy.

E-mail address: lauradotta@icloud.com (L. Dotta).

¹ DL and SO contributed equally to the study.

1. Introduction

In 2011, autosomal dominant gain-of-function (GOF) mutations in signal transducer and activator of transcription 1 (*STAT1*) gene have been identified as a cause of chronic mucocutaneous candidiasis disease (CMCD) [1,2]. To date, more than 100 patients have been reported, with 37 different mutations affecting the coiled-coiled (CCD) or the DNA-binding (DBD) domains of *STAT1*. This transcriptional activator plays a major role in various signaling pathways, particularly of IFNs, IL-27, IL-21, IL-6, and IL-17 immunity [3,4]. *STAT1* loss-of-function (LOF) mutations were already known to account for rare autosomal recessive (AR) immunodeficiencies [5], resulting respectively in fatal mycobacterial and viral diseases (when complete gene deficiency occurs [6]), or milder phenotypes (when deficiency is partial [7]). Autosomal dominant (AD) LOF mutations were identified as a cause of Mendelian susceptibility to mycobacteria infections [8]. GOF-*STAT1* mutations were firstly described among patients affected with severe

CMCD of the skin, nails, and mucous membranes, associated to autoimmune diseases; life-threatening conditions such as squamous-cell carcinoma, cerebral and, recently, aortic aneurysms [9] were also rarely reported. Disseminated fungal (coccidioidomycosis, histoplasmosis, mucormycosis) and viral (herpes virus family, a case report of orf virus) infections were also described [10–13]. Mutations of *STAT1* have been identified by next generation sequencing also in patients with IPEX (immune dysregulation, polyendocrinopathy, enteropathy, X-linked)-like features [14], and in patients with severe, fatal phenotypes resembling combined immunodeficiency [10,15]. Any evidence of any genotype-phenotype correlation is emerging, and data about long-term morbidity and prognosis may be controversial. Herein, we report nine patients diagnosed with previously reported and novel GOF-*STAT1* mutations, showing large heterogeneity for age distribution and phenotypes.

2. Material and methods

2.1. Patients

We report nine patients who were diagnosed as affected with CMCD and evaluated for genetic analysis and *in vitro* functional studies from their peripheral blood, according to approved protocols of Spedali Civili in Brescia, Italy. Cases are described in details in [16]. Written informed consent was obtained from all patients or their parents (for minors), and for healthy controls. Medical history and clinical data were retrospectively collected from medical records. In all patients extended immunological assessment was performed. For patients under the care of the Department of Brescia a pulmonary evaluation, including assessment of pulmonary function tests and imaging, was carried out.

2.2. Molecular genetic analysis

Whole exome sequencing (WES) was performed at Children's Mercy Hospital and Clinics, Kansas City, Centre for Pediatric Genomic Medicine (Professor Kingsmore Stephen F) for P1. *STAT1* mutation was subsequently confirmed by Sanger sequencing in both P1 and his mother P2. In patients P3–P9 Sanger sequencing was used to analyze *STAT1*. DNA was isolated from whole blood using QIAamp DNA Blood Mini Kit (Qiagen). *STAT1* gene was amplified by PCR and products were sequenced using BigDye Terminator Kit (Applied Biosystems). Sequences were analyzed with 310 Genetic Analyzer (Applied Biosystems). Sequence variants were identified relative to a reference sequence, GenBank accession no. ENST00000361099 for the *STAT1* cDNA, in which the c.1 position corresponds to the A of the ATG translation initiation codon. Mutations are designated as recommended by den Dunnen and Antonarakis [17].

2.3. Analysis of phosphorylated *STAT1* (p*STAT1*) by flow cytometry

Peripheral blood was left unstimulated and stimulated with IFN γ (1000 U/ml), or IFN α (40,000 U/ml), for 30 min. Cells were lysed, permeabilized, and stained, as indicated by the manufacturer (BD Phosflow). Specific phycoerythrin-labeled antibody for phosphorylated *STAT1* (p*STAT1*) (pY701; BD Biosciences) was used. p*STAT1* was evaluated in both lymphocyte and monocyte gates. Cells were acquired using FACSCalibur (BD Bioscience) and analyzed by FlowJo version 7.5 Software (TreeStar).

2.4. Cytoplasmic and nuclear extracts preparation, Western blot and EMSA

After stimulation with IFN γ or IFN β for 30 min, cells were lysed in cold buffer (150 mM NaCl, 50 mM Tris-HCl pH 7.4, 1% NP40, and protease inhibitors -Roche-containing 0.2 μ g of aprotinin, leupeptin and 1 mmol/L of sodium orthovanadate) on ice for 15 min. For Western blot analysis, cytoplasmic extracts were resolved on 8% polyacrylamide and subjected to immunoblots by standard procedures. Nitrocellulose membranes were first blocked for 1 h at room temperature in TBST

containing 5% BSA, and then incubated overnight at 4 °C with specific primary Abs (p*STAT1*, *STAT1*) in the same buffer. Antibodies against phospho-tyrosine *STAT1* were purchased from Cell Signaling Technologies (Denver, MA, USA). Antibodies against total *STAT1* (sc-346) were obtained from Santa Cruz, and antibodies against β -actin were obtained from Sigma-Aldrich. Detection was carried out using HRP-conjugated anti-mouse or anti-rabbit IgG (Amersham Biosciences), and revealed using ECL system (Amersham Biosciences). For EMSA, after stimulation with IFN γ and/or IFN β for 30 min, EBV transformed B cells (5×10^6 /condition) were diluted in ice-cold PBS and centrifuged twice at 300 X g for 5 min at 4 °C. Nuclear extracts were prepared using a modification of the method of Dignam *et al.* [18]. Transcription factor-binding analyses were performed as described previously [18]. Nuclear extracts were incubated in binding buffer in the presence of the labeled oligonucleotide *STAT*-binding probe from the GRR element located within the promoter of the Fc γ RI/CD64 gene (5-CTTTTCTGGGAAATACATCTCAAATCCTTGAAACATGCT-3) or from the interferon-stimulated response element (ISRE) (5-GATCGGGAAAGGGAAACCGAAACTGAA-3).

2.5. Mutagenesis assay

eGFP *STAT1* WT vector (Addgene) was used to obtain mutated *STAT1* form carrying L351F and L400V variants. Mutations were generated by site direct mutagenesis QuikChange Site-Directed Mutagenesis Kit (Agilent Technologies).

2.6. Luciferase reporter assay

U3C cells were seminanted into 96-well plates (1×10^4 /well) and transfected with 100 ng/well reporter plasmids and plasmids carrying alleles of *STAT1* (L351F and L400V) or a mock vector with Arrest-in (Thermo Scientific). After 6 h, cells were transferred into medium containing 10% FBS and cultured for 24h. Cells were stimulated with IFN γ at different concentration (10, 100, 1000 UI/ml), and IL-27 (100 ng/ml) for 16h. Luciferase production was assessed with Dual-Glo luciferase assay system (Promega) and normalized with respect to Renilla luciferase activity. Data are expressed as fold inductions with respect to unstimulated cells.

2.7. Statistical analysis

Statistical significance of *in vitro* immunological studies was analyzed by nonparametric two-side Mann-Whitney U-test with 95% confidence bounds. For all analyses $p < 0.05$ was considered statistically significant. Statistical analyses were performed using GraphPad Prism Version 5.0 (GraphPad Software, San Diego, CA).

3. Results

3.1. Genetic findings

We identified a novel familial *STAT1* mutation (L283M) in P1 (by WES) and in his mother P2. Other two previously unreported sporadic mutations were detected respectively in P3 and P9 (L351F), and in P6 (L400V). P3 had been previously analyzed for *AIRE* (autoimmune regulator) gene, showing a heterozygous variation 769C > T (R257X) he inherited from his healthy mother. Other mutations were: T385M in P4 and P5 [19], A267V in P7 [2], and T387A in P8 (Pignata personal communication; Higgins *et al.* [20]). All are heterozygous missense mutations (Table 1). Novel *STAT1* mutations affect both CCD and DBD domains.

3.2. Novel mutations result in increasing *STAT1* phosphorylation

We investigated IFN α - and IFN γ -induced p*STAT1* by cytometry from peripheral blood mononuclear cells (PBMCs) of our patients compared to healthy controls (Fig. 1 in [16]). Overall, we observed

Table 1
STAT1 mutations in CMCD patients.

	Sex	Age (years)	Mutation (c.DNA)	Mutation (aa change)	Exon	Affected domain
P1	Male	11	c.(847 T > A)	L283M	Exon 10	CCD
P2	Female	45	c.(847 T > A)	L283M	Exon 10	CCD
P3	Male	33	c.(1441 G > T)	L351F	Exon 12	DBD
P4	Male	15	c.(1542 C > T)	T385M	Exon 14	DBD
P5	Male	10	c.(1542 C > T)	T385M	Exon 14	DBD
P6	Female	7	c.(1198 C > G)	L400V	Exon 14	DBD
P7	Female	14	c.(801 T > A)	A267V	Exon 10	CCD
P8	Male	18	c.(1159 A > G)	T387A	Exon 14	DBD
P9	Female	8	c.(1441 G > T)	L351F	Exon 12	DBD

CMCD = chronic mucocutaneous candidiasis disease; aa = amino acid; CCD = coiled-coil domain; DBD = DNA-binding domain.

higher levels of pSTAT1 compared to healthy controls, following both IFN γ stimulation, in CD14⁺ monocytes (** $p < 0.01$), and IFN α stimulation, in CD3⁺ lymphocytes (** $p < 0.001$), also confirmed for novel STAT1 mutations (P1 and P2, P3 and P9, P6). Our results are consistent with data of published studies and confirm for novel heterozygous alleles the association with a dominant phenotype of gain of STAT1 phosphorylation and function.

3.3. L351F and L400V variants lead to a gain of STAT1 function

We analyzed pSTAT1 in Epstein–Barr Virus (EBV)-transformed lymphoblasts of P3 carrying the novel L351F mutation. As illustrated in Fig. 2A, Western blot showed that STAT1 level was normal in patient cells. pSTAT1 had been undetectable in unstimulated cells derived from P1 and P6, and its level had increased in response to both IFN γ - or IFN β -stimulation (data not shown). In order to prove the gain of function of L351F variant, P3 EBV-transformed lymphoblasts were treated with IFN β or IFN γ in the presence of the ³²P-labeled oligonucleotide STAT-binding probe derived from the IFN γ response region, or type I ISREs. In the presence of both probes, we observed that treatment with IFNs resulted in increased STAT1-binding activity to DNA (Fig. 2B). Moreover, novel mutations L351F (P3 and P9) and L400V (P6) were evaluated by transfection of STAT1-deficient U3C fibrosarcoma cells with STAT1 mutants constructs obtained by site-directed mutagenesis. Responses to cytokine stimulation were investigated by measuring the luciferase activity of the reporter gene under the control of the

γ -activated sequence (GAS) promoter. After stimulation with IFN γ or IL27, cells transfected with L351F or L400V alleles responded stronger than those transfected with *wild-type* allele. In addition, stimulation with increasing concentrations of IFN γ (10, 100, 1000 U/ml, respectively) resulted in two to five times stronger responses in cells transfected with novel mutant alleles (Fig. 2D). These results demonstrated how novel heterozygous alleles are GOF for GAS-dependent cellular responses to IFN γ .

3.4. A broad spectrum of infections may manifest beyond chronic candidiasis

3.4.1. Fungal and parasite infections

All patients (mean age 17-year-old, median 14-year-old) presented with recurrent or chronic infection with *Candida albicans* since early childhood (median age at onset <1-year-old) (See Table 2). Oropharyngeal candidiasis manifested in all cases at onset, 5 patients (55%) developed nail infection by their first decade, 4 patients (45%) had oesophageal candidiasis by their second decade, while skin and genital candidiasis were reported in 2 (P1 and P6) and 1 (P7) patients, respectively. In P4 candidiasis manifested only in a mild form, as oral thrush recurring during antibiotic therapy, well responding to topical antifungal medication (miconazole). Mucocutaneous candidiasis was treated with oral azole antifungal drugs (*i.e.* fluconazole, itraconazole, voriconazole), while treatment of oesophageal candidiasis in P2, P3 and P5 required intravenous antifungal therapy (*i.e.* fluconazole,

Table 2
Clinical and laboratory features of nine patients with STAT1-CMCD.

	Age at onset	Age at diagnosis	CMCD	Treatment resistance	Bacterial Infections	Viral infections	Bronchi-ectasis	Hypo-thyroidism	Other autoimmune manifestations	Lympho-penia	Poor vaccine response
P1	1 yr	9 yrs	+	+	URTI, pneumonias	None	–	+	None	–	–
P2	1 yr	43 yrs	+	+	URTI, pneumonias, skin abscesses	None	+	–	None	+	+
P3	6 mo	28 yrs	+	–	URTI, pneumonias, otitis media, skin abscesses, Leishmaniasis, Cryptococcosis	Recurrent molluscum, skin HPV	+	+	SLE-like skin disease, ANA and ds-DNA antibody positivity	+	+
P4	5 yrs	14 yrs	+	–	URTI, pneumonias	None	+	–	Vitiligo, ANA positivity	+/–	+
P5	2 mo	9 yrs	+	+	URTI, pneumonias, otitis media, sepsis	None	–	–	None	+/–	–
P6	2 yr	7 yrs	+	–	URTI, pneumonias, otitis media	None	+	–	None	–	–
P7	6 mo	14 yrs	+	–	URTI, pneumonias	None	–	–	None	+/–	–
P8	7 yrs	17 yrs	+	–	Parodontitis, skin abscesses, suppurative cyclid infection	Severe chicken pox, recurrent herpetic infections	NK	–	None	–	–
P9	5 mo	8 yrs	+	+/–	Pneumonia, episcleritis	Recurrent zoster and herpetic infections	NK	+	None	–	–

“+” = present; “–” = absent; NK = not known; yr.(s) = year(s); mo = months; CMCD = chronic mucocutaneous candidiasis disease; URTI = upper respiratory tract infections; HPV = human papilloma virus; SLE = systemic lupus erythematosus; ANA = antinuclear antibody; ds = double-strand.

Table 3
Pulmonary findings, current treatment and results of last spirometry of GOF-STAT1 patients.

	Age (yr)	Chronic Lung Disease	Site of bronchiectasis	Age at diagnosis (yr)	Respiratory physiotherapy	Age at starting (yr)	FVC L/%pred	FEV ₁ L/%pred	FEV ₁ /FVC %	FEF 25–75% L/s
P1	11	–	NA	NA	–	NA	2.26/96	2.13/106	94	NK
P2	45	+	L lower lobe, lingula	21	PEP-mask device + short acting bronchodilators, 2 times per day, regularly	30	3.05/88	2.62/84	81	3.42
P3	33	+	L lower lobe, lingula	10	PEP-mask device + short acting bronchodilators, 2 times per day, intermittently	12	3.05/68	2.17/58	71	1.49
P4	15	+	L lower lobe, lingula, R middle lobe	14	PEP-mask device + short acting bronchodilators, 3 times per day, regularly	14	3.54/92	2.66/80	75	2.19
P5	10	–	NA	NA	PEP-mask device + short acting bronchodilators, initially intermittently (i.e. during pulmonary infection), then 2 times per day, regularly	4	1.76/92	1.66/98	94	2.72
P6	7	+	L lower lobe, lingula, R middle lobe	6	PEP-mask device + short acting bronchodilators, 2 times per day, regularly	6	NP	NP	NP	NP
P7	14	–	NA	NA	–	NA	2.76/80	2.72/90	99	4.88
P8	18	–	NA	NA	–	NA	NP	NP	NP	NP
P9	8	–	NA	NA	–	NA	NP	NP	NP	NP

“+” = present; “–” = absent; yr. = years; NA = not applicable; NK = not known; L = left; R = right; PEP = positive expiratory pressure; FVC = forced vital capacity; L = liter; pred = predicted; FEV₁ = forced expiratory volume in 1 s; FEF = forced expiratory flow; NP = not performed.

amphotericin B, caspofungin), followed by oral medications (i.e. fluconazole, itraconazole, or voriconazole). All patients were started on continuous dosing-regimen: fluconazole was initially the drug of first choice for most of the patients, but changed to itraconazole in P1, P2, P3, and P5 following clinical (persistent or relapsing mucocutaneous candidiasis) and microbiological evidence of resistance. The latter has been monitored with susceptibility testing performed on *Candida* spp. cultured from

oropharyngeal swabs, routinely performed in the majority of patients with clinical evidence of infection, and resulting in a minimal inhibitory concentration (MIC) for fluconazole from 8 to 256 mcg/ml in resistant patients. In addition, the majority of patients have been followed with monitoring of serum azole level to concurrently adjust the dosage of medication (target of >500 ng/ml when prophylaxis or >1000 ng/ml when therapy regimen, respectively). We observed, specifically in P2,

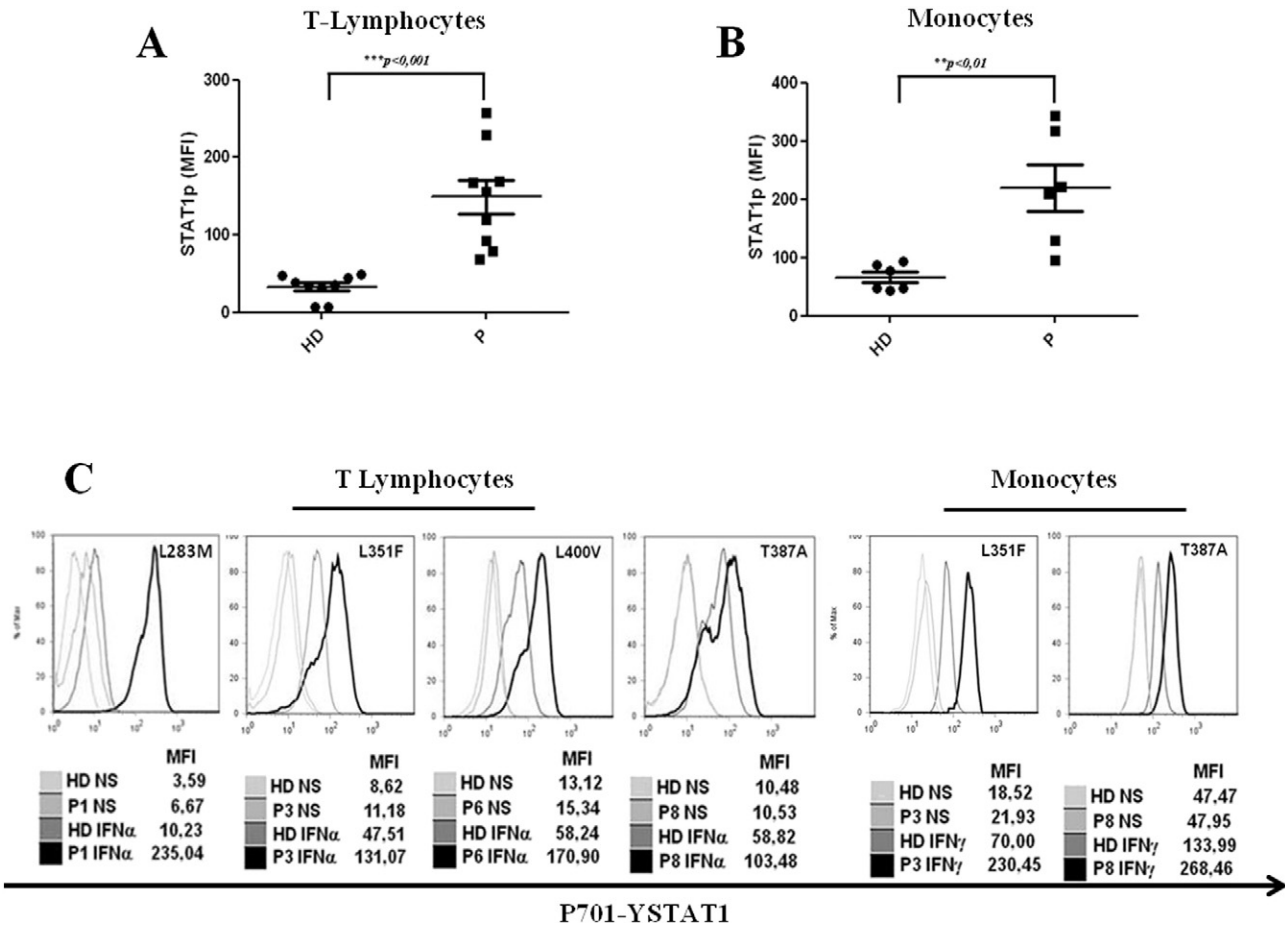


Fig. 1. GOF-STAT1 mutation is associated with increased STAT1 activation. A and B. Summary of mean intensity fluorescence (MFI) of pSTAT1 in T-lymphocytes induced with IFN α (A) and in IFN γ -stimulated monocytes (B). C and D. Intracellular staining of phosphorylated tyrosine 701 STAT1 (P701-YSTAT1) in not stimulated (NS) and IFN α -induced T lymphocytes (C), and not stimulated and IFN γ -induced monocytes (D). Each experiment was independently repeated at least three times for each patient: representative cases are shown. MFI = mean intensity fluorescence; HD = healthy donor.

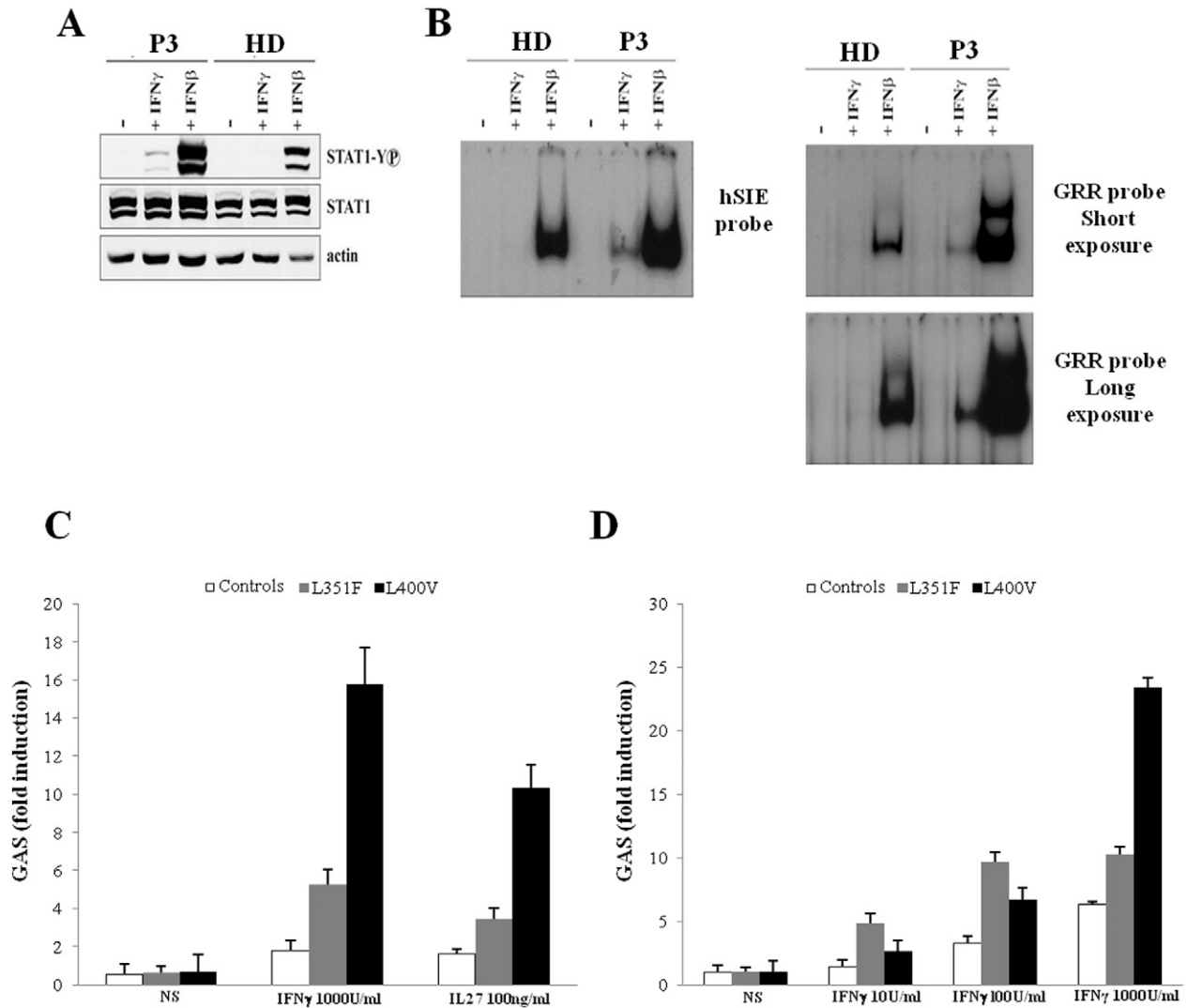


Fig. 2. Novel mutants L351F and L400V *STAT1* alleles are dominant for GAS-dependent cellular responses. A and B. Response of P3 EBV-B cells (L351F) by Western blot (A) and EMSA (B). C and D. Induction of GAS-dependent reporter gene transcription activity in U3C cells transfected with WT or mutant alleles of *STAT1* (L351F and L400V): cells were stimulated with IFN γ or IL27 (C) and increasing doses of IFN γ (D). Results derived from one representative experiment of three independent experiments. HD = healthy donor; NS = not stimulated.

suffering the most severe form of chronic mucocutaneous candidiasis (*i.e.* oropharynx, nails, esophagus), that intermittent regimen treatment and use of suboptimal dosage predisposed to persistent infection and development of resistance to azoles (initially limited to fluconazole, but extended to itraconazole and voriconazole, with current sensitivity for posaconazole). Interestingly, in addition to *Candida* infection, P3 also developed an intracellular pathogen infection with *Cryptococcus neoformans* (Fig. 3), presenting as disseminated granulomatous necrotizing lymphadenitis at the age of 14 years, well responding to intravenous fluconazole. Moreover, at the age of 28 years, the same patient suffered from disseminated visceral leishmaniasis, was initially treated with amphotericin B, but the latter caused drug-related nephropathy, and was replaced with miltefosine.

3.4.2. Bacterial infections

The majority of patients (no relevant episodes in P8 history) had a history of recurrent upper respiratory tract infections and experienced pneumonias (See Table 2), variably associated with bouts of obstructive bronchitis, since their childhood, often requiring hospitalization for intravenous antibiotic therapy. *Haemophilus influenzae*, *Streptococcus pneumoniae*, or *Staphylococcus aureus* were the pathogens usually detected in the sputum, when culture was available. Moreover, some patients had recurrent pulmonary exacerbations with opportunistic

pathogens. P2, P4 and P6 had been suffering from intermittent infection with *Pseudomonas aeruginosa*; in P4 bronchopneumonia with *Serratia marcescens* recurred twice when he was 14-year-old. The recurrence of pulmonary infections has currently led to permanent lung damage in 4 patients of our cohort (P2, P3, P4, P6), as diagnosed by chest computed tomography (CT)-scan (Pulmonary findings summarized in Table 3; see Fig. 2 in [16]). All patients had been commenced on pneumonologist follow-up, together with regular respiratory physiotherapy, in order to enhance clearance of bronchial secretion and control pulmonary exacerbations [21–23]. The analysis of spirometry results [24] in these patients developing chronic lung disease shows a tendency to develop obstructive pulmonary disease, with a forced expiratory volume in 1 s (FEV₁) generally below normal range, associated to a reduction in the forced expiratory flow during the interval 25–75% of the forced vital capacity (FEF 25–75%). These changes of FEF 25–75% constitute a sensitive parameter in the detection of obstructive small airway disease [25]. Specifically, P4 has experienced a rapid decline of his lung function (Forced Vital Capacity -FVC- from 3.17 to 2.17 L, FEV₁ from 2.35 to 1.68 L, and FEF 25–75% from 1.78 to 1.49 L/s) in a eight-months time characterized by pulmonary exacerbations with *Serratia*: in this patient, in few months, we have currently observed a return of his pulmonary tests to normal values (FVC 3.54 L, FEV₁ 2.66 L, FEF 25–75% 2.19 L/s) and no pulmonary exacerbations, likely related to the increase of daily

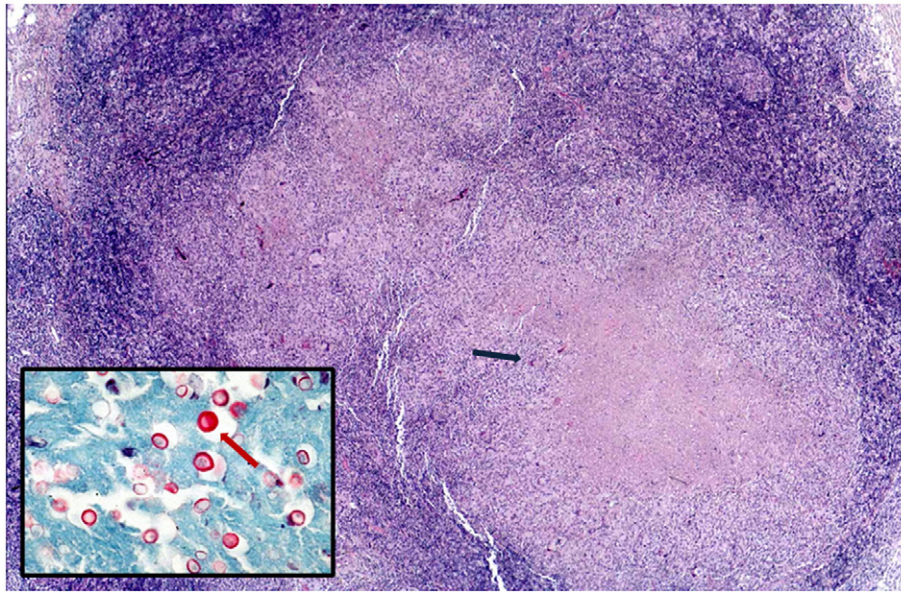


Fig 3. Necrotizing granulomatous lymphadenitis (blue arrow), containing numerous mucicarmine-positive cryptococci (red arrow) (Hematoxylin-Eosin; inset: mucicarmine stain).

respiratory physiotherapy and the start of antibiotic prophylaxis with azithromycin, following the rationale of a reduction of pulmonary exacerbations in patients with non-cystic fibrosis bronchiectasis by using low-dose macrolide [26].

Among other bacterial infections, our cohort features abscesses and sepsis. Three patients (P2, P3, and P8) suffered from skin abscesses: in P3 a coagulase negative *Staphylococcus* was detected and infection resolved after intravenous antibiotic and surgical excision, while P8 had recurrent *S. aureus*-positive abscesses requiring systemic antibiotic treatment, and P2 was alternately treated with oral or intravenous antibiotics for recurrent boils. P5 had a *Streptococcus viridians* sepsis, concomitantly to a *Pneumocystis jirovecii* pneumonia, at the age of four months (lymphocyte subsets had been performed few months after the acute episode with normal results), while P2 sepsis was caused by *Difteroides* spp. when 28-year-old.

3.4.3. Viral infections

We observed abnormal response to viral infections in some patients (See Table 2). P8 had varicella with severe involvement of mucosa at the age of 8 years. Both P8 and P9 presented with recurrent mucocutaneous infections with herpes simplex viruses and severe episodes of varicella-zoster infection. P3 had molluscum and human papilloma virus cutaneous lesions.

3.5. Autoimmune manifestations may be part of a heterogeneous phenotype

In our cohort, hypothyroidism manifested in three patients (P1, P3, and P9; see Table 2): all cases had negative auto-antibodies (antithyroglobulin, antithyroid peroxidase, anti thyroid-stimulating hormone -TSH- receptor antibody), but typically presented a dysomogeneous ultrasound appearance of the gland. All patients started the treatment of hypothyroidism with levothyroxine by their first decade of life. On autoimmune screening, antinuclear antibodies tested positive in P3 (title increasing from 1:160 to 1:320) and P4 (stable title 1:320), in P3 also associated to positivity for anti-double strand DNA antibodies (138–122%, normal value <35%): P3 has developed Systemic Lupus Erythematosus (SLE)-like skin face lesions, while P4 suffers from a mild form of vitiligo. Despite cerebral vasculitis and cerebral and aortic

aneurysms have been reported [19], none of our patients ever had signs or symptoms suggesting investigation for cerebral or heart complications.

3.6. The immunological phenotype: risk of progressing lymphopenia

Analysis of lymphocyte subsets in each patient of our cohort (Fig. 4; see Table 1 in [16]) revealed persistent lymphopenia in two adult patients. In P2, total lymphocytes range from a maximum of 1250 cells/mmc to 810 cells/mmc (mean below 1000 cells/mmc), with low counts of both T and B lymphocytes (normal $CD4^+/CD8^+$ ratio and NK cell counts in the normal range). P3 developed lymphopenia in his twenties, with total lymphocytes ranging from 700 to 1130 cells/mmc, low numbers of $CD3^+$ (375–730 cells/mmc), $CD4^+$ (233–421 cells/mmc), and $CD8^+$ (128–272 cells/mmc) cells, but normal B cell count (261–335 cells/mmc). Interestingly, P3 also showed low NK cells count, that was persistently below 50 cells/mmc (11–44 cells/mmc). In P4 we observed transitory reduction of $CD4^+$ T cells (382 cells/mmc), out of a specific infectious episode, in P5 low $CD4^+$ T cells (1153 cells/mmc) during his first year of life, but out of his episode of sepsis, and in P7 a single determination of low $CD19^+$ cells (152 cells/mmc). Moreover, lymphocyte subsets analysis in six patients showed a low percentage of memory B cells, with reduction of both un-switched (median 3% of B cells) and switched subsets (median 1% of B cells) (see Table 1 in [16]).

Three patients (P2, P3, P4) also had defective antibody response to tetanus toxoid (<0.05 UI/ml), with unprotective title confirmed after booster vaccine. Overall, serum immunoglobulin levels, TRECs, and lymphocyte proliferation assays to mitogens did not show abnormalities (data not shown). We observed low immunoglobulin (Ig) M level only in P1 in different determinations (IgM 31 mg/dl -range 56–261- at the age of 6 year-old; IgM 46 mg/dl -range 61–276- at the age of 10), with normal IgG (1040 mg/dl -range 707–1919-) and IgA (143 mg/dl -range 60–270-).

4. Discussion

4.1. Novel mutations confirm the increased STAT1 phosphorylation

We describe nine patients of Caucasian origin and Italian nationality with heterozygous GOF mutations in *STAT1*. Three novel mutations were identified: L283M in the CCD, while L351F and L400V in the

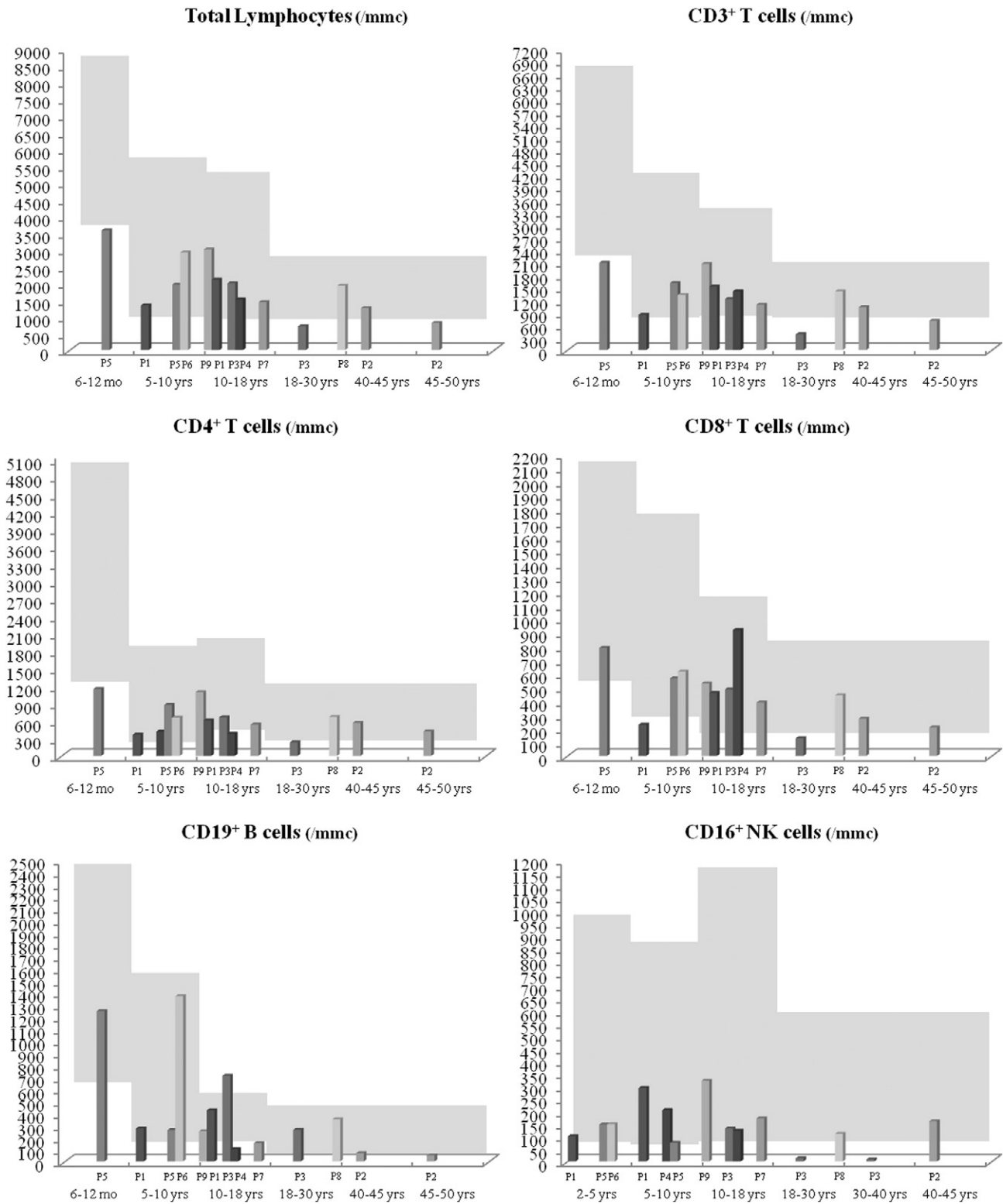


Fig. 4. Lymphocyte subsets for each CMCD patient are shown as a single value per age range. Normal ranges of lymphocyte counts, we have illustrated in the chart background, were based on age-matched healthy control subjects. The complete series of lymphocyte counts is shown in the Table 1 in [16].

DBD. The underlying pathogenesis involves a gain of STAT1 phosphorylation resulting in a gain-of-function of GAF in response to various cytokines. Consistently with previous reports, levels of pSTAT1 are high in CD3⁺ and CD14⁺ cells, gamma-activated sequence binding activity increases following stimulation with IFN γ , and cellular response is enhanced to cytokines such as IFN- α/β , IFN- γ , and IL-27, which potently inhibit development of IL-17-producing T cells *via* STAT1 [1–3,27].

4.2. CMCD represents the hallmark of GOF-STAT1 phenotype with high risk of resistance to treatment

In the clinical phenotype of the majority of patients, CMCD represents the main manifestation and feature of suspicion at onset, but severity largely varies from chronic recurrent and debilitating infection to milder form, detectable after detailed questioning of medical history,

or occurring only during antibiotic therapy. We show high risk of developing resistance to oral antifungal treatment, associated to high MIC to azoles (*i.e.* fluconazole), and resulting in chronic infection with *Candida*. Development of antifungal resistance in our patients was not associated to any specific STAT1 mutations. Conversely, STAT1 patients displaying mild forms of candidiasis may suggest that genetic or environmental factors could contribute to their susceptibility to fungal infections. In particular, intermittent regimens of antifungal treatment or use of azoles at suboptimal doses might favor the selection of azole-resistant strains of *Candida*. Development of azole-resistance may require use of alternative regimens including caspofungin, or liposomal amphotericin B, that are administered by an intravenous route. In addition, case report studies have suggested that immunomodulatory treatment with cytokines such as granulocyte-colony stimulating factor (G-CSF) or granulocyte monocyte-colony stimulating factor (GM-CSF) may restore the generation of Th17 cells and parallel enhance recovery from fungal infections [28]. However, these preliminary findings should be confirmed in larger cohort of patients. Until then, our study suggests that antifungal prophylaxis with fluconazole or itraconazole should be commenced in all patients at the time of diagnosis, regularly continued and strictly monitored by pharmacokinetics measurements and susceptibility testing, in order to optimize control of diffuse candidiasis, prevent developing of inadequate dose-related resistance, and guarantee efficient treatment.

4.3. A broader spectrum of infections, the occurrence of chronic lung disease, lymphopenia, or autoimmunity may complicate the prognosis

GOF-STAT1 patients may typically experience also recurrent bacterial infections since early childhood, and present viral diseases mainly with herpes family viruses [12,13,15,29], causing high morbidity and increasing the mortality risk. Specifically, Sherfe *et al.* reported of three patients who died of overwhelming viral infections (Cytomegalovirus, Epstein–Barr virus, and Jamestown Canyon virus, respectively), interestingly presenting with a combined immunodeficiency (CID)-like immunological phenotype (progressive loss of T cells and natural killer cells, plus humoral defect). In our cohort, we observed that lymphopenia, manifesting with reduction in CD3⁺, CD4⁺ and CD8⁺ lymphocytes subsets, may not be constantly present, but might progress by adulthood. Consistent with that, careful monitoring of main lymphocyte subsets could help in clinical management by early detection of patients developing severe lymphopenia that might require to be evaluated for hematopoietic stem cell transplantation (HSCT). Interestingly, we report a reduction in both un-switched and switched memory B cells in the majority of our patients, supporting a previous observation in the case report by Frans *et al.* [30]. Currently, any genotype–phenotype correlation seems consistent, even though we observed same characteristic features in patients with same mutations. Particularly, in our cohort an increased susceptibility to viral infections manifested in patients carrying L351F and T387A variants. Meanwhile, we observed how T385M variant differently manifested in two patients with similar age and sex: P4 suffered from severe and recurrent lower respiratory tract infections and developed bronchiectasis and chronic lung disease in his adolescent age; P5 presented with early severe reflux disease, required Nissen fundoplication, and had jatal hernia, concurrently with oesophageal candidiasis. Similarly, in previous reports [30], this mutation variably presented with mainly gastrointestinal or respiratory phenotype, but also with progressing combined immunodeficiency predisposing to fatal infections [15,19,31]. For other novel mutations herein identified, major phenotypic manifestations include early development of bronchiectasis in patient carrying the L400V variant, and lymphopenia and chronic lung disease progressing by adulthood in the familiar variant L283M. These phenotypes may add new characteristic manifestations, but are insufficient to hypothesize any certain correlation with the genotype; indeed, the paucity of reported cases likely suggests any observed association still as serendipity. More important, we show

how lung disease represents a major complication as it may slowly evolve by adulthood to permanent lung damage predisposing to recurrent pulmonary exacerbations and higher morbidity. Early recognition of lung damage at initial stage associated to prompt aggressive treatment of pulmonary infection and daily respiratory physiotherapy might prevent progression of the disease. The role of antibiotic prophylaxis, including low-dose macrolide, could be controversial because of increased risk of progressing candidiasis. Finally, autoimmune manifestations represent common features of the disorder and extensive autoimmune assessment should be regularly performed; consistently with what previously reported, thyroidopathy represents the most common disorder [1,19], variably onsets by the first or second decade of life, associates to no thyroid antibody or significant alterations of B subsets, but gland abnormalities, supporting the hypothesis of an increased response to type I IFNs and the role of IFNs signature in the disease [3,32]. Recently, Oftedale *et al.* redefined a “non-classical” form of autoimmune polyendocrine syndrome type 1 (APS-1) where a milder, less penetrant autoimmune phenotype associates to dominant heterozygous mutations in AIRE [33]. Even though AIRE p.R257 mutation is known to behave in a recessive manner, further characterization could be pursued to rule out the role of AIRE mutation in our patient P3 who features CMCD together with a mild autoimmune phenotype.

5. Conclusion

GOF-STAT1 disorder represents an emerging primary immunodeficiency and analysis of larger cohort of patients is warranted to better characterize clinical and genetic heterogeneity, long-term complications, and prognosis of the disease.

References

- [1] L. Liu, S. Okada, X.-F. Kong, A.Y. Kreins, S. Cypowyj, A. Abhyankar, *et al.*, Gain-of-function human STAT1 mutations impair IL-17 immunity and underlie chronic mucocutaneous candidiasis, *J. Exp. Med.* 208 (2011) 1635–1648.
- [2] F.L. van de Veerdonk, T.S. Plantinga, A. Hoischen, S.P. Smeekens, L.A.B. Joosten, C. Gilissen, *et al.*, STAT1 mutations in autosomal dominant chronic mucocutaneous candidiasis, *N. Engl. J. Med.* 365 (2011) 54–61.
- [3] S. Boisson-Dupuis, X.-F. Kong, S. Okada, S. Cypowyj, A. Puel, L. Abel, *et al.*, Inborn errors of human STAT1: allelic heterogeneity governs the diversity of immunological and infectious phenotypes, *Curr. Opin. Immunol.* 24 (2012) 364–378.
- [4] A. Puel, C. Picard, S. Cypowyj, D. Lilic, L. Abel, J.-L. Casanova, Inborn errors of mucocutaneous immunity to *Candida albicans* in humans: a role for IL-17 cytokines? *Curr. Opin. Immunol.* 22 (2010) 467–474.
- [5] D. Averbuch, A. Chappier, S. Boisson-Dupuis, J.-L. Casanova, D. Engelhard, The clinical spectrum of patients with deficiency of Signal Transducer and Activator of Transcription-1, *Pediatr. Infect. Dis. J.* 30 (2011) 352–355.
- [6] D. Vairo, L. Tassone, G. Tabellini, N. Tamassia, S. Gasperini, F. Bazzoni, *et al.*, Severe impairment of IFN- γ and IFN- α responses in cells of a patient with a novel STAT1 splicing mutation, *Blood* 118 (2011) 1806–1817.
- [7] A. Chappier, S. Boisson-Dupuis, E. Jouanguy, G. Vogt, J. Feinberg, A. Prochnicka-Chalufour, *et al.*, Novel STAT1 alleles in otherwise healthy patients with mycobacterial disease, *PLoS Genet.* 2 (2006), e131.
- [8] J. Bustamante, S. Boisson-Dupuis, L. Abel, J.-L. Casanova, Mendelian susceptibility to mycobacterial disease: genetic, immunological, and clinical features of inborn errors of IFN- γ immunity, *Semin. Immunol.* 26 (2014) 454–470.
- [9] M. Tanimura, K. Dohi, M. Hirayama, Y. Sato, E. Sugiura, H. Nakajima, *et al.*, Recurrent inflammatory aortic aneurysms in chronic mucocutaneous candidiasis with a gain-of-function STAT1 mutation, *Int. J. Cardiol.* 196 (2015) 88–90.
- [10] E.P. Sampaio, A.P. Hsu, J. Pechacek, H.I. Bax, D.L. Dias, M.L. Paulson, *et al.*, Signal transducer and activator of transcription 1 (STAT1) gain-of-function mutations and disseminated coccidioidomycosis and histoplasmosis, *J. Allergy Clin. Immunol.* 131 (2013) 1624–1634.
- [11] N. Kumar, M.E. Hanks, P. Chandrasekaran, B.C. Davis, A.P. Hsu, N.J. Van Wagoner, *et al.*, Gain-of-function signal transducer and activator of transcription 1 (STAT1) mutation-related primary immunodeficiency is associated with disseminated mucormycosis, *J. Allergy Clin. Immunol.* 134 (2014) 236–239.
- [12] B. Tóth, L. Méhes, S. Taskó, Z. Szalai, Z. Tulassay, S. Cypowyj, *et al.*, Herpes in STAT1 gain-of-function mutation [corrected], *Lancet* 379 (2012) 2500.
- [13] S.S. Kilić, A. Puel, J.-L. Casanova, Orf infection in a patient with Stat1 gain-of-function, *J. Clin. Immunol.* 35 (2014) 80–83.
- [14] G. Uzel, E.P. Sampaio, M.G. Lawrence, A.P. Hsu, M. Hackett, M.J. Dorsey, *et al.*, Dominant gain-of-function STAT1 mutations in FOXP3 wild-type immune dysregulation-polyendocrinopathy-enteropathy-X-linked-like syndrome, *J. Allergy Clin. Immunol.* 131 (2013) 1611–1623.

- [15] N. Sharfe, A. Nahum, A. Newell, H. Dadi, B. Ngan, S.L. Pereira, et al., Fatal combined immunodeficiency associated with heterozygous mutation in STAT1, *J. Allergy Clin. Immunol.* 133 (2014) 807–817.
- [16] L. Dotta, O. Scomodon, R. Padoan, S. Timpano, A. Plebani, A. Soresina, et al., Clinical and Immunological Data of Nine Patients with Chronic Mucocutaneous Candidiasis Disease, 2015 (Data in Brief submitted for publication).
- [17] J.T. Den Dunnen, E. Antonarakis, Nomenclature for the description of human sequence variations, *Hum. Genet.* 109 (2001) 121–124.
- [18] J.D. Dignam, R.M. Lebovitz, R.G. Roeder, Accurate transcription initiation by RNA polymerase II in a soluble extract from isolated mammalian nuclei, *Nucleic Acids Res.* 11 (1983) 1475–1489.
- [19] B. Soltész, B. Tóth, N. Shabashova, A. Bondarenko, S. Okada, S. Cypowyj, et al., New and recurrent gain-of-function STAT1 mutations in patients with chronic mucocutaneous candidiasis from Eastern and Central Europe, *J. Med. Genet.* 50 (2013) 567–578.
- [20] E. Higgins, T. Al Shehri, M.A. McAleer, N. Conlon, C. Feighery, D. Lalic, et al., Use of ruxolitinib to successfully treat chronic mucocutaneous candidiasis caused by gain-of-function signal transducer and activator of transcription 1 (STAT1) mutation, *J. Allergy Clin. Immunol.* 135 (2015) 551–553.
- [21] S. Groth, G. Stafanger, H. Dirksen, J.B. Andersen, M. Falk, M. Kelstrup, Positive expiratory pressure (PEP-mask) physiotherapy improves ventilation and reduces volume of trapped gas in cystic fibrosis, *Bull. Eur. Physiopathol. Respir.* 21 (1985) 339–343.
- [22] K. Hill, S. Patman, D. Brooks, Effect of airway clearance techniques in patients experiencing an acute exacerbation of chronic obstructive pulmonary disease: a systematic review, *Chron. Respir. Dis.* 7 (2010) 9–17.
- [23] A. Plebani, R. Pinzani, R. Startari, D. Brusa, R. Padoan, Usefulness of chest physiotherapy with positive expiratory pressure (PEP)-mask in HIV-infected children with recurrent pulmonary infections, *Acta Paediatr.* 86 (1997) (1992) 1195–1197.
- [24] S. Stanojevic, A. Wade, J. Stocks, J. Hankinson, A.L. Coates, H. Pan, et al., Reference ranges for spirometry across all ages: a new approach, *Am. J. Respir. Crit. Care Med.* 177 (2008) 253–260.
- [25] M.R. Simon, V.M. Chinchilli, B.R. Phillips, C.A. Sorkness, R.F. Lemanske, S.J. Szefer, et al., Forced expiratory flow between 25% and 75% of vital capacity and FEV1/forced vital capacity ratio in relation to clinical and physiological parameters in asthmatic children with normal FEV1 values, *J. Allergy Clin. Immunol.* 126 (2010) 527–534.
- [26] V.L. Yap, M.L. Metersky, New therapeutic options for noncystic fibrosis bronchiectasis, *Curr. Opin. Infect. Dis.* 28 (2) (2015) 171–176.
- [27] Y. Yamazaki, M. Yamada, T. Kawai, T. Morio, M. Onodera, M. Ueki, et al., Two novel gain-of-function mutations of STAT1 responsible for chronic mucocutaneous candidiasis disease: impaired production of IL-17A and IL-22, and the presence of anti-IL-17F autoantibody, *Journal of Immunology* (Baltimore, MD 193 (2014) (1950) 4880–4887.
- [28] G. Wildbaum, E. Shahar, R. Katz, N. Karin, A. Etzioni, S. Pollack, Continuous G-CSF therapy for isolated chronic mucocutaneous candidiasis: complete clinical remission with restoration of IL-17 secretion, *J. Allergy Clin. Immunol.* 132 (2013) 761–764.
- [29] Y. Mizoguchi, M. Tsumura, S. Okada, O. Hirata, S. Minegishi, K. Imai, et al., Simple diagnosis of STAT1 gain-of-function alleles in patients with chronic mucocutaneous candidiasis, *J. Leukoc. Biol.* 95 (2014) 667–676.
- [30] G. Frans, L. Moens, H. Schaballie, L. Van Eyck, H. Borgers, M. Wuyts, et al., Gain-of-function mutations in signal transducer and activator of transcription 1 (STAT1): chronic mucocutaneous candidiasis accompanied by enamel defects and delayed dental shedding, *J. Allergy Clin. Immunol.* 134 (5) (2014) 1209–1213.
- [31] S. Takezaki, M. Yamada, M. Kato, M.-J. Park, K. Maruyama, Y. Yamazaki, et al., Chronic mucocutaneous candidiasis caused by a gain-of-function mutation in the STAT1 DNA-binding domain, *Journal of Immunology* (Baltimore, MD 189 (2012) (1950) 1521–1526.
- [32] Y.J. Crow, Type I interferonopathies: Mendelian type I interferon up-regulation, *Curr. Opin. Immunol.* 32C (2014) 7–12.
- [33] B.E. Oftedal, A. Hellesen, M.M. Erichsen, E. Bratland, A. Vardi, J. Perheentupa, et al., Dominant mutations in the autoimmune regulator AIRE are associated with common organ-specific autoimmune diseases, *Immunity* 42 (2015) 1185–1196.