

# Localization of orexin B and receptor 2 for orexins in testicular cytotypes of the camelid alpaca (*Vicugna pacos*)

G Liguori<sup>1</sup> | C Squillacioti<sup>1</sup> | L Assisi<sup>2</sup> | N Mirabella<sup>1</sup> | E Langella<sup>3</sup> | A Costagliola<sup>1</sup> | A Vittoria<sup>1</sup>

<sup>1</sup>Department of Veterinary Medicine and Animal Productions, University of Naples Federico II, Naples, Italy

<sup>2</sup>Department of Biology, University of Naples Federico II, Naples, Italy

<sup>3</sup>School of Agricultural, Forestry, Food and Environmental Sciences, University of Basilicata, Potenza, Italy

## Correspondence

Loredana Assisi, Department of Biology, University of Naples Federico II, Naples, Italy.  
Email: assisi@unina.it

## Contents

The orexins A (OxA) and B (OxB) are two hypothalamic peptides involved in many physiological functions of the mammalian body. They act through the binding of two G-coupled receptors named receptor 1 (OX<sub>1</sub>) and receptor 2 (OX<sub>2</sub>) for orexins. The first receptor is specific for OxA, while the second binds both the substances with equal affinity. The orexins and the relative receptors have been traced by means of different techniques also at the periphery of the body and particularly in the adrenals, and in gastrointestinal and genital organs. Aim of this work was to investigate the presence of OxB and OX<sub>2</sub> by means of immunohistochemistry and Western blotting analysis in the testis of the South American camelid alpaca, a species primarily bred in Chile and Ecuador and recently diffused in Europe where the quality of its wool is particularly appreciated. OxB immunoreactivity (IR) was found in the tubular compartment of the testis where spermatogonia (resting), zygotene and pachytene spermatocytes, and spermatids clearly showed differently sized and shaped cytoplasmic positive structures. OX<sub>2</sub>-IR was found both in the interstitial and tubular compartments of the testis and particularly in Leydig cells and round and elongated spermatids. Western blotting analysis of testis lysates showed the presence of a protein band whose molecular weight corresponded to that currently assigned to OX<sub>2</sub>. Such findings easily translate the hypothesis that OxB and its receptor 2 play a functional role both in the interstitial and tubular compartments of the alpaca testis.

## 1 | INTRODUCTION

Two decades ago, the peptides orexin A (OxA) and orexin B (OxB) were discovered in the rat hypothalamus by two research groups (de Lecea et al., 1998; Sakurai et al., 1998) that worked independently. Such peptides derive from the cleavage of a common precursor molecule, the prepro-orexin, and bind two G-coupled receptors named receptor 1 (OX<sub>1</sub>) and receptor 2 (OX<sub>2</sub>) for orexins. The first receptor is specific for OxA, while the second binds both the substances with equal affinity.

The hypothalamic orexins are involved in the regulation of many functions of the mammalian body such as food intake (Sakurai et al., 1998), sleep-wake cycle (Taheri, Ward, Ghatei, & Bloom,

2000), arterial blood pressure and heart rate (Shirasaka, Nakazato, Matsukura, Takasaki, & Kannan, 1999), sexual behaviour (Muschamp, Dominguez, Sato, Shen, & Hull, 2007), water assumption (Kunii et al., 1999) and plasma corticosterone levels (Kuru et al., 2000). Both the orexins are also involved in the modulation of the hypothalamic/hypophyseal-adrenal/gonadal axes acting both indirectly, on the intermediate steps of the chains, and directly, on the final targets (Martyńska et al., 2006; Voisin, Rouet-Benzineb, Reuter, & Laburthe, 2003).

More recently, the orexins and their receptors, beyond referred as the orexinergic complex, were found to be present in the adrenals and in other peripheral organs belonging to the gastrointestinal and genital tract. Particularly, the presence of OxA, prepro-orexin

and OX<sub>1</sub> has been detected in the principal cells of the epididymis and in some testicular cytotypes of the rat and alpaca (Assisi et al., 2012; Liguori et al., 2012, 2014; Pavone, Tafuri, Avallone, Staiano, & Vittoria, 2009; Tafuri et al., 2009, 2010), in the urethro-prostatic complex of cattle (Russo et al., 2008) and in the normal, hyperplastic and carcinomatous prostate of humans (Valiante et al., 2013, 2015). The expression of OX<sub>1</sub> mRNA has been described in the testis of sheep (Zhang et al., 2005) and chicken (Ohkubo, Tsukada, & Shamoto, 2003) and in the seminal vesicles, penis and epididymis of men (Karteris, Chen, & Randeva, 2004). By contrast, the presence of OxB and OX<sub>2</sub> in the genital tract of mammals has been still poorly studied. The expression of OxB was described in rat testis by means of a radioimmunoassay (Mitsuma et al., 2000), and that of prepro-orexin mRNA was found in rat testis (Jöhren, Neidert, Kummer, Dendorfer, & Dominiak, 2001) and human epididymis and penis (Karteris et al., 2004). The detection of mRNA codifying for OX<sub>2</sub> appears to be species dependent because it was demonstrated in testis, epididymis, penis, seminal vesicles (Karteris et al., 2004) and prostate (Malendowicz, Szyszka, Ziolkowska, Rucinski, & Kwias, 2011) of humans and denied in the sheep (Zhang et al., 2005) and rat testis (Barreiro et al., 2004; Jöhren et al., 2001; Zheng et al., 2014). However, it is probable that the presence of OxB and its receptor 2 in genital organs is more abundant than described up to now. A recent study performed experimentally on the rat testis, in fact, assessed that both the molecules are widely diffused in the gonad along the majority of the stages of the germ cell developing cycle (Liguori et al., 2017).

The study of the orexinergic complex has never been applied, at least in our knowledge, to the genital tract of non-conventional ruminants of zootechnical interest. For this reason, we began a research on the presence and role played by the complex in the testis of the camelid alpaca (*Vicugna pacos*) (Liguori et al., 2012), whose breeding extended in the last years from the lands of origin to many countries in the world. The alpaca is a camelid phylogenetically similar to llama (*Lama glama*) and guanaco (*Lama guanicoe*) native of the Andean regions of South America, from Ecuador to southern Chile. In these countries, the alpaca breeding always played an important role for meat and wool production, and the recent diffusion of the species is particularly due to the quality of its wool which is greatly appreciated mainly in USA, Australia and Europe (Schwalm, Gauly, Erhardt, & Bergmann, 2007). At present, in Italy, 38 farms gained credit for management and breeding of this species and were officially recognized by the association of alpaca breeders (Italpaca).

Obviously, the knowledge of the reproductive physiology of alpaca is still poorly developed being founded mainly on practice as far as mating and selection. In countries having more temperate climate than those of origin, the alpaca is considered a non-seasonal breeder because the increased availability of food surely enhanced its fertility (Fowler, 1998).

To give further insight to the argument, here we describe the presence of OxB and OX<sub>2</sub> in the alpaca testis by means of an immunohistochemical technique and assess the expression of OX<sub>2</sub> using Western blotting analysis.

## 2 | MATERIAL AND METHODS

### 2.1 | Antibodies and chemicals

Mouse anti-OxA (MAB763) and anti-OxB (MAB734) monoclonal antibodies and their synthetic peptides were obtained from R&D Systems (Abingdon, UK) and from Tocris Bioscience (Bristol, UK), respectively; goat polyclonal anti-OX<sub>2</sub> antibody (sc-8074) and its blocking peptide (sc-8074 P) from Santa Cruz Biotechnologies (Santa Cruz, CA, USA); horseradish peroxidase-conjugated rabbit anti-goat IgG (A-5420) and bovine serum albumin (BSA) from Sigma Chemical Co. (St. Louis, MO, USA); and biotinylated goat anti-mouse (BA-9200), rabbit anti-goat (BA-1000) secondary antibodies and avidin-biotin complex (PK-6105) from Vector Laboratories (Burlingame, CA, USA). SDS-PAGE and the semidry apparatus were purchased from Bio-Rad (Hercules, CA, USA); enhanced chemiluminescence kit (RPN 2109) from ECL Amersham (Little Chalfont, Buckinghamshire, UK) and marker proteins from ProSieve QuadColor (London, UK).

### 2.2 | Animals

The animals employed in this research were kept in optimal sanitary and nutritional conditions in the "Domus Alpaca" farm (Pratola Peligna, Italy) where they were bred following a semirange condition. Five healthy males of approximately seven years of age were chosen for orchietomy. The surgical operation was performed according to Fowler (1998). The study protocol was in compliance with our institution's ethical guidelines. All procedures were approved by Italian laws regarding animal use in research (D. Lgs 116/92). All subjects were lacking of preputial adhesions which is considered a signal of sexual maturity (Tibary & Vaughan, 2006). Tissue collection was performed as described by Liguori et al. (2013). After removal, the testes were finely cut in small samples which were either fixed in Bouin's fluid for immunohistochemistry as described in details elsewhere (Squillacioti, De Luca, Paino, Langella, & Mirabella, 2009) or frozen in liquid nitrogen and stored at -80°C until used for Western blotting analysis.

### 2.3 | Immunohistochemistry

The fixed material was dehydrated in a series of ascending alcohols, embedded in Paraplast in vacuum and cut into 6-µm-thick sections. To obtain consecutive stained microscopic fields, series of 3-µm-thick sections were cut and mounted on numbered slides. The avidin-biotin-peroxidase complex (ABC) method was performed according the protocol previously described by De Luca et al., 2014. In the specific step, mouse monoclonal anti-OxB and anti-OxA and goat polyclonal anti-OX<sub>2</sub> primary antibodies, 1:200 diluted, were applied on sections overnight at 4°C. The day after, the antibodies were removed by a triple PBS washing and the sections were incubated at room temperature (18-22°C) in biotinylated goat anti-mouse IgG or rabbit anti-goat IgG, both 1:200 diluted, for 30 min. After washing, a further incubation was performed in freshly prepared ABC reagent for 30 min. 3-3' Diaminobenzidine was used as final staining. Some sections were

counterstained with haematoxylin to better localize the positivities. The specificity of the immunoreaction was tested by substituting the primary antibody with PBS or preabsorbing the antibody with an excess (100  $\mu\text{g}/\text{ml}$ ) of the relative antigen. Control sections resulted always negative. As a further specificity control of the two antibodies directed against OxB and OxA, couples of consecutive 3- $\mu\text{m}$ -thick sections were alternately stained with them and carefully checked for the eventual coexistence of the two positivities in the same structure. Coexistence, in fact, could imply cross-reactivity of an antibody (or both) with the heterologous antigen(s). The preparations were observed by a Nikon Eclipse E 600 light microscope, and microphotographs were taken by a Nikon Coolpix 8400 digital camera.

## 2.4 | Western blotting analysis

Frozen tissues were homogenized in a buffer (50 mM Tris-HCl, pH 7.00; 150 mM NaCl; 2% Triton; 5 mM EDTA; 10 mg/ml leupeptin; 0.1 U/ml aprotinin; 1 mM PMSF) using an Ultra-Turrax homogenizer and centrifuged at 16,000  $g$  for 20 min at 4°C. The resulting supernatants were characterized for protein concentration by Bio-Rad protein assay. Equal amounts of proteins, solubilized in boiling sodium dodecyl sulphate (SDS) sample buffer (2% SDS; 5% L-mercaptoethanol;

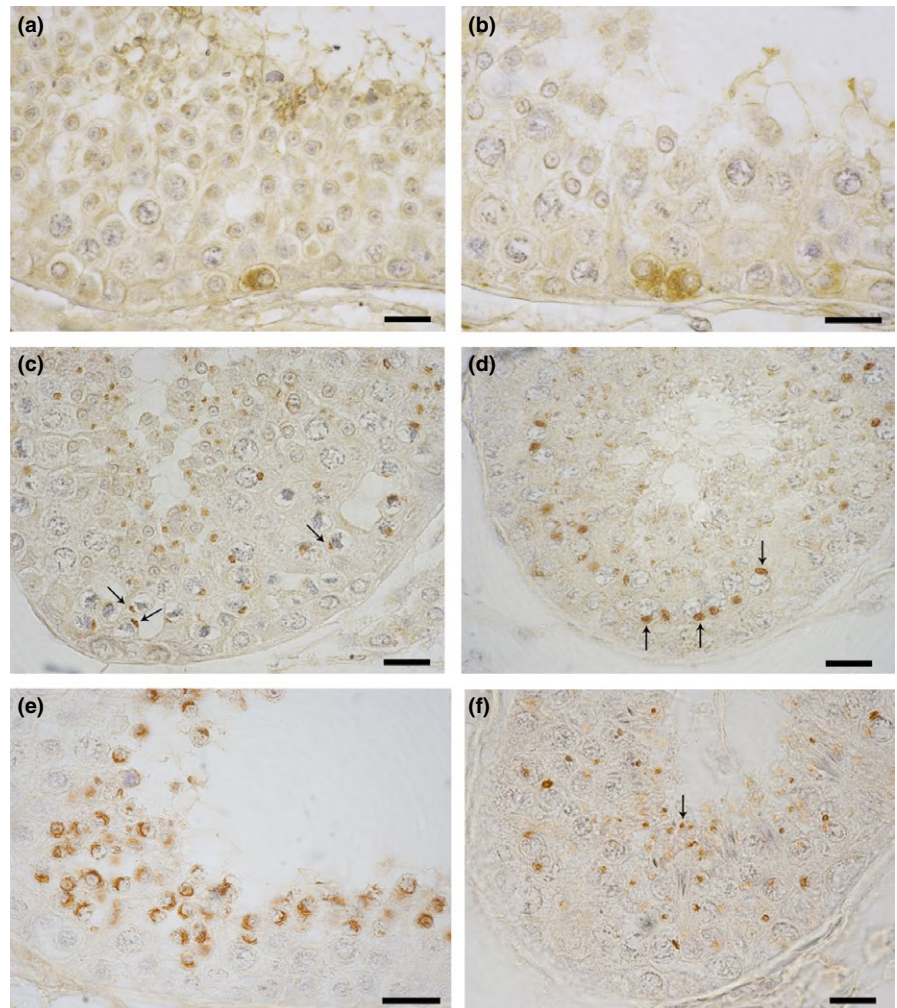
66 mM Tris, pH 7.5; 10 mM EDTA), were separated on a 12% SDS-polyacrylamide gel. After electrophoresis, the gel was transferred to nitrocellulose using a semidry apparatus as described elsewhere (Squillaciotti et al., 2012). The membrane was blocked for 1 hr at 42°C with 5% BSA in TBST buffer (150 mM NaCl; 20 mM Tris-HCl, pH 7.4; 0.3% Tween 20), washed with TBST and incubated for 2 hr at room temperature with goat polyclonal anti-OX<sub>2</sub> antibody 1:500 diluted in 2.5% BSA-containing TBST. The membrane was washed three times with TBST and re-incubated for 1 hr with horseradish peroxidase-conjugated rabbit anti-goat IgG 1:2,000 diluted in 1% BSA-containing TBST. Proteins were visualized by an enhanced chemiluminescence kit. Marker proteins were used to estimate the molecular weight of each band.

## 3 | RESULTS

### 3.1 | Immunohistochemical evaluation of OxB and OX<sub>2</sub> in the alpaca testis

Immunohistochemistry allowed us to demonstrate the following OxB-containing cytotypes in the alpaca testis: spermatogonia (Figure 1a) and preleptotene (resting) (Figure 1b), zygotene

**FIGURE 1** OxB IR in cytotypes of the alpaca testis. (a, b): An isolated spermatogonium (a) and two resting spermatocytes (b) are close in contact with the tubular membrane and show clusters of fine positive granules almost entirely filling their cytoplasm. (c, d): Zygotene (c) and pachytene (d) spermatocytes contain in their perinuclear cytoplasm a single, intensely stained, granular structure, respectively, oval or roundish in shape (arrows). (e, f): Round (e) and elongated (f) spermatids showed two different IR structures in the respective cytoplasm: the first, arciform in shape, embraced tightly portion of the round spermatid nucleus while the second, punctiform in shape, was localized in the tail of the older cells (arrow). Avidin-biotin immunohistochemical technique. Bars: 20  $\mu\text{m}$



(Figure 1c) and pachytene (Figure 1d) spermatocytes as well as young (round) (Figure 1e) and mature (elongated) (Figure 1f) spermatids. In spermatogonia and preleptotene spermatocytes, the positive material had the shape of a cluster of microgranules filling almost entirely the cytoplasm and driving the nucleus at the periphery of the cell. Couples of positive resting spermatocytes newly formed from the spermatogonia mitosis were often seen. In zygotene and pachytene spermatocytes, the OxB immunoreactivity (IR) assumed the aspect of flattened or roundish granules, respectively, which were localized in close perinuclear position. Along the spermatid maturation, the positive material changed in shape and localization following the morphological transformation of the cell which, as known, is round in the young elements and became progressively oval and elongated in the older ones. Young spermatids showed a semilunar-shaped positive structure closely adherent to the nuclear membrane (Figure 1e), while older elements contained a roundish granule at the periphery of the cytoplasm. Pre-spermatozoa elongated spermatids showed such a granule in their tail which was constantly turned towards the tubular lumen (Figure 1f).

Couples of 3- $\mu$ m-thick contiguous sections stained alternately by anti-OxB and anti-OxA antibodies showed that OxB IR never coexisted with OxA-IR in our preparations (Figure 2a–d).

OX<sub>2</sub>-IR was found in Leydig cells (Figure 3a) and round (Figure 3b) and elongated (Figure 3c) spermatids.

In Leydig cells, the positive material was finely granular in shape and diffused in the cytoplasm without any particular distribution. Cells showing different staining intensity were clustered in small groups or intermingled to negative ones in the majority of the interstitial spaces.

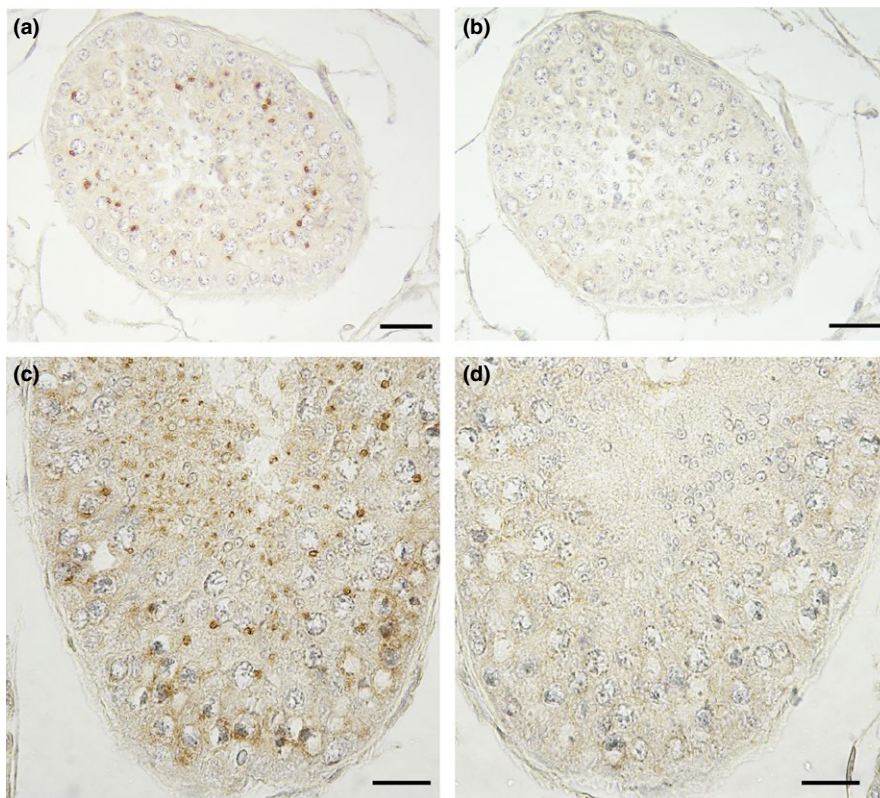
The aspect and localization of the spermatid IR were closely similar to that just described for OxB in the same cytotype.

### 3.2 | Expression of OX<sub>2</sub> in tissue extracts

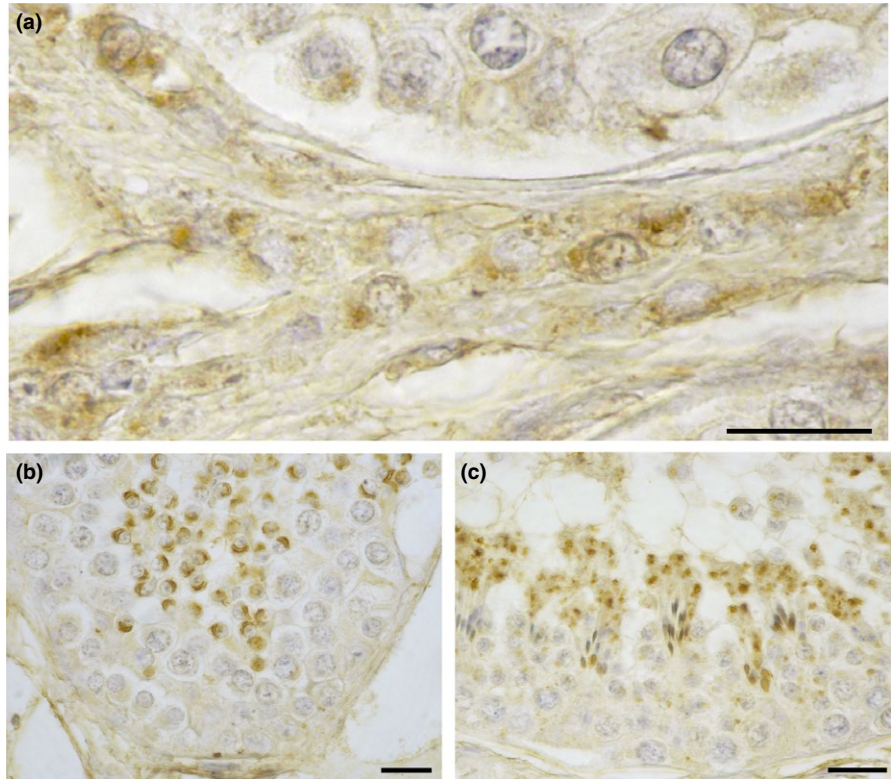
The expression of the OX<sub>2</sub> protein in the alpaca testis was detected by Western blotting analysis using a goat polyclonal antibody raised against a peptide mapping near the C-terminus of OX<sub>2</sub> of rat origin. As a control tissue of our experiment was chosen the rat brain notoriously containing huge amount of the receptor (Cluderay, Harrison, & Hervieu, 2002). Tissue extracts of alpaca testis and rat brain (Figure 4) reacted with the anti-OX<sub>2</sub> antibody which recognized in them a protein band weighting 40 kDa, which is the molecular weight currently assigned to the orexin receptor 2 (Figure 4, lanes 1 and 2, respectively).

## 4 | DISCUSSION

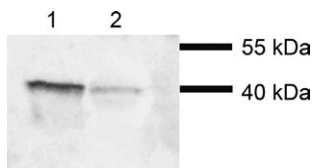
A previous study from our research group described the presence of OxA and its receptor 1 in the alpaca testis (Liguori et al., 2012). The present work reports the expression of the two counterpart substances, OxB and OX<sub>2</sub>, in the same organ, and thus, the existence of the orexinergic complex in the male gonad of the South American camelid is definitely demonstrated. In particular, the presence of OxB in the alpaca testis tissue is supported by the detection of prepro-orexin previously demonstrated by us (Liguori et al., 2012), and in the present study, we demonstrate the presence of the specific receptor, OX<sub>2</sub>.



**FIGURE 2** Specificity control experiment of the anti-OxB and anti-OxA antibodies. (a–d): The staining of two couples (a, b and c, d) of 3- $\mu$ m-thick consecutive sections with the anti-OxB (a, c) and anti-OxA (b, d) antibodies showed that the material positive to the first antibody was not bound by the second. Avidin–biotin immunohistochemical method. Bars: 20  $\mu$ m



**FIGURE 3**  $OX_2$ -IR in cytotypes of the alpaca testis. (a): Small cluster of Leydig cells containing different quantity of small positive granules scattered in their cytoplasm. (b, c): Round (b) and elongated (c) spermatids showed in their cytoplasm arciform or roundish positive structures which, respectively, embraced portion of the nucleus of the younger cells or were localized in the tail of the older ones. Avidin–biotin immunohistochemical technique. Bars: 20  $\mu$ m



**FIGURE 4**  $OX_2$  expression detected by means of Western blotting analysis of testis homogenate. Lane 1: alpaca testis. Lane 2: rat brain. Molecular weight markers are expressed in kDa and reported on the right

The presence of  $OX_1$  in mammalian Leydig cells suggested that OxA could play a role in testicular steroidogenesis (Assisi et al., 2012; Barreiro et al., 2004; Liguori et al., 2012). Particularly, it was hypothesized that OxA, mainly produced by the tubular Sertoli cells, could act on its same source by an autocrine modality of action decreasing the production of Müllerian inhibiting substance (MIS), which is a steroidolitic compound basically synthesized in these cells (Teixeira, Fynn-Thompson, Payne, & Donahoe, 1999). The consequent stimulation of testosterone production was experimentally assessed through the sequential *in vitro* addition of OxA and MIS, and vice versa, to slices of rat and alpaca testis (Assisi et al., 2012; Liguori et al., 2012). To test a potential steroidogenic effect of OxB in the male gonad, an experimental study was performed on *in vitro* cultured rat testis slices (Liguori et al., 2017) in which the steroidogenic activity of OxA was confirmed, but, conversely, OxB was found to be ineffective on testosterone production.

Also the adrenal steroidogenesis has been proved to be influenced by the orexinergic complex. Both the orexins, in fact, stimulated cortisol and corticosterone production from dispersed rat and human

adrenocortical cells through activation of the adenylate cyclase (AC)-dependent signalling cascade (Malendowicz, Tortorella, & Nussdorfer, 1999). The same metabolic pathway was involved in cortisol and aldosterone release stimulation induced by OxA on *in vitro* cultured porcine adrenocortical cells (Nanmoku et al., 2002).

At present, also the role played by the orexins in the activation of intermediate metabolic pathways is poorly known. Karteris et al. (2004) incubated cell membrane fragments from human testicular lysates with the two orexins in an *in vitro* experimental assay. Both the peptides were found to stimulate the phospholipase C (PLC)/inositol phosphate pathway, and OxB proved to be more efficient than OxA in disclosing such a way. More recently, Zheng et al. (2014) demonstrated that OxA activation of  $OX_1$  upregulates testosterone production via the ERK1/2 and p38 MAPK signalling pathway in primary cultures of rat Leydig cells. The role played by the orexinergic complex in the metabolism of other types of steroidogenic cells is, similarly, poorly known. Activation of  $OX_1$  in Chinese hamster ovary (CHO) cells led to a rapid, strong and long-lasting increase in ERK phosphorylation, which was mediated by  $Ca^{++}$  intracellular influx (Ammoun et al., 2006). In the same cellular type, also the OxB-induced  $OX_2$  activation promoted ERK phosphorylation and the intermediate pathway seemed to involve the  $G_q$ /PLC/protein kinase C (PKC) pathway stimulation (Guo & Feng, 2012). In human adrenocortical H295R cells, OxA and OxB enhanced steroidogenesis by regulating the activation of the  $Ca^{++}$ /PKC and ERK1/2 MAPK pathways (Ramanjaneya et al., 2009). Finally, in CHO and adrenocortical cells of rat and human origin, the ligand activation of  $OX_1$  was followed by AC/PLC/PKC (Kukkonen, Holmqvist, Ammoun, & Akerman, 2002) and AC/PKA (Holmqvist et al., 2005) signalling pathway stimulation, respectively.

In the alpaca testis, OxB-IR was described in many tubular cyto-types: spermatogonia, preleptotene (resting), zygotene and pachytene spermatocytes as well as in developing spermatids. OX<sub>2</sub>-IR was found both in the interstitial and the tubular compartments. These results also demonstrate the wide distribution of the two peptides in the male gonad in line with a previous study showing the localization of OxB and OX<sub>2</sub> in rat testis (Liguori et al., 2017). Our research also highlights a similarity between the orexinergic system of the alpaca testis and that described in the rat testis and suggests that this system could play a role in the regulation of spermatogenesis.

## 5 | CONCLUSIONS

In conclusion, the results obtained in this work definitely demonstrate that, in addition to OxA and OX<sub>1</sub> (Liguori et al., 2012), also OxB and OX<sub>2</sub> are widely diffused in the alpaca testis. Although further studies are needed to fully understand the role played in the mammalian testis by the orexinergic complex, we retain that the present knowledge of the argument is sufficient to prospect for the complex a pivotal role in determinism of many physiopathological aspects of the male gonad. A better comprehension of such role could be important also for developing new therapeutic approaches to testicular dysfunctions both in animals and men.

## ACKNOWLEDGEMENTS

We thank Mr Antonio Calamo and Mrs Sabrina Ali for the technical assistance.

## CONFLICT OF INTEREST

We confirm that there are no known conflict of interests to declare and there has been no significant financial support for this research.

## AUTHOR CONTRIBUTIONS

AV contributed to the experimental design, analysis and interpretation of results, and critical review and final editing of the article; GL contributed to the experimental design, performed the immunohistochemistry, contributed to the acquisition and the interpretation of results, and wrote the manuscript; CS and NM contributed to the collection of the surgical specimens, Western blotting method, and acquisition and the interpretation of the results; LA and EL contributed to reagents and analysis tools; AC contributed to the acquisition and the interpretation of results. All the authors discussed the results and contributed to write the final version of the manuscript. All the authors approved the final version of the manuscript.

## REFERENCES

Ammoun, S., Johansson, L., Ekholm, M. E., Holmqvist, T., Danis, A. S., Korhonen, L., ... Kukkonen, J. P. (2006). OX1 orexin receptors activate

- extracellular signal-regulated kinase in Chinese hamster ovary cells via multiple mechanisms: The role of Ca<sup>2+</sup> influx in OX1 receptor signaling. *Molecular Endocrinology*, 20, 80–99.
- Assisi, L., Tafuri, S., Liguori, G., Paino, S., Pavone, L. M., Staiano, N., & Vittoria, A. (2012). Expression and role of receptor 1 for orexins in seminiferous tubules of rat testis. *Cell and Tissue Research*, 348, 601–607.
- Barreiro, M. L., Pineda, R., Navarro, V. M., Lopez, M., Suominen, J. S., Pinilla, L., ... Tena-Sempere, M. (2004). Orexin 1 receptor messenger ribonucleic acid expression and stimulation of testosterone secretion by orexin-A in rat testis. *Endocrinology*, 145, 2297–2306.
- Cluderay, J. E., Harrison, D. C., & Hervieu, G. J. (2002). Protein distribution of the orexin-2 receptor in the rat central nervous system. *Regulatory Peptides*, 104, 131–144.
- De Luca, A., Liguori, G., Squillaciotti, C., Paino, S., Germano, G., Ali, S., & Mirabella, N. (2014). Expression of urocortin and its receptors in the rat epididymis. *Reproductive Biology*, 14, 140–147.
- Fowler, M. E. (1998). Medicine and surgery of South American camelids. In M. E. Fowler (Ed.), *Llama, Alpaca, Vicuna, Guanaco*, 2nd edn (pp. 135–136). Ames, Iowa: Blackwell Publishing, Iowa State University Press.
- Guo, Y., & Feng, P. (2012). OX2R activation induces PKC-mediated ERK and CREB phosphorylation. *Experimental Cell Research*, 318, 2004–2013.
- Holmqvist, T., Johansson, L., Ostman, M., Ammoun, S., Akerman, K. E., & Kukkonen, J. P. (2005). OX1 orexin receptors couple to adenylyl cyclase regulation via multiple mechanisms. *Journal of Biological Chemistry*, 280, 6570–6579.
- Jöhren, O., Neidert, S. J., Kummer, M., Dendorfer, A., & Dominiak, P. (2001). Prepro-orexin and orexin receptors mRNAs are differentially expressed in peripheral tissues of male and female rats. *Endocrinology*, 142, 3324–3331.
- Karteris, E., Chen, J., & Randevo, H. S. (2004). Expression of human prepro-orexin and signaling characteristics of orexin receptors in the male reproductive system. *Journal of Clinical Endocrinology and Metabolism*, 89, 1957–1962.
- Kukkonen, J. P., Holmqvist, T., Ammoun, S., & Akerman, K. E. (2002). Functions of the orexinergic/hypocretinergic system. *American Journal of Physiology. Cell Physiology*, 283, C1567–C1591.
- Kunii, K., Yamanaka, A., Nambu, T., Matsuzaki, I., Goto, K., & Sakurai, T. (1999). Orexins/hypocretins regulate drinking behaviour. *Brain Research*, 842, 256–261.
- Kuru, M., Ueta, Y., Serino, R., Nakazato, M., Yamamoto, Y., Shibuya, I., & Yamashita, H. (2000). Centrally administered orexin/hypocretin activates HPA axis in rats. *NeuroReport*, 11, 1977–1980.
- de Lecea, L., Kilduff, T. S., Peyron, C., Gao, X., Foye, P. E., Danielson, P. E., ... Sutcliffe, J. G. (1998). The hypocretins: Hypothalamus-specific peptides with neuroexcitatory activity. *Proceedings of the National Academy of Sciences*, 6, 322–327.
- Liguori, G., Assisi, L., Squillaciotti, C., Paino, S., Mirabella, N., & Vittoria, A. (2012). Presence, distribution and steroidogenic effect of the peptides orexin A and receptor 1 for orexins in the testis of the South America camelid alpaca (*Vicugna pacos*). *General and Comparative Endocrinology*, 179, 137–142.
- Liguori, G., Paino, S., Mirabella, N., Squillaciotti, C., De Luca, A., & Vittoria, A. (2014). Expression of orexin A and its receptor 1 in the epididymis of the South American camelid alpaca (*Vicugna pacos*). *Anatomia Histologia and Embryologia*, 43, 42–47.
- Liguori, G., Paino, S., Squillaciotti, C., De Luca, A., Ali, S., Langella, E., & Mirabella, N. (2013). Innervation and immunohistochemical characteristics of epididymis in alpaca (*Vicugna pacos*). *Italian Journal of Animal Science*, 12, 88–94.
- Liguori, G., Pavone, L. M., Assisi, L., Langella, E., Tafuri, S., Mirabella, N., ... Vittoria, A. (2017). Expression of orexin B and its receptor 2 in rat testis. *General and Comparative Endocrinology*, 242, 66–73.
- Malendowicz, W., Szyszka, M., Ziolkowska, A., Rucinski, M., & Kwias, Z. (2011). Elevated expression of orexin receptor 2 (HCRT2) in benign prostatic hyperplasia is accompanied by lowered serum orexin

- A concentrations. *International Journal of Molecular Medicine*, 27, 377–383.
- Malendowicz, L. K., Tortorella, C., & Nussdorfer, G. G. (1999). Orexins stimulate corticosterone secretion of rat adrenocortical cells, through the activation of the adenylate cyclase-dependent signaling cascade. *Journal of Steroid Biochemistry and Molecular Biology*, 70, 185–188.
- Martyńska, L., Polkowska, J., Wolińska-Witort, E., Chmielowska, M., Wasilewska-Dziubińska, E., Bik, W., & Baranowska, B. (2006). Orexin A and its role in the regulation of the hypothalamo-pituitary axes in the rat. *Reproductive Biology*, 6, 29–35.
- Mitsuma, T., Hirooka, Y., Kayma, M., Mori, Y., Yokoi, Y., Izumi, M., ... Nogimori, T. (2000). Radioimmunoassay for hypocretin-2. *Endocrine Regulations*, 34, 23–27.
- Muschamp, J. W., Dominguez, J. M., Sato, S. M., Shen, R. Y., & Hull, E. M. (2007). A role for hypocretin (orexin) in male sexual behavior. *Journal of Neuroscience*, 27, 2837–2845.
- Nanmoku, T., Isobe, K., Sakurai, T., Yamanaka, A., Takekoshi, K., Kawakami, Y., ... Nakai, T. (2002). Effects of orexin on cultured porcine adrenal medullary and cortex cells. *Regulatory Peptides*, 104, 125–130.
- Ohkubo, T., Tsukada, A., & Shamoto, K. (2003). cDNA cloning of chicken orexin receptor and tissue distribution: Sexually dimorphic expression in chicken gonads. *Journal of Molecular Endocrinology*, 31, 499–508.
- Pavone, L. M., Tafuri, S., Avallone, L., Staiano, N., & Vittoria, A. (2009). Expression of orexin A and its receptor 1 in the vestibular glands of the cattle genital tract. *Anatomical Record*, 292, 202–206.
- Ramanjaneya, M., Conner, A. C., Chen, J., Kumar, P., Brown, J. E., Jöhren, O., ... Randeve, H. S. (2009). Orexin-stimulated MAP kinase cascades are activated through multiple G-protein signalling pathways in human H295R adrenocortical cells: Diverse roles for orexins A and B. *Journal of Endocrinology*, 202, 249–261.
- Russo, F., Pavone, L. M., Tafuri, S., Avallone, L., Staiano, N., & Vittoria, A. (2008). Expression of orexin A and its receptor 1 in the bovine urethroprostatic complex. *Anatomical Record*, 291, 169–174.
- Sakurai, T., Amemiya, A., Ishii, M., Matsuzaki, I., Chemelli, R. M., Tanaka, H., ... Yanagisawa, M. (1998). Orexins and orexin receptors: A family of hypothalamic neuropeptides and G protein-coupled receptors that regulate feeding behaviour. *Cell*, 92, 573–585.
- Schwalm, A., Gauly, M., Erhardt, G., & Bergmann, M. (2007). Changes in testicular histology and sperm quality in llamas (*Lama glama*), following exposure to high ambient temperature. *Theriogenology*, 67, 1316–1323.
- Shirasaka, T., Nakazato, M., Matsukura, S., Takasaki, M., & Kannan, H. (1999). Sympathetic and cardiovascular actions of orexins in conscious rats. *American Journal of Physiology*, 277, R1780–R1785.
- Squillaciotti, C., De Luca, A., Ali, S., Paino, S., Liguori, G., & Mirabella, N. (2012). Expression of urocortin and corticotropin-releasing hormone receptors in the horse thyroid gland. *Cell and Tissue Research*, 350, 45–53.
- Squillaciotti, C., De Luca, A., Paino, S., Langella, E., & Mirabella, N. (2009). Effects of castration on the expression of the NGF and TrkA in the vas deferens and accessory male genital glands of the rat. *European Journal of Histochemistry*, 53, 239–248.
- Tafuri, S., Lo Muto, R., Pavone, L. M., Valiante, S., Costagliola, A., Staiano, N., & Vittoria, A. (2010). Novel localization of orexin A in the tubular cytotypes of the rat testis. *Regulatory Peptides*, 164, 53–57.
- Tafuri, S., Pavone, L. M., Lo Muto, R., Basile, M., Langella, E., Fiorillo, E., ... Vittoria, A. (2009). Expression of orexin A and its receptor 1 in the rat epididymis. *Regulatory Peptides*, 5, 1–5.
- Taheri, S., Ward, H., Ghatei, M., & Bloom, S. (2000). Role of orexins in sleep and arousal mechanisms. *Lancet*, 355, 847.
- Teixeira, J., Fynn-Thompson, E., Payne, A. H., & Donahoe, P. K. (1999). Mullerian-inhibiting substance regulates androgen synthesis at the transcriptional level. *Endocrinology*, 140, 4732–4738.
- Tibary, A., & Vaughan, J. (2006). Reproductive physiology and infertility in male South American camelids: A review and clinical observations. *Small Ruminant Research*, 61, 283–298.
- Valiante, S., Liguori, G., Tafuri, S., Campese, R., Monaco, R., Paino, S., ... Vittoria, A. (2013). Expression of orexin A and its receptor 1 in the human prostate. *Journal of Anatomy*, 222, 473–480.
- Valiante, S., Liguori, G., Tafuri, S., Pavone, L. M., Campese, R., Monaco, R., ... Vittoria, A. (2015). Expression and potential role of the peptide orexin-A in prostate cancer. *Biochemical and Biophysical Research Communications*, 464, 1290–1296.
- Voisin, T., Rouet-Benzineb, P., Reuter, N., & Laburthe, M. (2003). Orexins and their receptors: Structural aspects and role in peripheral tissues. *Cellular and Molecular Life Sciences*, 60, 72–87.
- Zhang, S., Blache, D., Vercoe, P. E., Adam, C. L., Blackberry, M. A., Findlay, P. A., ... Martin, G. B. (2005). Expression of orexin receptors in the brain and peripheral tissues of the male sheep. *Regulatory Peptides*, 124, 81–87.
- Zheng, D., Zhao, Y., Shen, Y., Chang, X., Ju, S., & Guo, L. (2014). Orexin A-mediated stimulation of 3 $\beta$ -HSD expression and testosterone production through MAPK signaling pathways in primary rat Leydig cells. *Journal of Endocrinological Investigation*, 37, 285–292.

**How to cite this article:** Liguori G, Squillaciotti C, Assisi L, et al. Localization of orexin B and receptor 2 for orexins in testicular cytotypes of the camelid alpaca (*Vicugna pacos*). *Reprod Dom Anim*. 2017;00:1–7.