

Endovascular treatment of spontaneous isolated abdominal aortic dissection

Anna Maria Giribono¹, Doriana Ferrara¹, Flavia Spalla¹,
Donatella Narese², Umberto Bracale³, Felice Pecoraro⁴,
Renata Bracale⁵, Luca del Guercio¹ and Umberto
Marcello Bracale¹

Acta Radiologica Open
5(12) 1–5
© The Foundation Acta Radiologica
2016
Reprints and permissions:
sagepub.co.uk/journalsPermissions.nav
DOI: 10.1177/2058460116681042
arr.sagepub.com



Abstract

Isolated abdominal aortic dissection is a rare clinical disease representing only 1.3% of all dissections. There are a few case series reported in the literature. The causes of this pathology can be spontaneous, iatrogenic, or traumatic. Most patients are asymptomatic and symptoms are usually abdominal or back pain, while claudication and lower limb ischemia are rare. Surgical and endovascular treatment are two valid options with acceptable results. We herein describe nine cases of symptomatic spontaneous isolated abdominal aortic dissection, out of which four successfully were treated with an endovascular approach between July 2003 and July 2013. All patients were men, smokers, symptomatic (either abdominal or back pain or lower limb ischemia), with a history of high blood pressure, with a medical history negative for concomitant aneurysmatic dilatation or previous endovascular intervention. Diagnosis of isolated abdominal aortic dissection were established by contrast-enhanced computed tomography angiography (CTA) of the thoracic and abdominal aorta. All nine patients initially underwent medical treatment. In four symptomatic cases, non-responsive to medical therapy, bare-metal stents or stent grafts were successfully positioned. All patients completed a CTA follow-up of at least 12 months, during which they remained symptom-free. Endovascular management of this condition is associated with a high rate of technical success and a low mortality; therefore, it can be considered the treatment of choice when it is feasible.

Keywords

Abdominal aorta, dissection, endovascular technique, stents, stent grafts

Date received: 10 June 2016; accepted: 1 November 2016

Introduction

Isolated abdominal aortic dissection (IAAD) is rare, usually limited to the infrarenal aorta. The causes of IAAD may be spontaneous, traumatic, or iatrogenic. Most patients with this pathology are male, with a median age of 60 years, and usually with concomitant high blood pressure (1). Co-existing abdominal aortic aneurysm and penetrating aortic ulcers are frequently associated. The clinical presentation of the disease may be acute, with an abrupt onset of symptoms, or chronic presenting ≥ 14 days of symptom onset. Natural history and therapeutic options of IAAD are not well known; its low incidence in the literature is based mainly on case reports and few case series. The most common symptom is abdominal or back pain, while claudication and lower limb ischemia are rare (1,2). Therapeutic strategies are conservative in the asymptomatic form

with a non-dilated aorta, while open or endovascular repair are the treatment of choice in the symptomatic cases. This decision is greatly influenced by anatomical conditions along with the surgeon's experience. In this report we describe our experience on four patients with

¹Department of Vascular and Endovascular Surgery University Federico II of Naples, Naples, Italy

²Department of Radiology, DIBIMEF, University of Palermo, Palermo, Italy

³Department of General Surgery, University Federico II of Naples, Naples, Italy

⁴Vascular Surgery Unity, University of Palermo, Palermo, Italy

⁵Department of Medicine and Health Science, University of Molise, Campobasso, Italy

Corresponding author:

Umberto Marcello Bracale, Department of Vascular and Endovascular Surgery, University Federico II of Naples, Naples, Italy.
Email: umbertomarcello.bracale@unina.it



spontaneous IAAD who presented at our institution and were treated by endovascular repair during a time period of 10 years.

Case reports

Between July 2003 and July 2013, nine patients (7 men, 2 women; median age, 67 years; age range, 46–77 years) were referred to our institution presenting with an IAAD. All patients were smokers with high blood pressure. Two patients were asymptomatic, while all the remaining patients were symptomatic. Two had abdominal pain responsive to medical treatment, three abdominal and unremitting pain non-responding to analgesic and anti-hypertensive therapy, and, in two of these, a bilateral buttock claudication was observed. Another patient presented with right lower limb ischemia with necrotic lesions of the first toe. One patient had a past medical history of myocardial infarction and another of chronic myeloproliferative syndrome. None had a history of trauma or previous endovascular intervention. Physical examination of the abdomen was unremarkable. Contrast-enhanced computed tomography angiography (CTA) of the thoracic and abdominal aorta was performed in all cases and the dissected flap of the infrarenal abdominal aorta with the classic appearance of “double-barreled” lumen was revealed.

No evidence of concomitant thoracic aorta dissection or abdominal aortic dilatation was detected.

All dissections were confined to the abdominal aorta between the renal arteries and the inferior mesenteric artery without retrograde extension to the thoracic aorta. The mean dissection length was 85 mm (range, 64–114 mm). In three cases the dissection was limited to the abdominal aorta, in another one the aortic dissection extended into the left common iliac artery with a contralateral iliac occlusive disease (3) and in five another cases the dissection involved both iliac arteries. Five patients (two asymptomatic and three symptomatic with abdominal pain) were treated medically and put under surveillance; none of them have so far developed either an abdominal aortic aneurysm or an extension of dissection. Four patients were treated endovascularly under spinal anesthesia; in the operating room the common femoral arteries (CFAs) were surgically exposed (two had bilateral cutdown). One patient was treated with a 23 × 14 mm Excluder bifurcated stent graft (W.L. GORE & Associates, Flagstaff, AZ, USA) (Fig. 1a–c). In one case, a Talent bifurcated (aortouniiliac) endograft (Medtronic Vascular, Santa Rosa, CA, USA) was positioned through the left CFA. Because the contralateral iliac artery was not suitable for iliac limb deployment, an occluding covered stent was then positioned, and a 8-mm ePTFE

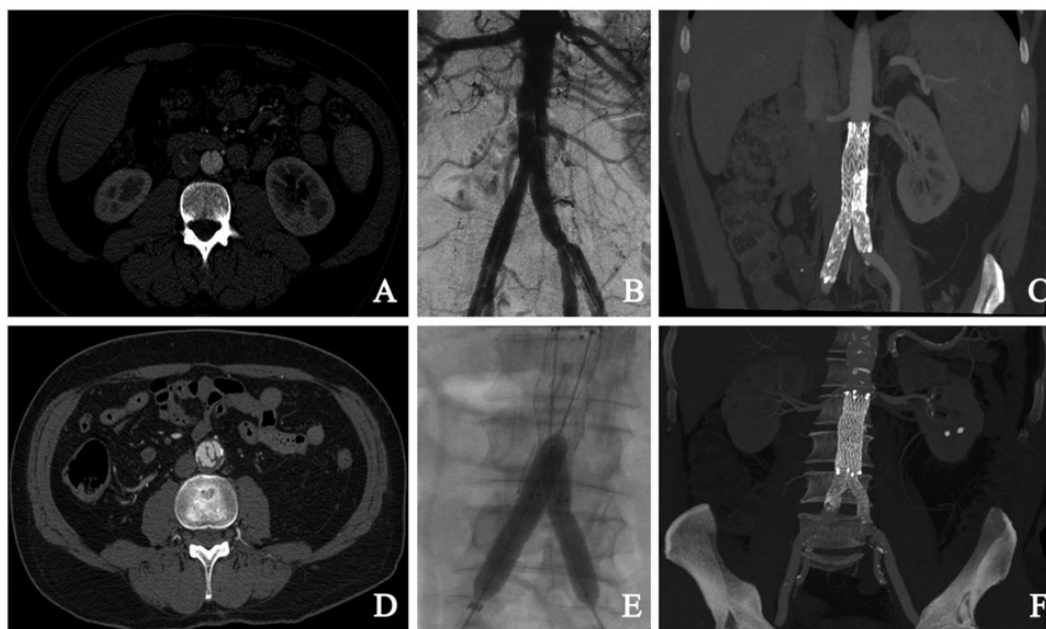


Fig. 1. Preoperative CTA showing “double-barreled” appearance of the abdominal aorta (a). Completion angiogram after bifurcated stent graft deployment (b). CTA 8 years after treatment showing good placement of the stent graft without any recurrence (c). CT scan axial image showing abdominal aortic dissection involving to iliac arteries (d). Intraoperative digital subtraction angiography demonstrating good placement of aortic and kissing bare metal stents (e). Postoperative CT scan showing good patency of aortic and iliac stents and complete disappearance of false lumen (f).

femoro-femoral bypass grafting was performed (3). The two remaining patients received a 20 mm (Fig. 1e–g) and 24 mm E-XL Jotec aortic stents (JOTEC, Hechingen, Germany), respectively. Both bare self-expandable stents were positioned below the renal arteries and, thereafter, a kissing stent of the aortic bifurcation was performed by using balloon-expandable stents (Express LD, Boston Scientific, Natick, MA, USA) (two 10 × 37 mm in one case and two 9 × 57 mm in the second). All patients had an uneventful postoperative course and, at the time of discharge, all were asymptomatic with peripheral pulses palpable bilaterally. Postoperative control was performed by CTA after 1 month and duplex ultrasound after 3, 6, and 12 months. Postoperative CTA showed full aortic remodelling in all cases and at 12 months all patients remained symptom-free. None of the patients developed over-time dilatation of the aorta or the iliac arteries above and below the treated segment. After the 12-month CTA, all patients underwent follow-up with duplex ultrasound and clinical examination. Patients' data, clinical symptoms, treatment and outcome are summarized in Table 1.

Discussion

Aortic dissection involving only the abdominal aorta is a rare clinical entity. Trimarchi et al., among 1417 patients enrolled in the IRAD registry from 1996 to 2003, found IAAD in only 1.3% of all dissections (1,4). Aortic rupture in IAAD patients occurs in about 15% of the patients (1,2,5) with mortality in the range of 17–28% (2,4–6). Asymptomatic patients with normal diameter of the aorta are usually treated conservatively. Vermeersch et al. reported 5 cases of asymptomatic IAAD treated conservatively with blood pressure control and strict follow-up. During the follow-up period, all patients remained symptom-free and the dissection length remained stable (7). Endovascular or surgical interventions are suggested in all patients with dissection and concomitant aortic aneurysm (aortic diameter exceeding 3 cm), or in patients with signs of aortic rupture, ischemic symptoms, and unremitting pain in a non-dilated aorta (5,6,8). The patients who referred to our institute were affected by symptomatic isolated abdominal dissection in absence of thoracic aortic involvement and aneurysmatic dilatation of the abdominal aorta.

All patients initially underwent best medical treatment including analgesic and anti-hypertensive therapy. The patients responding to medical therapy were subjected to surveillance, while in all other cases endovascular treatment was chosen.

Conventional surgical repair has been the mainstay of treatment with good long-term results especially in

patients with low operative risk. Both open and endovascular therapy show acceptable results, but in-hospital mortality for aortic dissection is 25–30% for open surgery compared to 10% for endovascular repair (1). Reported outcomes after endovascular treatment of IAAD are notable for a 30-day mortality of 0% and no major adverse events during hospital stay (9). The deployment of covered or bare metal stents is a safe and effective procedure to obliterate the dissected flap, induce thrombosis of the false lumen and restore blood flow in the true lumen. Nowadays, there are no commercially available devices specifically designed for closing IAAD along with no clear indications for the use of specific types of endovascular devices. In the absence of relevant thrombus formation in the true lumen, the risk of peripheral embolization is low; therefore the use of uncovered metal stents can be considered as a first and cheaper choice to ensure perfusion of collateral pathways and lumbar arteries. On the other hand, in case of risk for peripheral embolization or a co-existing abdominal aortic aneurysm, the use of stent grafts is recommended (9). A variety of bifurcated and aortouniiliac stent grafts can be used depending on morphology and diameters of interested vessels. This treatment avoids aortic cross-clamping and suturing in a highly friable aortic wall (8). Promising results appear in aortic remodeling obtained with endovascular repair; the complete thrombosis of the false lumen can be achieved in 91.3% of stent grafts (10). Furthermore, in the long term this therapeutic option prevents aortic rupture, progression of dissection, and formation of a subsequent aneurysm. The main anatomical limitation for endovascular repair with stent graft is the relatively small diameter of a non-aneurysmatic infrarenal aorta and aortic bifurcation (11), a problem that sometimes can be overcome by using aortouniiliac device (3). When considering the use of bare metal stents, balloon-expandable stents have a precise deployment and present a higher radial strength, highly indicated for very calcified vessels. Self-expandable stents, on the contrary, have higher flexibility and longer lengths. In our clinical experience two patients were successfully treated with an E-XL Jotec aortic self-expandable stent. The use of bare stent in the aorta for closure of the entry in IAAD must be critically discussed, even when a good result with complete thrombosis and shrinkage of the false lumen can be obtained (12).

From a technical point of view, the risks during endovascular treatment include: possibility of further aortic damage while advancing the guide-wire, with increase in the false lumen and wrong deployment (2). The use of intravascular ultrasound (IVUS) is helpful when positioning and advancing the guide-wire into the true lumen (13). Moreover, IVUS may be useful also

Table 1. Medical history, clinical presentation, treatment, and outcome of the patients.

Patient no.	Sex/age	Smok	Arterial hypertension	Renal failure	Myocardial infarction	Clinical presentation	Dissection length (mm)	Abdominal aorta diameter (mm)	Extension CIA	Treatment	Follow-up (months)	Outcome at latest follow-up
1	M/71	Yes	Yes	No	Yes	Abdominal and back pain	114	20.6	Yes	AUI + femoro-femoral bypass	123	Alive
2	M/46	Yes	Yes	No	No	Lower limb ischaemia with necrotic lesions of the first toe of right foot	64	20	No	Bifurcated stent graft	100	Alive
3	F/66	Yes	Yes	No	No	Abdominal pain	103	22.2	Yes	Medical therapy/surveillance	92	Alive
4	M/72	Yes	Yes	No	No	Asymptomatic presentation	66.2	20.6	No	Medical therapy/surveillance	112	Alive
5	M/68	Yes	Yes	No	No	Asymptomatic presentation	89	21	Yes	Medical therapy/surveillance	64	Alive
6	M/68	Yes	Yes	No	No	Abdominal pain	91.3	23	Yes	Medical therapy/surveillance	86	Alive
7	F/69	Yes	Yes	No	No	Abdominal pain	65.2	21.3	No	Medical therapy/surveillance	35	Alive
8	M/67	Yes	Yes	No	No	Buttock claudication with sudden abdominal pain	85	19.2	Yes	Aortic and iliac stenting	41	Alive
9	M/77	Yes	Yes	No	No	Buttock claudication with sudden abdominal pain	87.5	18.8	Yes	Aortic and iliac stenting	29	Alive

AUI, aortouniliac; CIA, common iliac arteries.

for precise measurement of vessel diameter and accurate identification of the dissection's limits.

In conclusion, despite the limited number of patients treated, our experience suggests that, compared to open surgery, endovascular management represents a feasible, safe, and minimally invasive approach with a low rate of complications, mortality, and secondary interventions. When the patient's anatomy allows, this is the treatment of choice. The long-term outcome data suggest that endovascular repair is a durable treatment option. Both bare stents and stent grafts showed promising results in the induction of the thrombosis of the false lumen and aortic remodeling.

Declaration of conflicting interests

The author(s) declared no potential conflicts of interest with respect to the research, authorship, and/or publication of this article.

Funding

The author(s) received no financial support for the research, authorship, and/or publication of this article.

References

1. Jonker FH, Schlösser FJ, Moll FL, et al. Dissection of the abdominal aorta. Current evidence and implications for treatment strategies: a review and meta-analysis of 92 patients. *J Endovasc Ther* 2009;16:71–80.
2. Handa N, Nishina T, Kato M, et al. Endovascular stent-graft repair for spontaneous dissection of infra-renal abdominal aorta. *Ann Vasc Surg* 2010;24:955.e1–4.
3. Porcellini M, Mainenti P, Bracale UM. Endograft repair of spontaneous infrarenal abdominal aortic dissection. *J Vasc Surg* 2005;41:155.
4. Trimarchi S, Tsai T, Eagle KA, et al. Acute abdominal aortic dissection: insight from the International Registry of Acute Aortic Dissection (IRAD). International Registry of Acute Aortic Dissection (IRAD) investigators. *J Vasc Surg* 2007;46:913–919.
5. Mantelas M, Antonitsis P, Kaitzis D, et al. Spontaneous isolated dissection of the abdominal aorta: single-center experience. *Interact Cardiovasc Thorac Surg* 2009;8:398–401.
6. Farber A, Lauterbach SR, Wagner WH, et al. Spontaneous infrarenal abdominal aortic dissection presenting as claudication: case report and review of the literature. *Ann Vasc Surg* 2004;18:4–10.
7. Vermeersch N, Hendriks JM, Lauwers P, et al. Aortic dissection limited to abdominal aorta: an underrecognized entity? *Acta Chir Belg* 2015;115:293–298.
8. Kouvelos GN, Vourliotakis G, Arnaoutoglou E, et al. Endovascular treatment for isolated acute abdominal aortic dissection. *J Vasc Surg* 2013;58:1505–1511.
9. Jawadi N, Bisdas T, Torsello G, et al. Endovascular treatment of isolated abdominal aortic dissections: Long-term results. *J Endovasc Ther* 2014;21:324–328.
10. Zhu QQ, Li DL, Lai MC, et al. Endovascular treatment of isolated abdominal aortic dissection and postoperative aortic remodeling. *J Vasc Surg* 2015;61:1424–1431.
11. Adam DJ, Roy-Choudhury S, Bradbury AW, et al. Endovascular repair of spontaneous infrarenal aortic dissection presenting as severe lower extremity ischemia. *Eur J Vasc Endovasc Surg* 2007;34:699–701.
12. Böckler D, Bianchini Massoni C, Geisbüsch P, et al. Single-center experience in the management of spontaneous isolated abdominal aortic dissection. *Langenbecks Arch Surg* 2016;401:249–254.
13. Giudice R, Frezzotti A, Scoccianti M. Intravascular ultrasound-guided stenting for chronic abdominal aortic dissection. *J Endovasc Ther* 2002;9:926–931.