

The occurrence and pathogenicity of *Serratospiculum tendo* (Nematoda: Diplotriaenoidea) in birds of prey from southern Italy

M. Santoro^{1*}, N. D'Alessio², F. Di Prisco², J.M. Kinsella³, L. Barca²,
B. Degli Uberti², B. Restucci⁴, M. Martano⁴, S. Troisi⁵, G. Galiero²
and V. Veneziano⁴

¹Department of Public Health and Infectious Diseases, Section of Parasitology, 'Sapienza - University of Rome', P. le Aldo Moro n. 5, 00185 Rome, Italy: ²Istituto Zooprofilattico Sperimentale del Mezzogiorno, Via Salute n. 2, Portici, Italy: ³Helm West Laboratory, 2108 Hilda Avenue, Missoula, Montana 59801, USA: ⁴Department of Veterinary Medicine and Animal Production, University of Naples Federico II, Naples, Italy: ⁵Istituto Di Gestione Della Fauna – Onlus (IGF), Via Mezzocannone n. 8, 80134 Naples, Italy

(Received 29 October 2014; Accepted 28 January 2015)

Abstract

The air sacs of free-ranging birds of prey ($n = 652$) from southern Italy, including 11 species of Accipitriformes and six of Falconiforms, were examined for infections with *Serratospiculum tendo* (Nematoda: Diplotriaenoidea). Of the 17 species of birds examined, 25 of 31 (80.6%) peregrine falcons (*Falco peregrinus*) from Calabria Region and a single northern goshawk (*Accipiter gentilis*) from Campania Region were infected with *S. tendo*, suggesting a strong host specificity for the peregrine falcon. The northern goshawk and 18 of 25 infected peregrine falcons showed cachexia and all infected birds had bone fractures. At gross examination, air sacculitis and pneumonia were the most common lesions in infected birds. Microscopically, the air-sac walls showed thickening of the smooth muscle cells, resulting in a papillary appearance, along with hyperplasia of the mesothelium and epithelium, and foci of plasma cell infiltration and macrophages associated with several embryonated eggs and adult parasites. Extensive areas of inflammation were found in the lungs, characterized by lymphocytes, macrophages and fibroblasts surrounding embryonated eggs. The northern goshawk also had detachment of the dextral lung with several necrotic foci. In this case, the death of the bird was directly attributed to *S. tendo* infection. Lesions and pathological changes observed here suggest that *S. tendo* can cause disease.

Introduction

Diplostriaenoid nematodes of the genus *Serratospiculum* include nine species parasitizing birds. Of these, at least eight are parasites of birds of prey, mainly of the genus *Falco*. *Serratospiculum tendo*, described as *Filaria tendo* Nitzsch 1857 from *Falco communis* (syn. *Falco tinnunculus*) in Russia, and later included in *Serratospiculum* by Skrjabin (1916), is the main species in the genus found in European birds of prey (Furmaga, 1957; Krone, 2000, 2002; Santoro *et al.*, 2012a, b; Natural History Museum, 2014).

The life cycle of *S. tendo* has only been studied under laboratory conditions. Specimens of *Geotrupes sylvaticus* (Coleoptera), *Locusta migratoria* (Orthoptera) and *Periplaneta americana* (Blattodea) were infected experimentally by feeding *S. tendo* eggs obtained from peregrine falcons (*Falco peregrinus*). Larvae were found only in *G. sylvaticus* and *L. migratoria* 6, 12 and 48 days post-infection (Bain & Vassiliades, 1969). In *Serratospiculum seurati*, a common species infecting captive falcons from the Middle East, at least six species of beetles and one isopod serve as intermediate hosts (Samour & Naldo, 2001). Adult worms deposit their eggs within air sacs, then embryonated eggs are coughed up and swallowed, and find their way out with faeces or in regurgitated pellets. When the eggs are ingested by insects, larvae hatch and develop to the third infective stages, which are encapsulated in the body fat. Captive falcons are infected by feeding on insects present inside their paddock (Bain & Vassiliades, 1969; Samour & Naldo, 2001), but the parasite life cycle in free-ranging falcons is speculative and, to date, remains unelucidated.

Reports on occurrence and pathological changes associated with *S. tendo* in Europe are scarce; however, they indicate a high prevalence of infection and pathogenicity (Furmaga, 1957; Krone, 2000, 2002; Kalisinska *et al.*, 2008; Santoro *et al.*, 2010, 2012a, b). Here we performed a survey on a large sample of birds of prey from southern Italy, including 11 species of Accipitriformes and six of Falconiforms to investigate features of *S. tendo* infection, including host specificity and pathological changes.

Materials and methods

A total of 652 free-ranging birds of prey, belonging to 11 species of Accipitriformes and six of Falconiforms that

died between January 1998 and August 2014 in Wildlife Rescue Centres (WRC) from the Calabria and Campania Regions of southern Italy, were examined for nematodes of the respiratory tract. The studied birds included 3 *Accipiter gentilis*, 55 *A. nisus*, 358 *Buteo buteo*, 18 *Circus aeruginosus*, 1 *C. cyaneus*, 1 *C. macrourus*, 1 *C. pygargus*, 1 *Hieraaetus pennatus*, 4 *Milvus milvus*, 3 *M. migrans*, 30 *Pernis apivorus*, 1 *Falco columbarius*, 6 *F. naumanni*, 33 *F. peregrinus*, 6 *F. subbuteo*, 127 *F. tinnunculus* and 4 *F. vespertinus*. During necropsy, the trachea, bronchi, lungs and air sacs were examined carefully under a dissecting microscope and nematodes were collected, counted and fixed in 70% ethanol. Worms were cleared in lactophenol on a glass slide for identification and then returned to the preservative. Voucher specimens from *A. gentilis* and *F. peregrinus* were deposited in the Natural History Museum, London, UK (accession number: NHMUK 2015.1.15.1) and the US National Parasite Collection, Smithsonian Institution, Washington, DC (accession number: USNPC 104802), respectively. In peregrine falcons, differences in prevalence between age classes and gender were assessed by the two-sided chi-squared test. A *P* value < 0.05 was regarded as statistically significant. Impression smears from the respiratory tract of all studied birds were examined microscopically for *S. tendo* eggs. Tissue samples from infected birds were fixed in 10% neutral buffered formalin, embedded in paraffin, sectioned at 3 µm, and stained with haematoxylin and eosin. All birds included in the present study died within 7 days after admission to rescue centres (Krone, 2000; Santoro *et al.*, 2010, 2012a, b).

Results

Serratospiculum tendo was found in the thoracic and abdominal air sacs of 25 of the 31 (80.6%) peregrine falcons from the Calabria Region. In three cases, adult nematodes were also found in the lungs. No significant differences were found between age classes and/or gender groups. The mean intensity of infection was 8.7, ranging from 1 to 35. The male to female ratio for *Serratospiculum* specimens was 1.2:1. A single northern goshawk from the Campania Region was infected with 17 specimens of *S. tendo* in its thoracic air sacs (fig. 1A).

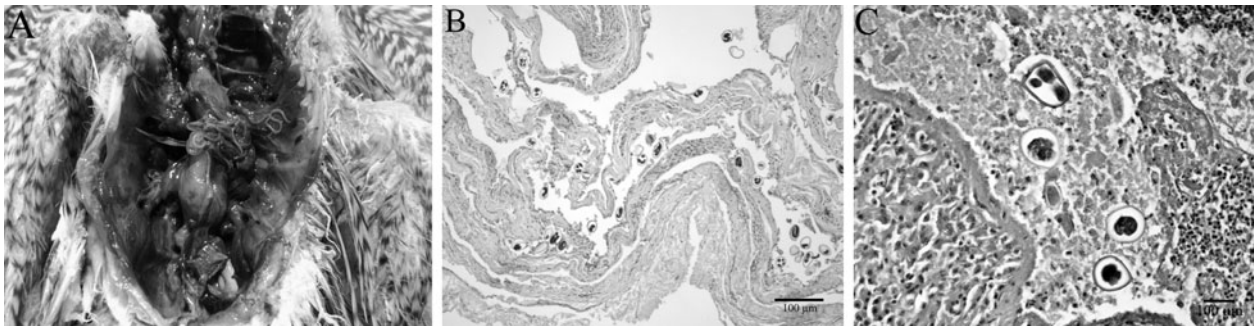


Fig. 1. (A) *Serratospiculum tendo* from the air sacs of *Accipiter gentilis*. (B) Section of a lung of *A. gentilis*, showing many embryonated eggs of *S. tendo*. (C) Section of the liver of *A. gentilis*, showing embryonated eggs of *S. tendo* surrounded by fibrinous exudates and lymphocytes on the outer surface.

The northern goshawk and 18 of 25 infected peregrine falcons showed cachexia, and all infected birds had bone fractures. At gross examination, air sacculitis and pneumonia were the most common lesions. The northern goshawk also showed a detachment of the dextral lung, showing several necrotic foci. Microscopically, impression smears from the respiratory tract of infected birds were all positive for embryonated eggs. Histologically, the air-sac walls of infected birds showed a thickening of the smooth muscle cells, resulting in a papillary appearance. There was hyperplasia of the mesothelium and epithelium, with foci of plasma cell infiltration and macrophages associated with several embryonated eggs (fig. 1B) and adult parasites. In the northern goshawk, the lungs showed extensive areas of inflammation characterized by lymphocytes, macrophages and fibroblasts surrounding necrotic foci associated with embryonated eggs, and the pulmonary interstitium appeared thickened. The liver capsule had several embryonated eggs surrounded by fibrinous exudates with many macrophages and lymphocytes (fig. 1C). In this latter case the death of the bird was directly linked to *S. tendo* infection.

Discussion

Birds of prey from southern Italy were studied for helminths by Santoro *et al.* (2012a, b). Diplotrienoid nematodes were assigned to the genus *Serratospiculum* based on the genus-specific features described by Anderson *et al.* (2009), and species-specific features of the male spicules described by Bain & Vassiliades (1969) and Bain & Mawson (1981). In Europe, three *Serratospiculum* spp. have been reported, including *S. guttatum* and *S. chungii*, both from Spain, and *S. tendo* from Britain, France, Germany, Italy, Poland, Russia, Spain and Tadzhikistan (Furmaga, 1957; Bain & Vassiliades, 1969; Illescas-Gomez *et al.*, 1993; Krone, 2000, 2002; Kalisinska *et al.*, 2008; Santoro *et al.*, 2012a, b; Natural History Museum, 2014). In addition the latter species has also been reported in *F. peregrinus* from Australia (Bain & Mawson, 1981) and Peru (Gomez-Puerta *et al.*, 2014). *Serratospiculum tendo* may be distinguished easily from *S. chungii* and *S. guttatum*, mainly by the longer length of the spicules (Bain & Vassiliades, 1969; Bain & Mawson, 1981). Recently, Königová *et al.* (2013) reported *Serratospiculum amaculata* in the great tit (*Parus major*) from Slovakia; however, this species is currently not considered a member of *Serratospiculum* but of *Serratospiculoides* (Sternler & Cole, 2008; Anderson *et al.*, 2009).

Recorded hosts for *S. tendo* include *F. peregrinus*, *F. cherrug*, *F. tinnunculus*, *F. biarmicus*, *F. mexicanus*, *F. cyaneus*, *F. zithofalco* (Falconiformes); *Milvus korschun* (syn. *M. migrans*) (Accipitriformes); and *Corvus frugilegus* and *Thamnophilus stagus* (Passeriformes) (Skrjabin, 1916; Furmaga, 1957; Krone, 2000, 2002; Santoro *et al.*, 2010, 2012b; Natural History Museum, 2014). Therefore, the northern goshawk represents a new host record for *S. tendo*.

Of the 17 birds of prey studied, 25 of 31 (80.6%) peregrine falcons from Calabria Region and a northern goshawk from Campania Region were infected by *S. tendo*. The small sample of northern goshawks examined from

Calabria ($n = 1$) and Campania ($n = 1$) is insufficient to draw definitive conclusions for this host in southern Italy. In contrast, the high prevalence of infection in the peregrine falcon suggests a strong host specificity for this parasite. Similarly, Krone (2000) identified *S. tendo* in 16 of 19 peregrine falcons in Germany. Since the free-ranging peregrine falcon is a specialized predator in open spaces, feeding almost exclusively on living birds of small to medium size, according to local availability (Ratcliffe, 2000), a different source of infection should be expected for *S. tendo* in free-ranging falcons, with respect to that reported for *S. seurati* in captive individuals (hosted in paddocks) feeding on insects. The present results from the free-ranging peregrine falcons strengthen the hypothesis proposed by Bain & Vassiliades (1969) and Krone & Cooper (2002) regarding the possible existence of avian transport hosts for *S. tendo* larvae. On the other hand, the main prey items of the northern goshawk are small birds and mammals found in forest habitats. An examination of a larger sample of northern goshawks is required to establish whether or not the *S. tendo* infection in this host is an isolated case.

Most of the morbidity and mortality by diplotrienoid nematodes has been described for *S. seurati* in captive birds of prey in the Middle East (Samour & Naldo, 2001; Tarello, 2006), and *Serratospiculoides amaculata* in free-ranging individuals in North America (Bigland *et al.*, 1964; Kocan & Gordon, 1976; Sternler & Espinosa, 1998; Sternler & Cole, 2008). Clinical signs included dyspnoea, reduced flight performance, weight loss, anorexia, lethargy, vomiting, closed eyes, pain and tremors. The most common pathological changes were thickening of air-sac membranes compromising air exchange, congestion, focal haemorrhages and focal necrosis of lungs, and bronchial oedema with secondary bacterial and mycotic infections causing death (Bigland *et al.*, 1964; Kocan & Gordon, 1976; Sternler & Espinosa, 1998; Samour & Naldo, 2001; Tarello, 2006; Sternler & Cole, 2008). Kalisinska *et al.* (2008) reported intestinal helminths such as digeneans and a cestode, an epidermal mycosis and a pulmonary bacterial infection in an emaciated peregrine falcon from Poland with an infection of *S. tendo* in the air sacs, but the death of the falcon was not linked to a specific cause. Unfortunately, in the present study, living birds of prey at the time of admission to the rescue centres showed no clinical signs of infection, but lesions recorded at post-mortem, together with the observed pathological changes, suggested that *S. tendo* may have caused disease.

In addition to direct effects induced by nematodes on tissues of their hosts, such infections may affect host body condition, and, in turn, flight performance and predatory effectiveness, together with a predisposition to secondary trauma (Bigland *et al.*, 1964; Kocan & Gordon, 1976; Samour & Naldo, 2001; Tarello, 2006; Sternler & Cole, 2008; Santoro *et al.*, 2010). For example, peregrine falcons catch their avian prey during spectacular flight performances (Ratcliffe, 2000) and non-optimal health condition may cause flying imbalance and accidental impacts. In this study, all *Serratospiculum*-infected birds of prey showed traumatic injuries, but whether *S. tendo* contributed to debilitation, and consequently secondary trauma, in these hosts is unknown.

Financial support

This study was funded by the Ministry of Health of Italy (IZS ME 06/10 RC).

Conflict of interest

None.

References

- Anderson, R.C., Chabaud, A.G. & Willmott, S.** (2009) *Keys to the nematode parasites of vertebrates*. 462 pp. Wallingford, CAB International.
- Bain, O. & Mawson, M.** (1981) Oviparous filarial nematodes mainly from Australian birds. *Records of the South Australian Museum (Adelaide)* **18**, 265–284.
- Bain, O. & Vassiliades, G.** (1969) Cycle évolutif d'un Dicheilonematinae, *Serratospiculum tendo*, filaire parasite du faucon. *Annales de Parasitologie* **44**, 595–604.
- Bigland, C.H., Lui, S.K. & Perry, M.L.** (1964) Five cases of *Serratospiculum amaculata* (Nematoda: Filarioidea) infection in prairie falcons (*Falco mexicanus*). *Avian Diseases* **8**, 412–419.
- Furmaga, S.** (1957) The helminth fauna of predatory birds (Accipitres and Striges) of the environment of Lublin. *Acta Parasitologica Polonica* **5**, 215–297.
- Gomez-Puerta, L.A., Ospina, P.A., Ramirez, M.G. & Cribillero, N.G.** (2014) First record of *Serratospiculum tendo* (Nematoda: Diplostriaenidae) in Peru. *Revista Peruana de Biología* **21**, 111–114.
- Illescas-Gomez, M.P., Rodríguez, M. & Aranda, F.** (1993) Parasitism of falconiform, strigiform and passeriform (Corvidae) birds by helminths in Spain. *Research and Review in Parasitology* **53**, 129–135.
- Kalisinska, E., Lisowski, P., Czernomysy-Furowicz, D. & Kavetska, K.M.** (2008) Serratospiculiasis, mycosis, and haemosiderosis in a wild peregrine falcon from Poland. A case report. *Bulletin of the Veterinary Institute in Pulawy* **52**, 75–79.
- Kocan, A. & Gordon, L.R.** (1976) Fatal air sac infection with *Serratospiculum amaculata* in a prairie falcon. *Journal of the American Veterinary Medical Association* **169**, 908.
- Königová, A., Molnár, L., Hřčková, G. & Várady, M.** (2013) The first report of serratospiculiasis in great tit (*Parus major*) in Slovakia. *Helminthologia* **50**, 254–260.
- Krone, O.** (2000) Endoparasites in free-ranging birds of prey in Germany. pp. 101–116 in Lumeij, J.T., Remple, J.D., Redig, P.T., Lierz, M. & Cooper, J.E. (Eds) *Raptor biomedicine III*. Lake Worth, Zoological Educational Network.
- Krone, O.** (2002) Die wechselbeziehungen zwischen dem wanderfalken und seinen endoparasiten. pp. 965–987 in Rockenbach, D. (Ed.) *Der wanderfalk in Deutschland und umliegenden gebieten*. Ludwingsburg, Verlag Ch. Holzinger.
- Krone, O. & Cooper, J.E.** (2002) Parasitic disease. pp. 105–120 in Cooper, J.E. (Ed.) *Birds of prey. Health and diseases*. 3rd edn. Iowa, Iowa State Press.
- Natural History Museum.** (2014) Host parasite database of the Natural History Museum, London, UK. Available at <http://www.nhm.ac.uk/research-curation/scientific-resources/taxonomy-systematics/host-parasites/database/index.jsp> (accessed 5 September 2014).
- Ratcliffe, D.** (2000) *The peregrine falcon*. 2nd edn. 454 pp. London, T. & A.D. Poyser.
- Samour, J.H. & Naldo, J.** (2001) Serratospiculiasis in captive falcons in the Middle East: A review. *Journal of Avian Medicine and Surgery* **15**, 2–9.
- Santoro, M., Tripepi, M., Kinsella, J.M., Panebianco, A. & Mattiucci, S.** (2010) Helminth infestation in birds of prey (Accipitriformes and Falconiformes) in southern Italy. *Veterinary Journal* **186**, 119–122.
- Santoro, M., Kinsella, J.M., Galiero, G., Degli Uberti, B. & Aznar, F.J.** (2012a) Helminth community structure in birds of prey (Accipitriformes and Falconiformes) in southern Italy. *Journal of Parasitology* **98**, 22–29.
- Santoro, M., Mattiucci, S., Nascetti, G., Kinsella, J.M., Di Prisco, F., Troisi, S., D'Alessio, N., Veneziano, V. & Aznar, F.J.** (2012b) Helminth communities of owls (Strigiformes) indicate strong biological and ecological differences from birds of prey (Accipitriformes and Falconiformes) in southern Italy. *Plos One* **7**, e53375.
- Skrjabin, K.I.** (1916) Nematodes des oiseaux du Turkestan russe. *Annuaire du Musée Zoologique de l'Académie Impériale des Sciences de Petrograd* **20**, 457.
- Sterner, M.C. & Cole, R.A.** (2008) *Diplostriaena*, *Serratospiculum* and *Serratospiculoides*. pp. 434–438 in Atkinson, C.T., Thomas, N.J. & Hunter, B. (Eds) *Parasitic diseases of wild birds*. Iowa, Wiley Blackwell.
- Sterner, M.C. & Espinosa, R.H.** (1998) *Serratospiculoides amaculata* in a Cooper's Hawk (*Accipiter cooperii*). *Journal of Wildlife Diseases* **24**, 378–379.
- Tarello, W.** (2006) Serratospiculosis in falcons from Kuwait: incidence, pathogenicity and treatment with melarsomine and ivermectin. *Parasite* **13**, 59–63.