

## Case Report

## Open Access

Massimo Mesoletta\*, Filippo Ricciardiello, Domenico Tafuri, Roberto Varriale, Domenico Testa

# Delayed recurrent nerve paralysis following post-traumatic aortic pseudoaneurysm

DOI 10.1515/med-2016-0041

received January 6, 2016; accepted March 7, 2016

**Abstract:** Blunt trauma to the neck or to the chest are increasingly observed in the emergency clinical practice. They usually follow motor vehicle accidents or may be work or sports related. A wide pattern of clinical presentation can be potentially encountered. We report the uncommon case of a patient who was referred to our observation presenting with hoarseness and dysphagia. Twenty days before he had sustained a car accident with trauma to the chest, neck and the mandible. Laryngoscopy showed a left recurrent laryngeal nerve palsy. Further otolaryngological examination showed no other abnormality. At CT and MR imaging a post-traumatic aortic pseudoaneurysm was revealed. The aortic pseudoaneurysm was consequently repaired by implantation of an endovascular stent graft under local anesthesia. The patient was discharged 10 days later. At 30-days follow-up laryngoscopy the left vocal cord palsy was completely resolved.

Hoarseness associated with a dilated left atrium in a patient with mitral valve stenosis was initially described by Ortner more than a century ago. Since then several non malignant, cardiovascular, intrathoracic disease that results in embarrassment from recurrent laryngeal nerve palsy usually by stretching, pulling or compression; thus, the correlations of these pathologies was termed as

cardiovascular syndrome or Ortner's syndrome. The reported case illustrates that life-threatening cardiovascular comorbidities can cause hoarseness and that an impaired recurrent laryngeal nerve might be correctable.

**Keywords:** Recurrent nerve paralysis, aortic pseudoaneurysm, Ortner's syndrome, cardiovascular syndrome

## 1 Introduction

Vocal cord paralysis is a common disease in the practice of otolaryngology. Many disease entities in the head, neck and thorax regions can cause recurrent laryngeal nerve paralysis, including ectopic dislocations, inflammatory, neoplastic, cerebrovascular, heart, degenerative and other conditions such as trauma [1-3]. Blunt trauma to the neck or to the chest are increasingly observed in the emergency clinical practice. They usually follow motor vehicle accidents, or may be a consequence of job or sport practice. A wide pattern of clinical presentation can be potentially encountered.

The recurrent paralysis of vocal cords is not only a disease entity but may also be a symptom of other disorders (central or peripheral pathologies, non-surgical or surgical paralysis etc). Patient with unilateral recurrent laryngeal nerve paralysis complain of hoarseness and occasional liquid aspiration. Ortner described hoarseness of voice to the left recurrent laryngeal nerve palsy in three patients with severe mitral stenosis [4]. Although it was initially associated with mitral stenosis, several other case reports suggested that hoarseness can be caused and associated by numerous cardiovascular pathologies [5,6]. In particular, these can be congenital conditions (atrial and ventricular septal defect, aortopulmonary window, double outlet right ventricle) [7-9], adult disorders (left atrial enlargement, left ventricular aneurysm, thrombosed giant left atrium [10], atrial myxoma [11], aortic aneurysms [12-14] or pseudoaneurysms [15]), iatrogenic lesions

**\*Corresponding author: Massimo Mesoletta**, Department of Neuroscience Reproductive and Dentistry Sciences, Otolaryngology Unit; University of Naples "Federico II", Naples - Italy. Via G. Filangieri 36, 80121 Napoli, Italy, E-mail address: massimo.mesoletta@tin.it

**Filippo Ricciardiello**, Department of Neuroscience Reproductive and Dentistry Sciences, Otolaryngology Unit; University of Naples "Federico II", Naples, Italy

**Domenico Tafuri**, Department of Sport Sciences and Wellness, University of Naples "Parthenope", Naples, Italy

**Roberto Varriale, Domenico Testa**, Department of Anesthesiologic, Surgical and Emergency Sciences; Otolaryngology, Head and Neck Surgery Unit; Second University of Naples, Italy

(cardiac surgery [16,17], thoracic surgery [18], atrial fibrillation ablation procedure [19]). The term “cardiovascular syndrome” was used in these cases [6,19].

We report the uncommon case of a patient who had undergone a chest and neck blunt trauma: after twenty days he presented with hoarseness and dysphonia. The left recurrent laryngeal nerve palsy secondary to a post-traumatic aortic pseudoaneurysm was revealed.

## 2 Case report

A 40-year old male, was referred to our observation presenting with hoarseness and dysphagia. Twenty days before he had sustained a car accident with trauma to the chest, the neck and the mandible. He had been submitted to a plain film of the chest, revealing the fractures of the 6th right rib, the 6th and 7th left ribs.

Fiber laryngoscopy showed an immobile left vocal cord in the paramedian position compatible with left recurrent laryngeal nerve paralysis. Further otolaryngological examination showed no abnormality. The laboratory findings were normal. In the potential suspect of an aortic injury, the patient underwent contrast material-enhanced spiral computer tomography (CT) of the chest. Moreover, because of its superior capability in depiction of functional information regarding flow patterns and luminal communications, MR imaging of the chest was also performed. At CT, MR and angiMR imaging a post-traumatic aortic pseudoaneurysm was revealed: concomitant compression of the left bronchus was shown as well (Fig. 1, 2). The aortic pseudoaneurysm was consequently repaired by implantation of an endovascular stent graft under local anesthesia. The patient was discharged

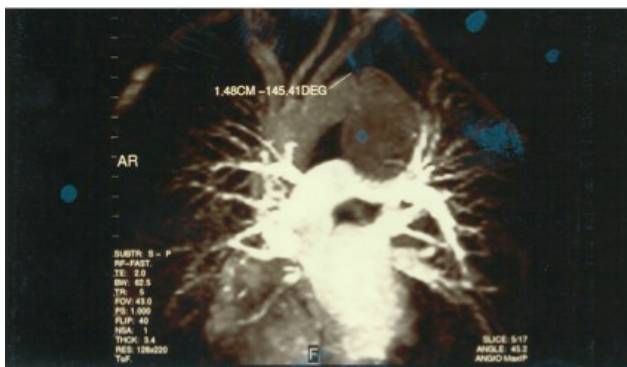10 days later, and at the 3-years follow-up visit the hoarseness and the dysphonia had resolved completely.

**Ethical approval:** The research related to human use has been complied with all the relevant national regulations, institutional policies and in accordance the tenets of the Helsinki Declaration, and has been approved by the authors’ institutional review board or equivalent committee.

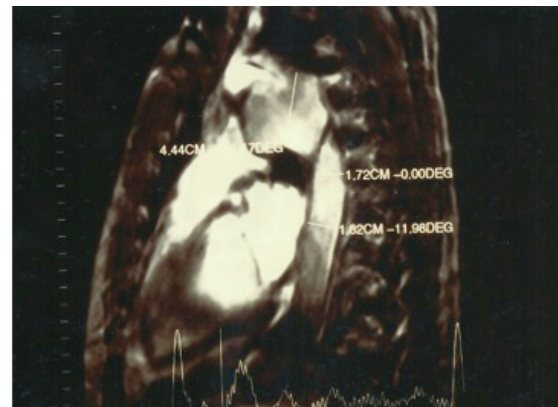
**Informed consent:** Informed consent has been obtained from all individuals included in this study.

## 3 Discussion

The association of vocal cord dysfunction with thoracic aortic aneurysm has been reported in the cardiovascular and otolaryngologic literature [4,5,6,8,21-23]. The recurrent laryngeal nerve in its course from the brain stem to the larynx follows a path that brings it in proximity to numerous structures. These structures can interfere with its function by pressure or by disruption of the nerve caused by disease invading the nerve. Indeed, a recurrent laryngeal nerve paralysis can be related to multiple causes. Malignant neoplasms of the lung and pulmonary tuberculosis are most frequent causes of the paralysis. Idiopathic paralysis are also very frequent; paralysis caused by thyroid surgery [2,3] and endotracheal intubation come next. Ortner’s syndrome [4], also known as cardiovocal syndrome, is a rare clinical entity that is manifested by hoarseness due to left recurrent laryngeal nerve palsy secondary to cardiovascular disease. Thoracic aortic aneurysms are usually asymptomatic [24,25]. In a retrospective



**Figure 1:** Angio MRI: presence of pseudo-aneurysm of the descending thoracic aorta compressing the bronchus of the left and probably the left recurrent nerve. At the level of the origin of the descending thoracic enjoying a break from the intima closed chest trauma.



**Figure 2:** Angio MRI: Evidence of the relationship between the vascular intimal rupture post-traumatic descending thoracic aorta and the pseudo-aneurysm formation.

study of 62 patients with thoracic aortic aneurysms, only one patient (1,6%) manifested hoarseness secondary to recurrent nerve palsy [26]. In case of aortic aneurysm, the incidence of left recurrence laryngeal nerve paralysis has been reported as 5% to 12 % [26-28]. Among unusual causes, post-traumatic pseudoaneurysms of the thoracic aorta presenting at a time remote from the original injury are a rare but complex problem. In patients with recurrent laryngeal nerve paralysis, the left recurrent nerve is most commonly involved with respect to the right laryngeal nerve [5]. Left recurrent laryngeal nerve paralysis has been reported in approximately 10% of patients who survive long enough to develop a pseudoaneurysm [6], but the time of onset has rarely been specified. Woodson [20] reported 50 cases of thoracic aortic trauma reviewed to determine the incidence and timing of laryngeal paralysis, and compared with 50 cases of atherosclerotic aneurysms matched for location. Four patients in the traumatic group were hoarse, and the onset was immediate in 3. Six in the atherosclerotic group became hoarse. Their results indicate that laryngeal paralysis following severe trauma can be a very early sign of aortic injury and requires prompt and thorough investigation [29,30]. Similarly, in the case of a delayed presentation of a post-traumatic vascular injury, rapid diagnosis is of great importance, considering its unpredictable evolution. Razzouk et al. [15], reported 17 patients with pseudoaneurysm of the thoracic aorta. Four pseudoaneurysms developed post-trauma while 13 developed after aortic or cardiac surgery. The interval between initial operation and recognition of pseudoaneurysm varied from three months to eight years while the four post-traumatic pseudoaneurysms presented 5 to 26 years post injury.

Information regarding the reversibility of hoarseness in cardiovascular syndrome after correction of the underlying cardiovascular disease is limited. Of those reported [7], 12 of 14 cases resolved within 1 week to 3 years, with a duration of preexisting hoarseness ranging from 1 month to 10 years. It appears that the recurrent nerve palsy in cardiovascular syndrome can be reversed: it depends on the degree and duration of palsy.

Also in our case, in whom symptoms and clinical evidence were revealed in a delayed phase (twenty days post-trauma), the anamnesis of a previous cervical blunt trauma was useful. Moreover, the patient presented with dysphonia, a very common symptom in patients with unilateral laryngeal paralysis. Finally, radiological imaging proved effective to yield the definitive diagnosis. In fact, in the past decade, CT and magnetic resonance imaging has been gradually assuming more importance in cardiovascular diagnosis [20]; advances in imaging methods also

contributed to improved nonsurgical treatment of aortic pseudoaneurysms. Indeed, endovascular techniques are emerging as an alternative approach in the treatment of aortic disease, including post-traumatic aortic pseudoaneurysm [31-33]. A cell based therapy using Endothelial Progenitor Cells (EPCs) should be a possible revolutionary approach just used in several benign and malignant diseases [34-38]. EPCs biological properties are related to several biomarkers and pathogenic mechanisms involving  $Ca^{2+}$  related to vascular and non vascular pathologies [39-52].

## 4 Conclusion

In conclusion, the specialist should consider the diagnosis of Ortner's syndrome after more common causes have been excluded, particularly in patients with cardiovascular disease. After trauma if the nerve is not damaged the hoarseness may be reversible once the pseudoaneurysm has been treated. Therefore, timely diagnosis and correction of the underlying disease is very important.

The definitive diagnosis of post-traumatic aortic pseudoaneurysm is now accomplished for the most part by using noninvasive imaging techniques. In patients who sustained major blunt chest or neck trauma presenting with hoarseness and dysphonia, a recurrent nerve palsy following post-traumatic aortic pseudoaneurysm must be included in the differential diagnosis.

**Conflict of interest statement:** Authors state no conflict of interest.

## References

- [1] Testa D, Galera F, Insabato L, Vassallo A, Mesolella M, Galli V. Submandibular gland myoepithelioma. *Acta Otolaryngol.* 2005 Jun;125(6):664-666
- [2] Guerra G, Cinelli M, Mesolella M, Tafuri D, Rocca A, Amato B et al. Morphological, diagnostic and surgical features of ectopic thyroid gland: A review of literature. *Int J Surg.* 2014;12S1:S3-S11
- [3] Soscia A, Guerra G, Cinelli MP, Testa D, Galli V, Macchi V et al. Parapharyngeal Ectopic Thyroid: the possible persistence of the lateral thyroid anlage. *Surgical Radiologic Anatomy* 2004, 26(4):338-343
- [4] Ortner NI, Recurrenslahmung bei mitralstenose. *Wien Klin Wochenschr* 1987; 10: 753-755
- [5] Thirlwall AS, Ortner's syndrome: a centenary review of unilateral recurrent laryngeal nerve palsy secondary to cardiothoracic disease. *J Laryngol Otol* 1997; 111:869-871

- [6] Mulpuru SK, Vasavada BC, Punukollu GK, Patel AG. Cardiovascular Syndrome: A Systematic Review. *Heart, Lung and Circulation* 2008; 17:1-4
- [7] Condon LM, Katkov H, Singh A, Helseth HK. Cardiovascular syndrome in infancy. *Pediatrics* 1985; 76(1):22-25
- [8] Chan P, Lee CP, Ko JT, Hung JS. Cardiovascular (Ortner's) syndrome left recurrent laryngeal nerve palsy associated with cardiovascular disease. *Eur J Med* 1992;1(8): 492-495
- [9] Robida A, Povhe B. Cardiovascular syndrome in an infant with a double outlet of the right ventricle. *Eur J Pediatr* 1988;148(1):15-16
- [10] Rimón D, Cohen L, Rosenfeld J. Thrombosed giant left atrium mimicking a mediastinal tumor. *Chest* 1977; 71(3):406-408
- [11] Rubens F, Goldstein W, Hickey N, Dennie C, Keon W. Hoarseness secondary to left atrial myxoma. *Chest* 1989; 95(5):1139-1140
- [12] Yang TH, Chao PZ, Lee FP. Left vocal palsy as the presenting sign of thoracic aortic aneurysm. *J Taiwan Otolaryngol Head Neck Surg* 2003;38:63-67
- [13] Lydakis C, Thalassinou E, Apostolakis S, Michou E, Kontopoulou E. Hoarseness as imminent symptom of aortic aneurysm rupture (Ortner's Syndrome). *Int Angiol* 2006; 25:221-223
- [14] Teixido MT, Leonetti JP. Recurrent laryngeal nerve paralysis associated with thoracic aortic aneurysm. *Otolaryngol Head Neck Surg* 1990; 102: 140-144
- [15] Razzouk A, Gundry S, Wang N, Heyner R, Sciolaro C, Van Arsdell G et al. Pseudoaneurysms of the aorta after cardiac surgery or chest trauma. *Am Surg.* 1993;59(12):818-823
- [16] Casthely PA, Labagnara J. Hoarseness and vocal cord paralysis following coronary artery bypass surgery. *J Cardiothorac Vasc Anesth* 1992; 6:263-264
- [17] Tewari P, Aggrwal SK. Combined left-sided recurrent laryngeal and phrenic nerve palsy after coronary artery operation. *Ann Thorac Surg* 1996;61(6):1721-1722
- [18] Murty GE, Smith MC. Recurrent laryngeal nerve palsy following heart-lung transplantation: three case of vocal cord augmentation in the acute phase. *J Laryngol Otol* 1989;103(10): 968-969
- [19] Pai RK, Boyle NG, Child JS, Shivkumar K. Transient left recurrent laryngeal nerve palsy following catheter ablation of atrial fibrillation. *Heart Rhythm* 2005;2(2):182-184
- [20] Woodson GE, Kendrick B. Laryngeal paralysis as the presenting sign of aortic trauma. *Arch Otolaryngol Head and Neck Surg* 1989;115(9):1100-1102
- [21] Annema JT, Brahim JJ, Rabe KF. A rare cause of Ortner's syndrome (cardiovascular hoarseness). *Thorax* 2004; 59: 636
- [22] G. Motta, F.A. Salzano, S. Motta, M. Mesoletta, M. Salafia. Diagnosi differenziale: I tumori benigni e maligni del naso. In: *La Poliposi Nasale a cura di M. Maurizi, Relazione Ufficiale LXXXIV Congresso Nazionale della Società Italiana di Otorinolaringologia e Chirurgia Cervico-Facciale*, Saint Vincent, 28-31 Maggio 1997, Pacini editore, 238-280, 1997
- [23] Testa D, Guerra G, Landolfo PG, Nunziata M, Conzo G, Mesoletta M et al. Current therapeutic perspectives in the functional rehabilitation of vocal fold paralysis after thyroidectomy: CO<sub>2</sub> laser arytenoidectomy. *Int J Surg.* 2014;12 Suppl 1:S48-51
- [24] Cotrufo M, Della Corte A, De Santo LS, Quarto C, De Feo M, Romano G et al. Different patterns of extracellular matrix protein expression in the convexity and the concavity of the dilated aorta with bicuspid aortic valve: preliminary results. *J Thorac Cardiovasc Surg* 2005 Aug; 130(2):504-511
- [25] Cotrufo M, De Santo L, Della Corte A, Di Meglio F, Guerra G, Quarto C et al. Basal lamina structural alterations in human asymmetric aneurismatic aorta. *Eur J Histochem* 2005; Oct-Dec;49(4):363-370
- [26] Ishimoto SI, Ito K, Toyama M. Vocal cord paralysis after surgery for thoracic aortic aneurysm. *Chest* 2002; 121:1911-1915
- [27] Ishii K, Adachi H, Tsubaki K, Ohta Y, Yamamoto M, Ino T. Evaluation of recurrent nerve paralysis due to thoracic aortic aneurysm and aneurysm repair. *Laryngoscope* 2004; 114: 2176-2181
- [28] Nguyen TT, Zhang H, Dziegielewska PT, Seemann R. Vocal cord paralysis secondary to spontaneous internal carotid dissection: case report and systematic review of the literature. *J Otolaryngol Head Neck Surg* 2013; 42:34
- [29] Khan IA, Wattanasauwan N, Ansari A. Painless aortic dissection presenting as hoarseness of voice: Cardiovascular Syndrome: Ortner's Syndrome. *Am J Emerg Med* 1999; 17:361-363
- [30] Elzamzamy U, Joharij IA. Thoracic aortic aneurysm presenting only as vocal cord paralysis. *Neurosciences* 2007; 12:245-248
- [31] Rapacciuolo A, De Angelis MC, di Pietro E, Puglia R, Di Tommaso E, Ruggiero D et al. Percutaneous treatment of a aorto-caval fistula in a old high risk patient. *BMC Surg.* 2012;12 Suppl 1:S32
- [32] Amato B, Esposito G, Serra R, Compagna R, Vigliotti G, Bianco T et al. One-step mini-invasive treatment of abdominal aortic-iliac aneurysm associated with colo-rectal cancer. *Int J Surg.* 2014;12 Suppl 2:S193-196
- [33] Giugliano G, Laurenzano E, Rengo C, De Rosa G, Brevetti L, Sannino A et al. Abdominal aortic aneurysm in patients affected by intermittent claudication: prevalence and clinical predictors. *BMC Surg.* 2012;12 Suppl 1:S17
- [34] Moccia F, Dragoni S, Lodola F, Bonetti E, Bottino C, Guerra G et al. Store-dependent Ca<sup>2+</sup> entry in endothelial progenitor cells as a perspective tool to enhance cell-based therapy and adverse tumour vascularisation. *Curr Med Chem* 2012 Dec 1;19(34):5802-5818
- [35] Moccia F, Lodola F, Dragoni S, Bonetti E, Bottino C, Guerra G et al. Ca<sup>2+</sup> signalling in endothelial progenitor cells: a novel means to improve cell-based therapy and impair tumour vascularisation. *Curr Vasc Pharmacol.* 2014 Jan;12(1):87-105
- [36] Moccia F, Dragoni S, Cinelli M, Montagnani S, Amato B, Rosti V et al. How to utilize Ca<sup>2+</sup> signals to rejuvenate the reparative phenotype of senescent endothelial progenitor cells in elderly patients affected by cardiovascular diseases: a useful therapeutic support of surgical approach? *BMC Surg* 2013 Oct 8;13(Suppl 2):S46
- [37] Dragoni S, Laforenza U, Bonetti E, Reforgiato M, Poletto V, Lodola F et al. Enhanced Expression of Stim, Orai, and TRPC Transcripts and Proteins in Endothelial Progenitor Cells Isolated from Patients with Primary Myelofibrosis. *PLoS One* 2014 Mar 6;9(3):e91099
- [38] Lodola F, Laforenza U, Bonetti E, Lim D, Dragoni S, Bottino C et al. Store-operated Ca<sup>2+</sup> entry is remodelled and controls in vitro angiogenesis in endothelial progenitor cells isolated from tumoral patients. *PLoS One* 2012 7(9):e42541
- [39] Dragoni S, Turin I, Laforenza U, Potenza DM, Bottino C, Glasnov TN et al. Store-operated Ca<sup>2+</sup> entry does not control proliferation in primary cultures of human metastatic renal cellular carcinoma. *Biomed Res Int.* 2014;2014:739494

- [40] Sanchez-Hernandez Y, Laforenza U, Bonetti E, Fontana J, Dragoni S, Russo M et al. Store operated Ca<sup>2+</sup> entry is expressed in human endothelial progenitor cells. *Stem Cells and Development* 2010 Dec;19(12):1967-1981
- [41] Dragoni S, Laforenza U, Bonetti E, Lodola F, Bottino C, Guerra G et al. Canonical Transient Receptor Potential 3 channel triggers VEGF-induced intracellular Ca<sup>2+</sup> oscillations in endothelial progenitor cells isolated from umbilical cord blood. *Stem Cells and Development* 2013 Oct 1;22(19):2561-2580
- [42] Dragoni S, Laforenza U, Bonetti E, Lodola F, Bottino C, Berra-Romani R et al. Vascular endothelial growth factor stimulates endothelial colony forming cells proliferation and tubulogenesis by inducing oscillations in intracellular Ca<sup>2+</sup> concentration. *Stem Cells*. 2011 Nov;29(11):1898-1907
- [43] Berra-Romani R, Avelino-Cruz JE, Raqeeb A, Della Corte A, Cinelli M, Montagnani S et al. Ca<sup>2+</sup>-dependent nitric oxide release in the injured endothelium of excised rat aorta: a promising mechanism applying in vascular prosthetic devices in aging patients. *BMC Surg* 2013 Oct 8;13(Suppl 2):S40
- [44] Berra-Romani R, Raqeeb A, Torres-Jácome J, Guzman-Silva A, Guerra G, Tanzi F et al. The mechanism of injury-induced intracellular calcium concentration oscillations in the endothelium of excised rat aorta. *J Vasc Res*. 2012;49(1):65-76
- [45] Potenza DM, Guerra G, Avanzato D, Poletto V, Pareek S, Guido D et al. Hydrogen sulphide triggers VEGF-induced intracellular Ca<sup>2+</sup> signals in human endothelial cells but not in their immature progenitors. *Cell Calcium*. 2014 Sep;56(3):225-234
- [46] Dragoni S, Guerra G, Pla Af, Bertoni G, Rappa A, Poletto V et al. A Functional Transient Receptor Potential Vanilloid 4 (Trpv4) Channel Is Expressed In Human Endothelial Progenitor Cells. *J Cell Physiol* 2015 Jan;230(1):95-104
- [47] Moccia F, Zuccolo E, Poletto V, Cinelli M, Bonetti E, Guerra G et al. Endothelial progenitor cells support tumour growth and metastatisation: implications for the resistance to anti-angiogenic therapy. *Tumour Biol*. 2015 Aug;36(9):6603-6614
- [48] Dragoni S, Reforgiato M, Zuccolo E, Poletto V, Lodola F, Ruffinatti FA et al. Dysregulation of VEGF-induced pro-angiogenic Ca<sup>2+</sup> oscillations in primary myelofibrosis-derived endothelial colony forming cells. *Exp Hematol*. 2015 Dec;43(12):1019-1030.e3
- [49] Moccia F, Guerra G. Ca<sup>2+</sup> Signalling in Endothelial Progenitor Cells: Friend or Foe? *J Cell Physiol*. 2016 Feb;231(2):314-327
- [50] Ronco V, Potenza DM, Denti F, Vullo S, Gagliano G, Tognolina M et al., A novel Ca<sup>2+</sup>-mediated cross-talk between endoplasmic reticulum and acidic organelles: Implications for NAADP-dependent Ca<sup>2+</sup> signalling. *Cell Calcium* 2015 Feb;57(2):89-100
- [51] Moccia F, Zuccolo E, Soda T, Tanzi F, Guerra G, Mapelli L et al. Stim and Orai proteins in neuronal Ca(2+) signaling and excitability. *Front Cell Neurosci*. 2015 Apr 24;9:153
- [52] Zuccolo E, Bottino C, Diofano F, Poletto V, Codazzi AC, Mannarino S et al. Constitutive store-operated Ca<sup>2+</sup> entry leads to enhanced nitric oxide production and proliferation in infantile hemangioma-derived endothelial colony forming cells. *Stem Cells Dev*. 2016 Feb 15;25(4):301-319