Prenatal Diagnosis of Ulbright-Hodes Syndrome

Giuseppe M. Maruotti, MD, Annalisa Agangi, MD, Raffaele Napolitano, MD, Laura L. Mazzarelli, MD, Filomena Quaglia, MD, Ilma F. Carbone, MD, Maria R. D'Armiento, MD, Pasquale Martinelli, MD

Ulbright-Hodes syndrome, or limb reduction defects and renal dysplasia, is an unusual lethal congenital malformation that consists of mesomelia, radiohumeral fusion, and renal dysplasia. We report the successful prenatal diagnosis of the condition at 21 weeks' gestation in a family with a negative history, which to our knowledge has not been reported previously. Sonographic findings, new and atypical features, the differential diagnosis, and counseling of the couple are reported.

Case Report

A 32-year-old primigravida was referred to our department at 21 weeks' gestation because of severe oligohydramnios and growth restriction on routine second-trimester sonography. Her family history was negative for limb reduction disease or renal dysplasia. The parents were not consanguineous. Amniocentesis revealed a normal 46,XY karyotype. On sonography, we confirmed the severe oligohydramnios and growth restriction with fetal biometric measurements compatible with 18 weeks' gestation. The fetal anatomic examination revealed severe subcutaneous diffuse edema (Figure 1), shortening of all limbs, absence of a longitudinal mesomelic segment of both superior limbs (Figure 2), and absence of the right fibula (Figure 3). The evaluation of the extremities showed a left clubfoot and hyperextension of both hands (probably because of the absence of ulnae). Cerebellar hypoplasia and a moderate cleft lip were noted. Additional anomalies included bilateral renal dysplasia. Both kidneys were abnormally small, with cysts and with increased parenchymal echogenicity (Figure 4). Although there was the presence of additional intracranial abnormalities that to our knowledge have not been reported previously, the coexistence of limb defects and renal dysplasia led to the suspicion of the limb reduction defects and renal dysplasia, or

Received September 22, 2008, from the Prenatal Diagnosis Unit, Department of Gynecology and Obstetrics (G.M.M., A.A., R.N., L.L.M., F.Q., I.F.C., P.M.), and Department of Biomorphologic and Functional Sciences (M.R.D.), University Federico II, Naples, Italy. Revision requested September 25, 2008. Revised manuscript accepted for publication November 11, 2008.

Address correspondence to Pasquale Martinelli, MD, Vico Acitillo 53, 80131 Naples, Italy.
E-mail: martinel@unina.it

© 2009 by the American Institute of Ultrasound in Medicine

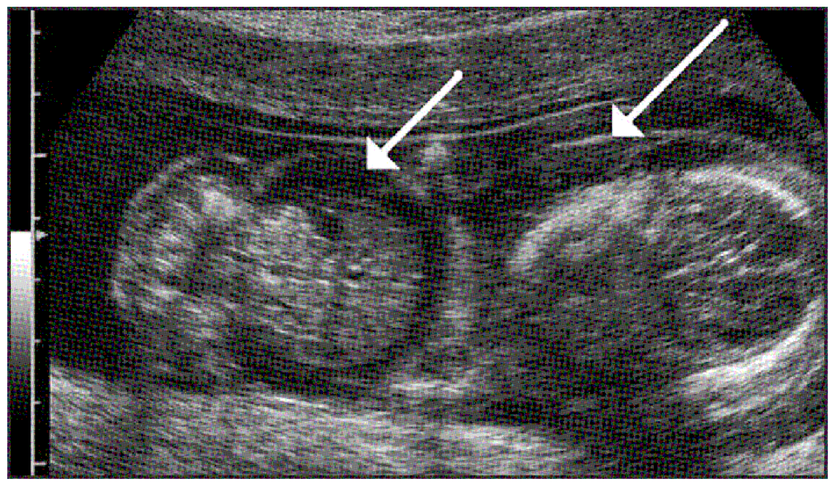

Figure 1. Diffuse edema. Examination of the fetal anatomy revealed severe fluid accumulation due to subcutaneous edema (arrows).

Ulbright-Hodes syndrome. During prenatal counseling, we informed the couple that the sonographic features observed were compatible with the rare Ulbright-Hodes syndrome. We also discussed the difficulty of a definitive prenatal diagnosis because, to our knowledge, (1) this condition has never been identified prenatally, and (2) the association with cerebellar hypoplasia and a cleft lip has never been described before. The couple opted for termination of pregnancy because all of the reported cases were lethal due to severe renal dysplasia.

At necroscopy, the presence of the prenatal anomalies, including severe subcutaneous diffuse edema (Figure 5), was confirmed. Severe shortening of the limbs, absence of both ulnae, and absence of the right fibula were confirmed by radiography (Figure 6). A left clubfoot was also present. Bilateral renal dysplasia and hypoplasia (Figure 7) were confirmed. In addition, radiohumeral fusion, a Potter-like face with a beaked nose, a moderate cleft lip, slight antimongoloid slanting of the palpebral fissures, micrognathia, a high palate and small mouth, a short neck, hypoplastic lungs, and cerebellar hypoplasia were noted. The diagnosis of limb reduction defects and renal dysplasia, or Ulbright-Hodes syndrome, was confirmed postnatally.

Discussion

We describe the prenatal diagnosis of an uncommon condition that to our knowledge has never been described prenatally. Limb reduction defects and renal dysplasia is an extremely rare and lethal disease, with only 3 cases reported in the world in the last 20 years.[1,2] In 1984, Ulbright et al[1] described an isolated male neonate with a "new syndrome" consisting of mesomelia, radiohumeral fusion, and renal dysplasia. The main manifestations described were a high palate, congenital shortness of the forearms and metacarpals with fusion of the humerus and radius, absence of the ulnae and severe hypoplasia of the radius, absent fibulae, bilateral talipes equinovarus, long, thin ribs, anterior rounding of the lumbar vertebrae, and renal hypoplasia. This syndrome appears lethal because of the severe renal dysplasia causing oligohydramnios and pulmonary hypoplasia. In 1990, Schrander-Stumpel et al[2] reported 2 siblings, a male and a female, who died of respiratory failure shortly after birth. The siblings each had complete phocomelia of the upper limbs,

Figure 2. Absence of a longitudinal mesomelic segment of the superior limbs. Examination of the superior limbs revealed hyperextension of the hand (arrow), which we assumed indicated absence of the ulna.

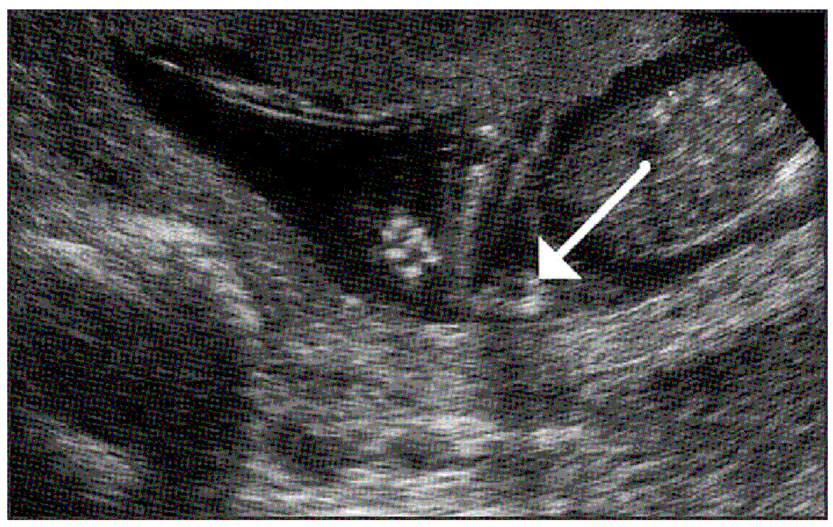

Figure 3. Absence of the left fibula. Examination of the inferior left leg revealed a left clubfoot, which we assumed indicated absence of the fibula.

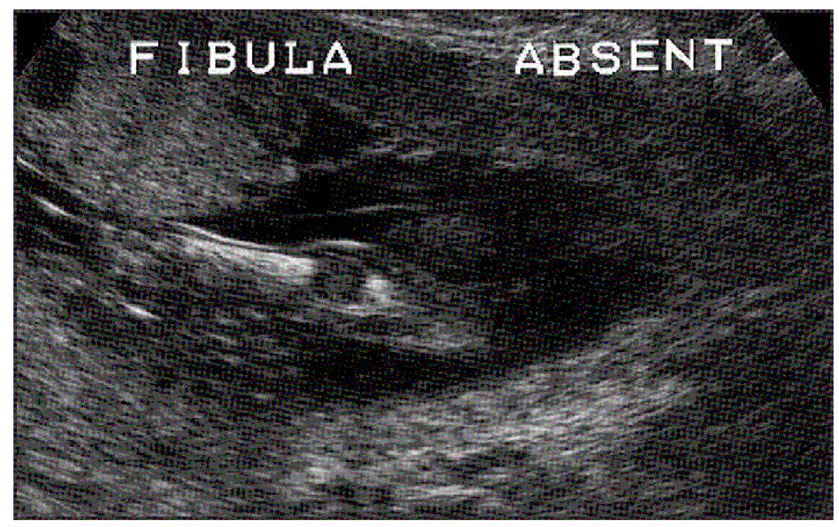

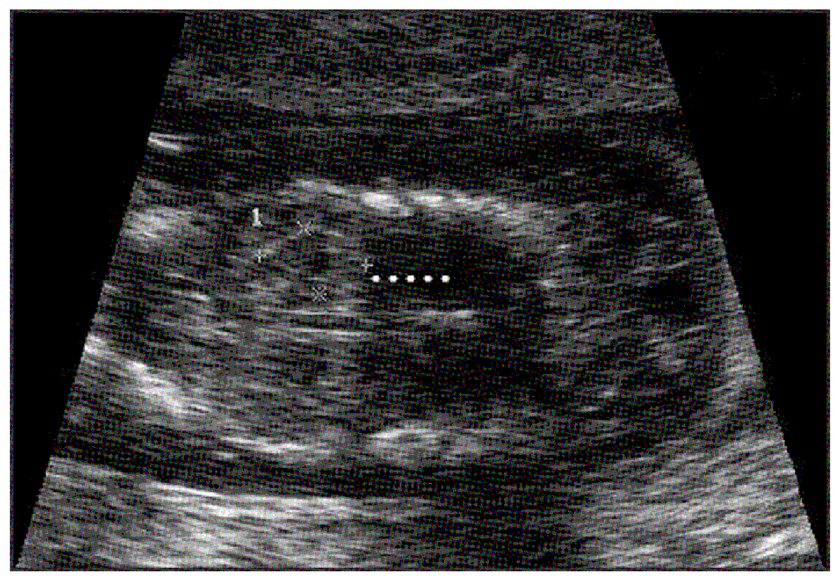

Figure 4. Renal dysplasia and hypoplasia. Both the kidneys were abnormally small, with cysts and hyperechoic renal parenchyma.

rib anomalies, renal dysplasia, external genital abnormalities, and a Potter-like face with growth restriction. The authors hypothesized that their cases represented evidence of the existence of the new syndrome described in 1984 by Ulbright et al[1] and suspected an autosomal recessive transmission.

Figure 5. Diffuse edema. Severe fluid accumulation due to subcutaneous edema was present at the neck, thorax, and abdomen. A potter-like face with a beaked nose, a moderate cleft lip (arrow), slight antimongoloid slanting of the palpebral fissures, micrognathia (asterisk), and a small mouth are visible.

In the Online Mendelian Inheritance in Man database, limb reduction defects are features of 109 syndromes and renal dysplasia of 230; however, the coexistence of both abnormalities is typical of only 20 conditions. In the differential diagnosis, we must consider mainly thrombocytopenia and absent radius syndrome.[3] Its major features are bilateral absence of the radius and thrombocytopenia, but complete phocomelia of the arms has been described in about 5% of cases. Defects of the limbs are possible in thrombocytopenia and absent radius syndrome; however, the fibula aplasia and renal dysplasia have never before been described. The syndrome of mesomelic dwarfism, which involves hypoplasia of the ulnae, fibulae, and mandible, does not include renal abnormalities. Ulbright-Hodes syndrome lacks the thickness and bowing of the radii and tibiae typical of many syndromes characterized by skeletal abnormalities and the ocular involvement described in most syndromes with renal dysplasia.[4]

Figure 6. Postnatal radiography shows severe shortening of the limbs, absence of both ulnae, and absence of the right fibula; r indicates radius; and T, right tibia.

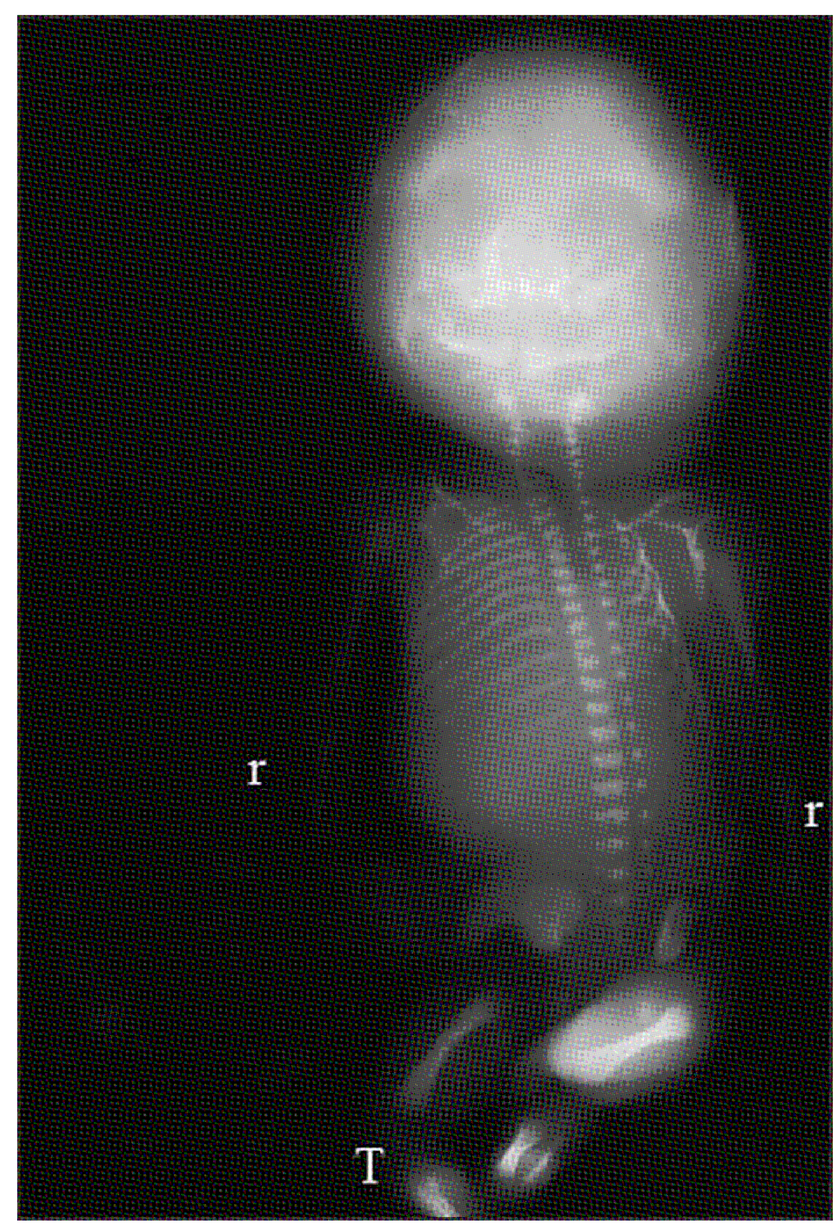

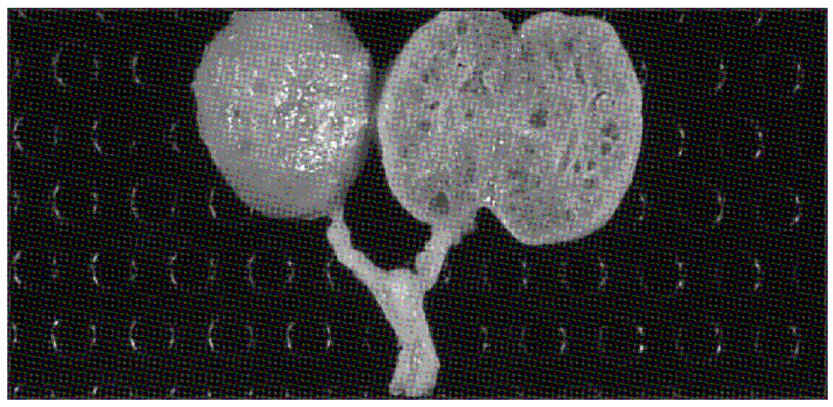

Figure 7. Necroscopy of the kidneys. Both kidneys have an abnormal structure; the regular parenchyma is absent, and there are multiple small cysts. Bilateral renal dysplasia and hypoplasia were confirmed.

Schinzel-Giedon syndrome is characterized by renal malformation, mesomelic brachymelia, and talipes, but it does not include the absence of ulnae and fibulae, the facial, rib, and hand anomalies observed in limb reduction defects and renal dysplasia.[5] Another case described by Gollop and Coates[6] included a bifid humerus and hand malformation, but it lacked renal involvement. Robert syndrome was also considered in the differential diagnosis because its clinical heterogeneity of skeletal dysplasia, but the absence of head and eye deformities and the presence of renal dysplasia led us to exclude the diagnosis.[7]

A challenging differential diagnosis was atelosteogenesis type 2, or de la Chapelle dysplasia. This syndrome is characterized by severely shortened limbs, a bifid distal humerus, a rounded distal femur (features not present in our case), a small chest, scoliosis, clubfoot, abducted thumbs, and a cleft palate. However, renal dysplasia is not a typical feature of this condition.[8]

A few but solid observations suggest that our case was Ulbright-Hodes syndrome instead of another known condition or a new syndrome. First, in all of the cases of Ulbright-Hodes syndrome, ours included, the renal dysplasia is characterized by a few normal nephrons scattered randomly through the renal tissue. On the contrary, in classic renal dysplasia, the kidneys are composed of normal areas interspersed with areas of dysplasia, which do not contain normal nephrons. Second, there was a perfect correspondence between the limb abnormalities in the fetus we observed and that described by Ulbright-Hodes et al[1]: the mesomelia, radiohumeral fusion, absence of ulnae, hypoplasia of the radius, and absence of fibulae were seen in both cases. Third, in ours and previous cases, the severe oligohydramnios, secondary to the renal dysplasia, was responsible for the talipes equinovarus and the "Potter-like face" with a beaked nose, slight antimongoloid slanting of the palpebral fissures, micrognathia, a high palate, and a small mouth. In our case, rib abnormalities were not observed. Never-reported features consisting of cerebellar hypoplasia and moderate cleft features were observed and may be considered atypical findings. Because the origin of this condition is unknown, we have hypothesized that limb defects and, above all, the histologic aspect of kidneys are the main characteristics of the syndrome. The abnormality of the kidneys causes oligohydramnios and pulmonary hypoplasia, which leads to the death of affected fetuses. In the meantime, adjunctive features may be observed, but they do not substantially influence the natural history of the disease.

In summary we have described the prenatal sonographic diagnosis of limb reduction defects and renal dysplasia, also known as Ulbright-Hodes syndrome.

References

1. Ulbright CE, Hodes ME, Ulbright TM. New syndrome: renal dysplasia, mesomelia, and radiohumeral fusion. Am J Med Genet 1984; 17:667–668.
2. Schrander-Stumpel C, de Die-Smulders C, Fryns JP, da Costa J, Bouckaert P. Limb reduction defects and renal dysplasia: confirmation of a new, apparently lethal, autosomal recessive MCA syndrome. Am J Med Genet 1990; 37:133–135.
3. Hall JC. Thrombocytopenia and absent radius (TAR) syndrome. J Med Genet 1987; 24:79–83.
4. McKusick V. Mendelian Inheritance in Man. 6th ed. Baltimore, MD; Johns Hopkins University Press; 1978.
5. Kelley RI, Zackai EH, Charney ED. Congenital hydronephrosis, skeletal dysplasia, and severe developmental retardation: the Schinzel-Giedion syndrome. J Pediatr 1982; 100: 943–946.
6. Gollop TR, Coates V. Apparent bifurcation of distal humerus with oligoectrosyndactyly. Am J Med Genet 1983; 14:591–593.
7. Fryns JP, Kleczkowska A, Moerman P, van den Berghe K, van den Berghe H. The Robert tetraphocomelia syndrome: identical limb defects in two siblings. Ann Genet 1987; 30: 243–245.
8. Whitley CB, Burke BA, Granroth G, Gorlin RJ. de la Chapelle dysplasia. Am J Med Genet 1986; 25:29–39.