

CT FINDINGS OF THORACOLUMBAR SPINE LESIONS IN DOGS

**C. DARABAN¹, V. VULPE¹, FLORENTINA BOCĂNEȚI¹, GIUSEPPINA
MENNONNA², M. SACCONI², G. FATONE², L. MEOMARTINO²**

¹University of Agriculture Science and Veterinary Medicine „Ion Ionescu de la Brad”, Faculty of Veterinary Medicine, M. Sadoveanu Alley No. 8, 700489, Iasi, Romania

²Faculty of Veterinary Medicine, Naples, Italy
E-mail: titidaraban@yahoo.com

Summary

In veterinary medicine, computed tomography (CT) is one of the most commonly used methods for imaging the spine because it provides a detailed examination of the spinal cord and surrounding tissues.

The aim of this study was to assess thoracolumbar lesions in a number of dogs studied during the year 2011.

There were retrospectively evaluated CT studies from 30 dogs of different breeds (mean age= 6.23 years) presented at the Interdepartmental Center of Radiology in the period January - December 2011, with suspected thoracolumbar vertebral or spinal cord lesions. The CT studies were performed without contrast medium in 27 patients, with contrast medium in subarachnoid space (CT- myelography) in two dogs, and in two patients before and after i.v. administration of contrast medium (Iopamidol 370mg/ml). In one dog both intravenous and subarachnoid administration of contrast medium were used.

There were found 46 disc herniations, 10 degenerative spondylopathies, 5 vertebral malformations, 4 vertebral neoplasia, 4 disc degenerations (mineralization and/or vacuum phenomenon), 4 subdural and epidural hemorrhages, 2 spinal cord degenerations (degenerative myelopathy), 2 radicular neoplasia and 2 discospondylitis. In our sample, there was a prevalence of intervertebral disc herniation and in many cases the same dog showed multiple localizations. Usually, disc herniations were clearly visible without contrast medium, causing different degrees of spinal cord compression.

In conclusion, CT demonstrated to be a valuable diagnostic tool for detection and characterization of thoracolumbar spinal lesions in dogs.

Key words: CT, thoracolumbar spine, dog, herniated disc

Nowadays, computed tomography is an indispensable imaging method for the diagnosis of vertebral or spinal cord lesions in small animals. One of the strengths of CT is its use in the evaluation of bony changes. Thoracolumbar level is exposed to congenital, neoplastic, degenerative, inflammatory or traumatic lesions.

Materials and methods

During the January to December 2011, thirty dogs suspected to have thoracolumbar spinal injuries were examined using CT.

Mixed breed dogs were the most common, with 9 individuals. Other breeds included the German Shepherd (8), Bichon Maltese (2), Dachshund (2), French Bulldog (2), Labrador (2), and 1 each of other breeds (Beagle, Cocker Spaniel, Pekingese, Rottweiler and Yorkshire Terrier). Twenty one male (twenty intact and one neutered male) and nine female (four intact and five neutered females) dogs were included. The mean age was 6.23 years (range 2 - 12 years). The mean weight was 19.7 kg (range 4.5 - 50 kg). A neurological examination was performed on all animals at the time of admission to hospital.

The CT studies were performed using a helical (single layer) CT scanner (GE Prospeed). During the imaging procedure, all dogs were maintained in dorsal recumbency and under general inhalation anesthesia. Following the scout image of the thoracolumbar level, obtained in a lateral view, all the intervertebral spaces between T3-T4 and L3-L4 were studied by a single transverse subtle slice passing through the endplates of vertebral bodies. Once the lesion site was suspected, the corresponding tract (two or more vertebral bodies) was studied using subtle contiguous slices (1 or 3 mm). Slice thickness varied between dogs, depending on body size and length of the studied segment. CT settings were 120 kVp, 100 - 160 mA, with a scan time of 2 seconds per slice. CT window level (WL) and window width (WW) settings varied according to the examined tissues. For assessing tissue density, on the transverse CT images, Hounsfield Units (HU) were measured in a Region of Interest (ROI). In some cases, for achieving more information, Multiplanar Reformatted images (MPR) were obtained. CT studies were performed without contrast medium in 27 patients, with contrast medium in subarachnoid space (CT- myelography) in 2 dogs, and in 2 patients before and after i.v. administration of contrast medium (Iopamidol 370mg/ml; 1 ml/kg). In one dog both intravenous and subarachnoid administration of contrast medium were used.

All the transverse images were assessed for the presence of spinal cord or vertebral or intervertebral spaces lesions (i.e. spinal cord compressions, disc herniations, spinal cord or vertebral neoplasia, etc.).

Results and discussions

On a CT transverse scan, the spinal cord is round-shaped, surrounded dorso-laterally by epidural fat and ventrally, by two nerve roots; usually, its density is between 30 - 40 HU (Fig. 1). The vertebral bone tissue shows a regular and uniform cortical bone and a homogeneous trabecular bone. The intervertebral disc appears as a hypodense round-shaped tissue between two vertebral endplates. MPR images into a dorsal or sagittal plane may help to visualize the relationship among the spinal cord, vertebrae and surrounding tissues.

The thirty dogs included in this study had a total of 46 disc herniations, 10 degenerative spondylopathies, 5 vertebral malformations, 4 vertebral neoplasia, 4 disc degenerations (mineralization and/or vacuum phenomenon), 4 subdural and

epidural hemorrhages, 2 spinal cord degenerations (degenerative myelopathy), 2 radicular neoplasia and 2 discospondylitis.

There was a prevalence of intervertebral disc herniation (30 Hansen type II; 16 Hansen type I) and in many cases the same dog showed multiple localizations of lesions. Disc herniations were clearly visible without contrast medium, causing different degrees of spinal cord compression (Fig. 2).

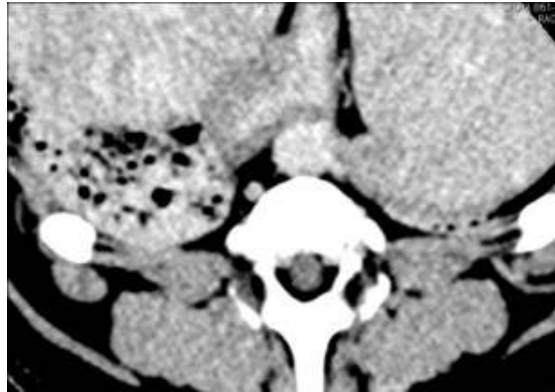


Fig. 1. CT transverse image - normal aspect of thoracic vertebra and spinal cord (T10-11)

The diagnosis of intervertebral disc herniations using non-contrast CT scans is beneficial to the dog because it avoids the injection of contrast medium into the subarachnoid space, potentially damaging the injured spinal cord further. Another advantage is that it is quick to perform and so reduces anesthesia time. Non-contrast CT scans of the spine can be useful in the diagnosis of acute intervertebral disc herniations in chondrodystrophoid breeds of dog (6).

Most intervertebral disk extrusions are spontaneous and are not associated with any traumatic event. In dogs, about 80% of thoracolumbar extrusions or protrusions occur between the T10 and L3 vertebrae. This may relate to the increased motion of the vertebral column at this level compared with the more stable thoracic area (1).

Dogs with disc herniations showed at the same time multiple intervertebral disc degenerations (i.e. mineralization or vacuum phenomenon) (Fig. 8). In small sized dogs, due to the thicker intervertebral space, it was often difficult to make a differential diagnosis between disc mineralization and partial volume artifact. Disc degeneration is common in all dog breeds, but the chondrodystrophic breeds are affected more frequently (3). In our study, calcification discs and vacuum phenomenon were presented in four dogs. The vacuum phenomenon appears when gas (nitrogen) from extracellular fluid accumulates in a space caused by

distraction of opposing surfaces. In CT images gas is characterized by its markedly decreased opacity (4).

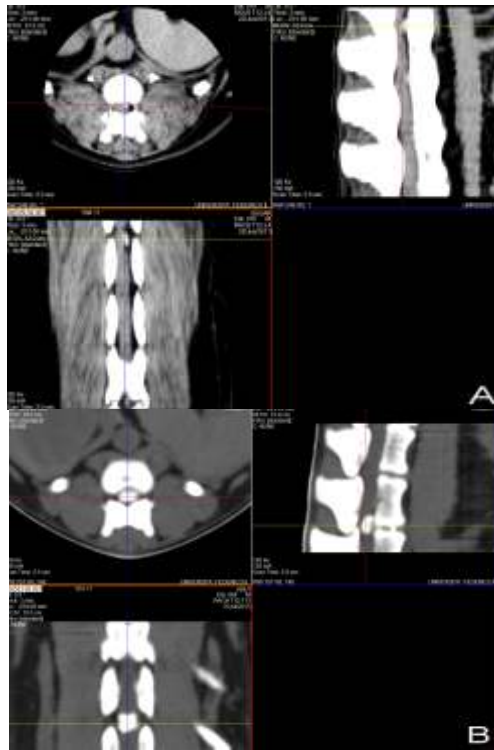

Fig. 2. MPR (bone window) - Mild (A) and severe (B) intervertebral disc herniation

One Cocker Spaniel and one mixed-breed dog presented subdural/epidural hemorrhage due to disc herniation. Subdural/epidural hemorrhage appears as a relatively hyperdense material surrounding the spinal cord. CT images suggest that subdural/epidural hemorrhage can extend cranial and caudal to the disc herniation, over a number of vertebrae (Fig. 3).

In three dogs (one Rottweiler and two mixed-breed dogs (range 7 – 11 years) spinal cord and vertebral degenerations associated with neoplasia were observed.

Differentiating between intradural/extramedullary lesions and intramedullary lesions can be important regarding treatment of these lesions. Dorsal and sagittal plane reconstruction of the CT images may also help enhance lesion detection and exact anatomic classification, particularly for differentiation of spinal cord neoplasms (Fig. 4).

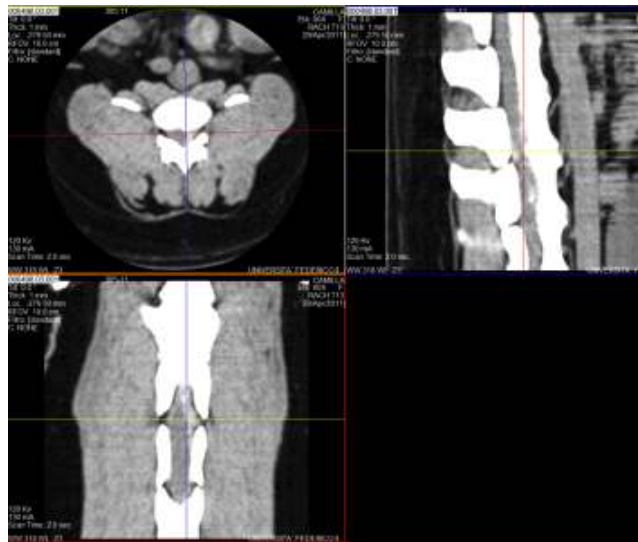


Fig. 3. MPR (soft tissue window) - Subdural haemorrhage at the level of L2-L3 and L3-L4

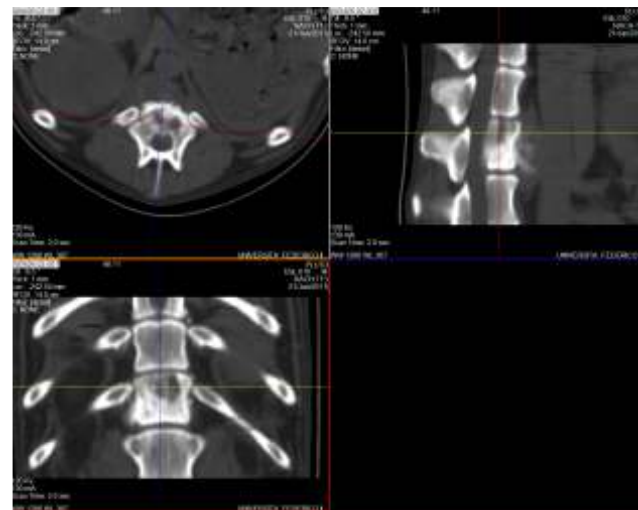


Fig 4. MPR (bone window) - Note the central bone lysis and the periosteal proliferation on ventral surface of the T13 vertebral body. At the same time, a mild periosteal proliferation on the pavement of T13 vertebral canal causes a discrete extradural compression of the spinal cord

It has been suggested that the administration of intravenous contrast medium may enhance intramedullary neoplasms (7).

In order to evaluate the degree of attenuation of the spinal cord, a region of interest (ROI) was chosen (Fig. 5).

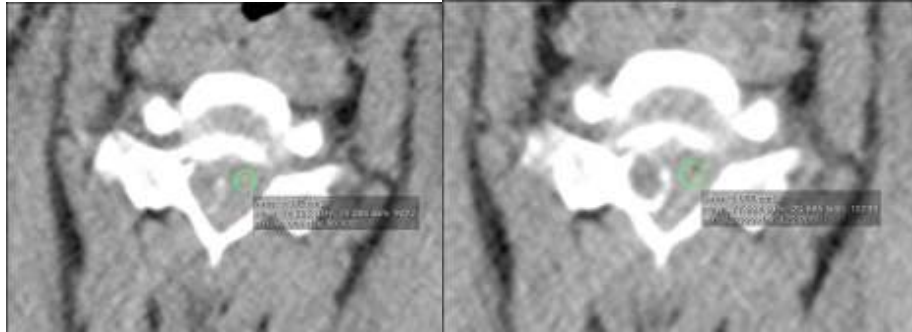


Fig. 5. Root neoplasia: CT transverse scan of a CT-myelography at level of T1-T2. A- pre-contrast; B- post-contrast. ROI shows a weak contrast enhancement (pre-contrast: 74.5 HU; post-contrast: 77.9 HU) of the compressive lesion

In a French bulldog male of 3.5 years, multiple vertebral malformations, like hemivertebra ("wedge-shaped" vertebra) and butterfly vertebra, were found at the level of the thoracic spine (Fig. 6). These malformations are commonly detected in brachycephalic breeds, especially in those that also have screw tails. The most commonly affected site is the mid thoracic region of the vertebral column (2). A German Shepherd male of 8 years, showed multiple dorsal process laterally deviated. In our experience, this malformation is occasionally found and usually, it is not correlated with any spinal cord injuries.

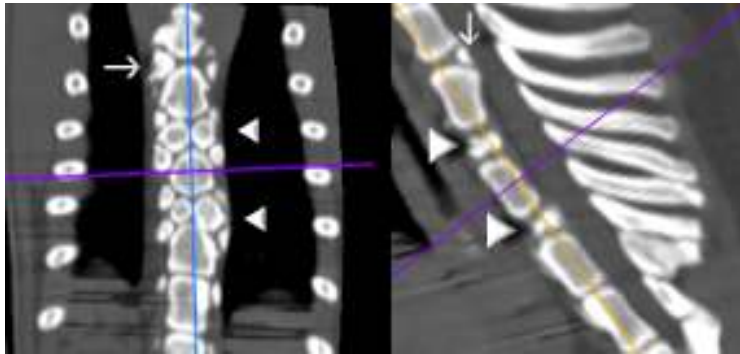


Fig. 6. MPR (bone window) - hemivertebra (white arrow) and butterfly vertebra (white arrowhead)

Two German Shepherd dogs, one intact male and one neutered female, both 9 years of age, were suspected of degenerative myelopathy after CT examination. They showed multiple foci of spondylopathies, small disc protrusions and several regions of spinal cord atrophy and deformity (Fig. 7) (5).

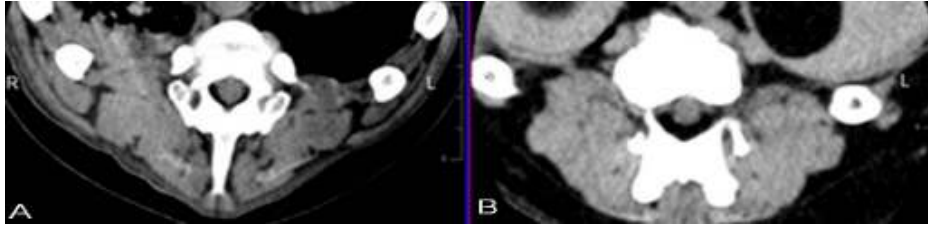


Fig. 7 Transverse CT images obtained at T12-T13 (soft tissue window). A- normal spinal cord; B- spinal cord atrophy in dog with suspect degenerative myelopathy: spinal cord is narrowed and has a polygonal shape.

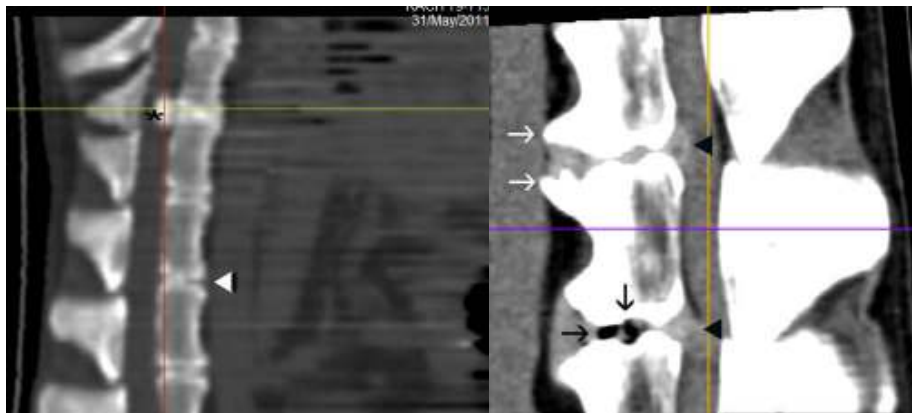


Fig. 8. MPR sagittal reconstruction of disc herniations and disc degenerations; A – Disc herniation (Hansen type I) (*) at level of T10-T11 and mineralization at level of T12-T13 (white arrowhead). B – Disc protrusion (Hansen type II) (black arrowheads), spondylopathy (white arrows) and vacuum phenomenon (black arrows) at level of T13-L1 and L1-L2.

Conclusions

Computed tomography demonstrated to be a valuable diagnostic tool for detection and characterization of thoracolumbar spine lesions in dogs.

MPR images may help to understand better the connections between the spinal cord, vertebral bodies and surrounding tissues.

The administration of intravenous contrast medium may enhance intramedullary neoplasms.

A correct CT diagnostic may provide a good therapeutic care.

References

1. **De Lahunta, A., Glass, E.**, Veterinary Neuroanatomy and Clinical Neurology, Philadelphia, WB Saunders, 2008.
2. **Done, S.H., Drew, R.A., Robins, G.M.**, Hemivertebra in the dog: clinical and pathological observations, Veterinary Record, 1975, 96, 313-317.
3. **Hansen, H.J.**, A pathologic-anatomic study on disc degeneration in dog, Acta Orthopædica Scandinavica, Supplementum, 1952, 1-117.
4. **Hathcock, J.**, Vacuum phenomenon of the canine spine: CT findings in 3 patients, Veterinary Radiology & Ultrasound, 1994, 35, 4, 285-289.
5. **Jones, J., Inzana, Karen, Rossmeyl, J., Bergman, R., Wells, Tana, Butler, Katherine**, CT myelography of the thoraco-lumbar spine in 8 dogs with degenerative myelopathy, Journal of Veterinary Science, 2005, 6(4), 341-348.
6. **Olby, Natasha, Muñana, Karen, Sharp, N., Thrall, D.**, The computed tomographic appearance of acute thoracolumbar intervertebral disc herniations in dogs, Veterinary Radiology & Ultrasound, 2000, 41, 5, 396-402.
7. **Roub, L.W., Drayer, B.P.**, Spinal computed tomography: limitations and applications, American Journal of Roentgenology, 1979, 133, 267-273.