

Extraskeletal chondroma of the masseter muscle: a case report with review of the literature

J. Falletti¹, R. De Cecio^{1,2},
A. Mentone³, V. Lamberti¹,
M. Friscia³, S. De Biasi³,
L. Califano³, L. Insabato¹

¹Department of Biomorphological and Functional Science, Section of Anatomic Pathology, Federico II University, Naples, Italy;

²Unit of Anatomic Pathology and Cytopathology, Regional Oncologic Hospital, CROB, Rionero in Vulture, Potenza, Italy;

³Department of Maxillofacial Surgery, Federico II University, Naples, Italy

J. Falletti, R. De Cecio, A. Mentone, V. Lamberti, M. Friscia, S. De Biasi, L. Califano, L. Insabato: Extraskeletal chondroma of the masseter muscle: a case report with review of the literature. Int. J. Oral Maxillofac. Surg. 2009; 38: 895–899. © 2009 International Association of Oral and Maxillofacial Surgeons. Published by Elsevier Ltd. All rights reserved.

Abstract. The authors report a case of soft tissue chondroma of the masseter muscle in a 49-year-old man. The tumour was entirely composed of lobules of hyaline cartilage. The literature on head and neck soft tissue chondroma is also reviewed. To the authors' knowledge, this is the first case of muscular soft tissue chondroma in the head and neck region.

Keywords: soft tissue; cartilaginous; tumour.

Accepted for publication 27 February 2009
Available online 5 April 2009

Benign extrasosseous cartilaginous tumours are uncommon and usually present as discrete, ossified masses localised in soft tissues. Juxtacortical chondroma, also known as periosteal chondroma, arises from the periosteal region of the long bone or a small bone of the hand or foot^{30,43}. When occurring in extrasosseous and extrasynovial locations, it is known as extraskeletal or soft tissue chondroma¹².

Soft tissue chondroma generally affects the soft tissue of the hands and feet^{26,43} in the third and fourth decades of life²⁶; it occasionally occurs in the abdominal wall, and head and neck¹⁰. In the head and neck area, the most reported sites are the nasal cavity, paranasal sinuses, larynx¹⁰ and tongue^{7,24}, less frequently, it has been described in the soft palate¹³, tonsil⁴⁶, masticatory space¹⁰, parotid gland^{3,18,22} and cheek^{4,16,18,26}. Uncommon sites are the fallopian tubes¹⁵, ovaries²⁹ and lungs²⁷.

The authors describe a soft tissue chondroma of the left masseter muscle

in a 49-year-old man. To the authors' knowledge, this is the first case of chondroma reported at this site.

Case report

A 49-year-old man was admitted with a 6 year history of swelling in the left preauricular region that had increased in the last year. Clinical examination revealed a 5 cm diameter, well-circumscribed nodule, covered by normal skin in the left preauricular region (Fig. 1A); it appeared firm and painless, and floating in superficial planes.

Ultrasound examination revealed a well-circumscribed, 4 cm diameter, nodular mass in the masseter muscle with a non homogeneous hypoechoic structure and calcifications (Fig. 1B).

A computed tomography (CT) scan confirmed the presence of a non homogeneous density nodule in the left masseter muscle (Fig. 1C). Fine-needle aspiration

cytology of the mass was performed suggesting a diagnosis of mixed tumour of the parotid gland. The lesion was surgically excised. A 'face lift' cutaneous incision was made in the parotid region and the common trunk of the facial nerve was isolated. Myotomy of the masseter muscle was carried out, and the mass was removed (Fig. 1D). The parotid gland was returned to its original position.

The specimen was a 4 cm, well-circumscribed nodular mass (Fig. 2A). The cut surface was thickened and translucent with a central calcified area (Fig. 2B).

Histological examination showed a well-circumscribed, lobulated mass composed of nodules of hyaline cartilage surrounded by condensed, collagenous tissue (Fig. 2C). There was variation in cellularity within the lesion and the chondrocytic lacunae varied in size (Fig. 2D). Mitotic figures were not seen and there was no evidence of atypia, necrosis or vascular invasion. The tumour was entirely pro-

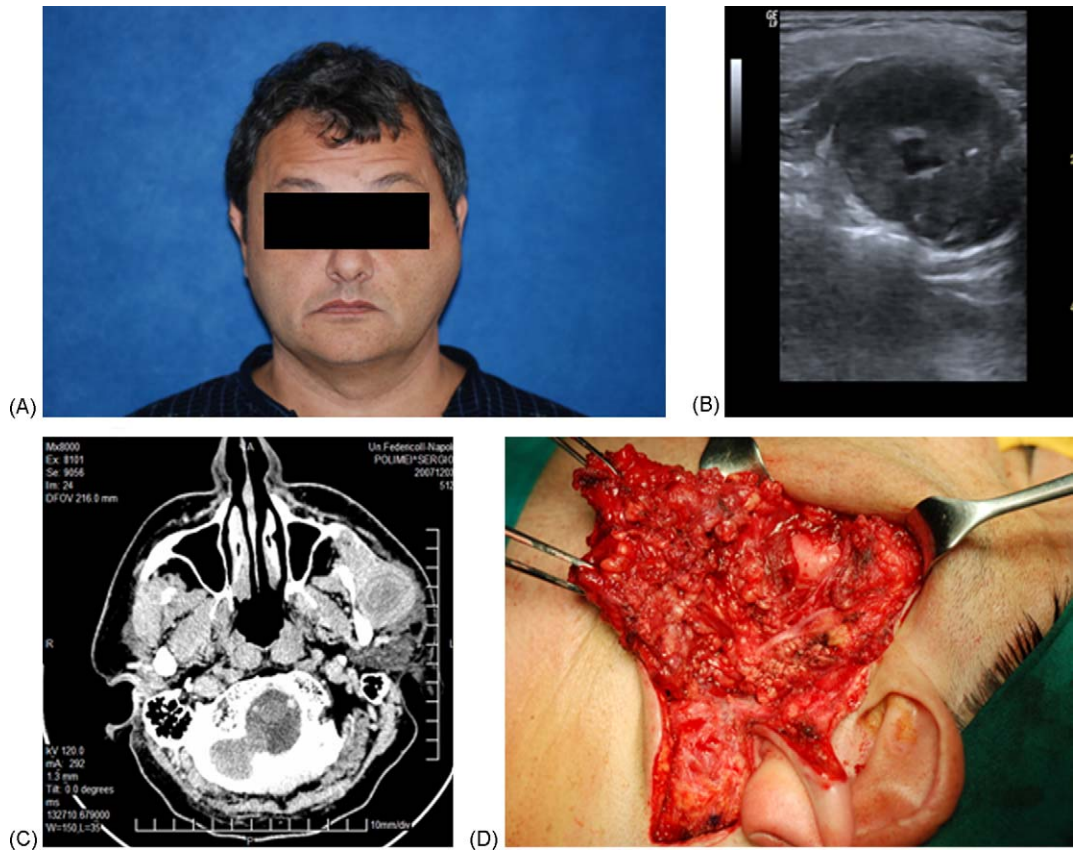


Fig. 1. (A) Clinical image showing swelling in the left preauricular region. (B) Ultrasound reveals a 4 cm intramuscular hypoechoic mass with calcifications. (C) CT image demonstrates a tumour mass in the left masseter muscle. (D) Intraoperative image shows a tumour within the masseter muscle.

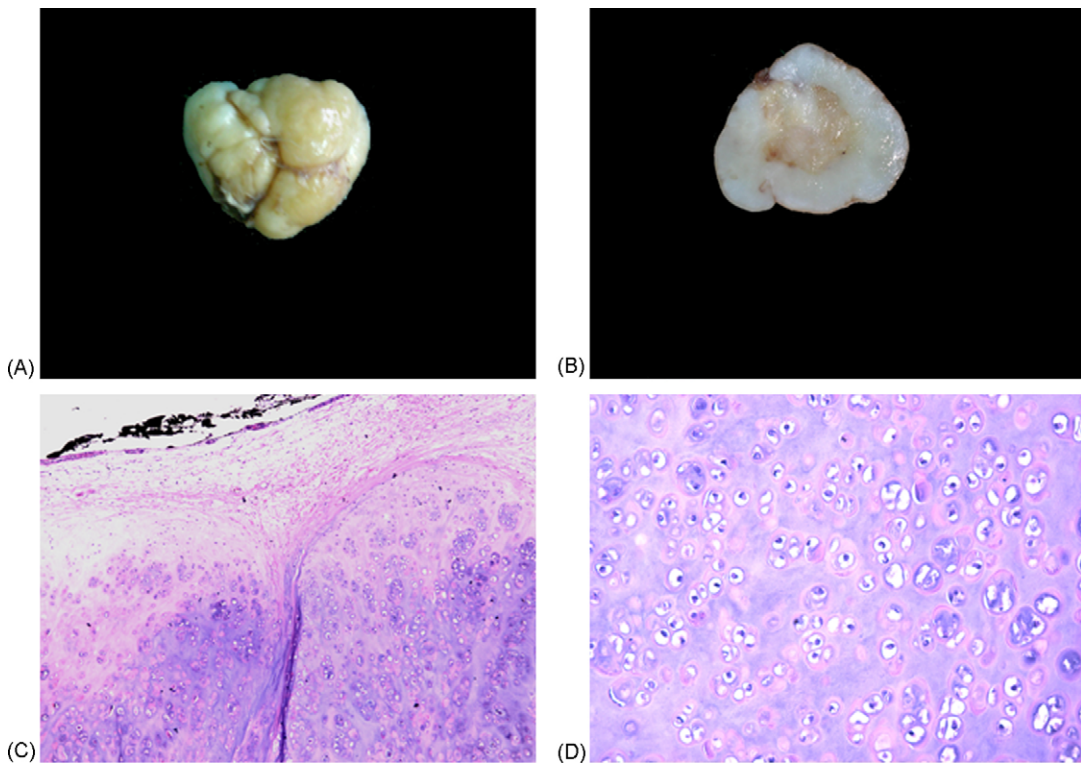


Fig. 2. (A) Gross appearance of the lesion showing a mass with an irregular outer surface and translucent cut section (B). (C) Lobules of hyaline mature cartilage surrounded by a thin fibrous capsule (H/E, 10x). (D) At high power, chondrocytic lacunae with mild atypia are evident (H/E, 20x).

Table 1. Review of literature on soft tissue chondroma of the head and neck.

Author	Age	Sex	Location	Duration of disease	Dimension (cm)	IHC
Bruce 1953 ⁵	NA	NA	Tongue	NA	NA	NA
Rosen 1961 ³¹	NA	NA	Tongue	NA	NA	NA
Yoel 1965 ⁴⁹	NA	NA	Tongue	NA	NA	NA
Ramachandran 1968 ²⁸	NA	NA	Tongue	NA	NA	NA
Hankey 1968 ¹⁶	60	F	Cheek	31 years	4x4x3	NA
Huppertz 1969 ¹⁸	26	F	Cheek	2 years	8x5x3	NA
Viglioglia 1970 ⁴⁴	NA	NA	Tongue	NA	NA	NA
Samant 1971 ³²	NA	NA	Tongue	NA	NA	NA
Gutmann 1974 ¹⁴	NA	NA	Tongue	NA	NA	NA
Zegarelli 1977 ⁵⁰	NA	NA	tongue	NA	NA	NA
del Rio 1978 ¹¹	NA	NA	Tongue	NA	NA	NA
Junqueira 1982 ²⁰	NA	NA	Tongue	NA	NA	NA
Yasuoka 1984 ⁴⁸	40	M	Tongue	NA	NA	NA
Segal 1984 ³⁶	NA	NA	Tongue	NA	NA	NA
	NA	NA	Tongue	NA	NA	NA
Sambo 1986 ³³	NA	NA	Tongue	NA	NA	NA
Ling 1986 ²³	NA	NA	Tongue	NA	NA	NA
Van der Wal 1987 ⁴²	61	F	Tongue	NA	NA	NA
Aguirre 1988 ¹	53	M	Tongue	NA	NA	NA
Tani 1989 ⁴¹	NA	NA	Tongue	NA	NA	NA
Ishibashi 1989 ¹⁹	79	F	Tongue	NA	NA	NA
Yamanaka 1989 ⁴⁷	20	F	Tongue	NA	1.50	NA
Sanchez-Aniceto 1990 ³⁴	61	M	Tongue	NA	NA	NA
Munro 1990 ²⁴	NA	NA	Tongue	NA	NA	NA
Kostopoulos 1993 ²²	32	M	Parotid gland	NA	NA	S-100+
Blum 1993 ⁴	60	F	Cheek	1 year	1	NA
Kamysz 1996 ²¹	5	F	Neck	9 months	NA	NA
Wang 1998 ⁴⁵	20	M	Parapharyngeal space	2 years	NA	NA
Sera 2005 ³⁷	17	M	Tongue	NA	NA	NA
Onodera 2005 ²⁶	47	F	Cheek	NA	4x2x2	S-100+, vim+
Aslam 2006 ³	47	F	Parotid gland	2 years	4x3x2	S-100+, vim+
De Riu 2007 ¹⁰	47	M	Masticatory space	NA	3.5	S-100+, vim+
Vazquez Mahia 2007 ⁴³	54	F	Preauricular region	4 years	2.5x2.5	NA
Scivetti 2008 ³⁵	51	F	Tongue	NA	0.5	S-100+
Present case	49	M	Masseter muscle	6 years	4	S-100+

IHC: immunohistochemistry; NA: not available; vim: vimentin.

cessed and serially sectioned but no epithelial components were observed. Immunohistochemically, the tumour cells were strongly positive for S-100 protein, and negative for smooth muscle and myoepithelial markers.

Discussion

The authors report a rare case of a primary benign cartilaginous tumour in the masseter muscle of a 49-year-old male of 6 years' duration. Extraskelatal chondromas are benign tumours arising in soft tissues unrelated to the bone.

The aetiology of soft tissue chondromas is unknown but it is thought that they arise from residual embryonic tissue or from metaplastic pluripotential mesenchymal cells^{10,39}. The tumour cells probably arise from uncommitted mesenchymal stem cells either by metaplastic or neoplastic processes. Theories about their origin vary, YASUOKA et al. suggested that tongue chondromas develop from residual embryonal tissue in an area of fetal cartilage, or from pluripotent mesenchy-

mal cells that undergo metaplasia and differentiate into cartilage as a result of an irritating stimulus^{15,48}. In the fallopian tube, the tumour could develop from the mesenchyme of the myosalpinx or subcoelomic mesenchyme of the tubal serosa³⁸. Chondromas and cartilaginous tumours have also been studied cytogenetically^{6,40}.

Chromosomal alterations are not random, but can be associated with specific tumour types and their location. Tallini et al. have found cytogenetic similarities and common occurrence of 12q13-15 or +5 alterations in synovial/parosteal or soft tissue chondromas strongly supporting the hypothesis of a common origin for all these lesions⁴⁰. Abnormalities of chromosomes 5, 6, 7 and 12, and of chromosomal regions 6q13, 12q13 and 17p13 are shared by malignant and benign cartilaginous tumours⁶.

The masseter muscle is located in the masticatory space. Chondromas arising in the masseter muscle are difficult to recognize clinically and can be mistaken for salivary gland tumours¹⁷.

Radiologically, soft tissue chondromas can show irregular calcification without involvement of underlying bone. The most common pattern of calcification is curvilinear, as in the present case¹⁵.

The present case was clinically and cytologically mistaken for a salivary gland tumour, although histologically a clear diagnosis of cartilaginous tumour was made. Even serially sectioned epithelial cells were not recognized. Although appearing benign, a full skeletal survey must be carried out to exclude a well-differentiated skeletal chondrosarcoma, which occasionally metastasises to skin. Well-differentiated extraskelatal chondrosarcoma is rare¹⁷. Ectomesenchymal chondromyxoid tumour^{2,25} must also be considered. It is most often described in the oral cavity², particularly in the tongue² but also in the hard palate²⁵. It is a well-circumscribed, but unencapsulated, lesion with a lobular growth pattern and various degrees of cellularity setting in a myxoid, chondroid or hyalinized background. Immunohistochemistry is useful because tumour cells are positive for antibodies

directed against glial fibrillary acidic protein, cytokeratins, S-100 protein and CD-57^{2,25}.

To the authors' knowledge, this is the first case of primary intramuscular chondroma arising in the masseter muscle. In two comprehensive reports of extraosseous chondroma the predominant location of this tumour was in the hands and feet^{8,9}.

A review of the literature on head and neck soft tissue chondromas (Table 1) disclosed 34 cases of soft tissue chondromas occurring in the head and neck region, of which 24 were in the tongue^{1,3,11,14,19-20,23-24,28,31-37,41-42,44,47,49-50}, 4 in the cheek^{4,16,18,26}, 2 in the parotid gland^{3,22}, 1 in the parapharyngeal space⁴⁵, 1 in the preauricular region⁴³, 1 in the neck²¹ and 1 in the masticatory space¹⁰. The age range of the patients was 5–79 years. Soft tissue chondroma is more common in females than in males (even though the patient's gender was not available in 16 cases) and the most common site is the tongue. The lesion has a slow and indolent course and occasionally is present for many years¹⁶. The treatment of choice is a wide local excision owing to the high recurrence rate of 10–15%¹⁵.

In conclusion, the authors have recorded a rare location for soft tissue chondroma of the head and neck region, clinically mistaken for a salivary gland tumour.

Competing interests

None declared

Funding

None

Ethical approval

Not required

References

- AGUIRRE JM, MARTINEZ-CONDE R, TANAGO JG, RIVERA POMAR JM. Chondroma of the tongue. Report of a case and review of the literature. *Int J Oral Maxillofac Surg* 1988; **17**: 285–287.
- ALLEN CM. The ectomesenchymal chondromyxoid tumor: a review. *Oral Dis* 2008; **14**: 390–395.
- ASLAM MB, HAQQANI MT. Extraskeletal chondroma of parotid gland. *Histopathology* 2006; **48**: 465–467.
- BLUM MR, DANFORD M, SPEIGHT PM. Soft tissue chondroma of the cheek. *J Oral Pathol Med* 1993; **22**: 334–336.
- BRUCE KW, McDONALD JR. Chondroma of the tongue. *Oral Surg Oral Med Oral Pathol* 1953; **6**: 1281–1283.
- BUDDINGH EP, NAUMANN S, NELSON M, NEFFA JR, BIRCH N, BRIDGE JA. Cytogenetic findings in benign cartilaginous neoplasms. *Cancer Genet Cytogenet* 2003; **141**: 164–168.
- CHANG SE, LEE MW, CHOI JH, SUNG KJ, MOON KC, KOH JK. A case of lingual chondroma. *Br J Dermatol* 1999; **141**: 773–774.
- CHUNG EB, ENZINGER FM. Benign chondromas of soft part. *Cancer* 1978; **41**: 1414.
- DAHLIN C, SALVADOR H. Cartilaginous tumors of the soft tissues of the hands and feet. *Mayo Clin Proc* 1974; **49**: 721.
- DE RIU G, MELONI SM, GOBBI R, CONTINI M, TULLIO A. Soft-tissue chondroma of the masticatory space. *Int J Oral Maxillofac Surg* 2007; **36**: 174–176.
- DEL RIO CE. Chondroma of the tongue: review of the literature and a case report. *J Oral Med* 1978; **33**: 54–56.
- FLETCHER CDM, UNNI KK, MERTENS F, eds: WHO Classification of tumors. Pathology and genetics of tumors of soft tissue and bone. Lyon: IARC Press 2002: 237–240.
- GARDNER DG, PATERSON JC. Chondroma or metaplastic chondrosis of soft palate. *Oral Surg Oral Med Oral Pathol* 1968; **26**: 601–604.
- GUTMANN J, CIFUENTES C, BALZARINI MA, SOBARZO V, VICUÑA R. Chondroma of the tongue. *Oral Surg Oral Med Oral Pathol* 1974; **37**: 75–77.
- HAN JY, HAN HS, KIM YB, KIM JM, CHU YC. Extraskeletal chondroma of the fallopian tube. *J Korean Med Sci* 2002; **17**: 276–278.
- HANKEY GT, WATERHOUSE JP. A calcifying chondroma in the cheek. *Br J Oral Surg* 1968; **5**: 239–244.
- HUMPHREYS S, PAMBAKIAN H, MCKEE PH, FLETCHER CD. Soft tissue chondroma—a study of 15 tumours. *Histopathology* 1986; **10**: 147–159.
- HUPPERTZ M. Rare case of chondroma formation in the parotid region. *HNO* 1969; **17**: 111–112.
- ISHIBASHI T, NOMURA Y, KOJIMABARA M. Chondroma of the tongue. *ORL J Otorhinolaryngol Relat Spec* 1989; **51**: 182–186.
- JUNGUEIRA HR, FIGUEIREDO HS, QUEIROZ HM. Chondroma of the tongue. *Arq Cent Estud Curso Odontol* 1982; **19**: 93–100.
- KAMYSZ JW, ZAWIN JK, GONZALEZ-CRUSSI F. Soft tissue chondroma of the neck: a case report and review of the literature. *Pediatr Radiol* 1996; **26**: 145–147.
- KOSTOPOULOS IS, DANILIDIS I, VELEGRAKIS G, PAPADIMITRIOU CS. Chondroma of the parotid gland. Clinical–histologic–immunohistochemical findings of a rare case. *Laryngorhinootologie* 1993; **72**: 261–263.
- LING KC. Chondroma of the tongue. *J Oral Maxillofac Surg* 1986; **44**: 156–158.
- MUNRO JM, SINGH MP. Chondroma of the tongue. Report of a case and a consideration of the histogenesis of such lesions. *Arch Pathol Lab Med* 1990; **114**: 541–542.
- NIGAM S, DHINGRA KK, GULATI A. Ectomesenchymal chondromyxoid tumor of the hard palate—a case report. *J Oral Pathol Med* 2006; **35**: 126–128.
- ONODERA K, XU H, KIMIZUKA S, ECHIGO S, OOYA K. Chondroma of the cheek: A case report. *Int J Oral Maxillofac Surg* 2005; **34**: 924–926.
- PASTOR E, ANDREU A, LLOMBART M, CHINER E. Pneumonia as a presentation of an endobronchial chondroma. *An Med Interna* 2004; **21**: 565–566.
- RAMACHANDRAN K, VISWANATHAN R. Chondroma of the tongue. Report of a case. *Oral Surg Oral Med Oral Pathol* 1968; **25**: 487–490.
- RAMOS MARTÍNEZ E, RODRÍGUEZ MOGUEL L, QUIJANO NAREZO M, SANTIAGO PAYÁN H. Primary chondroma of the ovary. Report of a case. *Ginecol Obstet Mex* 1983; **51**: 95–98.
- ROSAI J, ed: Rosai and Ackerman's Surgical Pathology. China: Mosby 2004: 2158.
- ROSEN MD. Chondroma of the tongue: report of case. *J Oral Surg Anesth Hosp Dent Serv* 1961; **19**: 157–159.
- SAMANT HC, GUPTA OP. Chondroma of the tongue. *Oral Surg Oral Med Oral Pathol* 1971; **32**: 450–452.
- SAMBO F, BRUNELLO A, CAPRI GA, CIVELLI M, PRIORE L, RATTO C. Chondroma of the tongue. A clinical case and review of the literature. *Minerva Stomatol* 1986; **35**: 821–825.
- SANCHEZ-ANICETO G, GARCIA-PEÑIN A, BALLESTIN C. Lingual chondroma. *Rev Stomatol Chir Maxillofac* 1990; **91**: 480–482.
- SCIVETTI M, MAIORANO E, PILOLLI PIETRO E, CORVAGLIA S, CIMMINO AM, LUCHESE A, FAVIA G. Chondroma of the tongue. *Clin Exp Dermatol* 2008; **33**: 460–462.
- SEGAL K, SIDI J, KATZAV Y, ROTEM A. Chondroma of the tongue. Report of two cases. *Ann Otol Rhinol Laryngol* 1984; **93**: 271–272.
- SERA H, SHIMODA T, OZEKI S, HONDA T. A case of chondroma of the tongue. *Int J Oral Maxillofac Surg* 2005; **34**: 99–100.
- SPANTA R, LAWRENCE WD. Soft tissue chondroma of the fallopian tube. Differential diagnosis and histogenetic considerations. *Pathol Res Pract* 1995; **191**: 174–176.
- SPIRO RH, GEROLD FP, STRONG EW. Mandibular “swing” approach for oral and oropharyngeal tumors. *Head Neck Surg* 1981; **3**: 371–378.
- TALLINI G, DORFMAN H, BRYNS P, DAL CIN P, DE WEVER I, FLETCHER CD, JONSON K, MANDAHN N, MERTENS F, MITELMAN F, ROSAI J, RYDHOLM A,

- SAMSON I, SCIOT R, VAN DEN BERGHE H, VANNI R, WILLÉN H. Correlation between clinicopathological features and karyotype in 100 cartilaginous and chordoid tumours. A report from the Chromosomes and Morphology (CHAMP) Collaborative Study Group. *J Pathol* 2002; **196**: 194–203.
41. TANI Y, AZUMA T, NAGAYAMA M. Chondroma of the tongue. *J Oral Maxillofac Surg* 1989; **47**: 91–92.
42. VAN DER WAL N, VAN DER WAAL I. Osteoma or chondroma of the tongue; a clinical and postmortem study. *Int J Oral Maxillofac Surg* 1987; **16**: 713–717.
43. VÁZQUEZ MAHÍA I, LÓPEZ-CEDRÚN CEMBRANOS JL, FERRERAS GRANADO J, LORENZO FRANCO F. Temporomandibular juxtaarticular chondroma: case report. *Med Oral Patol Oral Cir Bucal* 2007; **12**: 171–174.
44. VIGLIOGLIA PA, STIRPARO MA. Chondroma of the tongue. *Oral Surg Oral Med Oral Pathol* 1970; **29**: 820–826.
45. WANG DH, GUAN XL, XIAO LF, ZHANG XP, CHEN MG, SUN KM. Soft tissue chondroma of the parapharyngeal space: a case report. *J Laryngol Otol* 1998; **112**: 294–295.
46. WELLER CV. The incidence and histopathology of bone and cartilage in the tonsil. *Ann Otol Rhinol Laryngol* 1923; **32**: 687.
47. YAMANAKA T, FURUHASHI I, MORI T, NAKAMURA S, MURATA M, KAWARADA M, KANEHISA J, TAKEUCHI H, OKAMOTO Y, TOKUHIRO Y. Case report of chondroma of the tongue. *Gifu Shika Gakkai Zasshi* 1989; **16**: 681–686.
48. YASUOKA T, HANDA Y, WATANABE F, OKA N. Chondroma of the tongue. Report of a case. *J Maxillofac Surg* 1984; **12**: 188–191.
49. YOEL J, PUNDYK C. Chondroma of the tongue. *Oral Surg Oral Med Oral Pathol* 1965; **20**: 578–582.
50. ZEGARELLI DJ. Chondroma of the tongue. *Oral Surg Oral Med Oral Pathol* 1977; **43**: 738–745.

Address:
Luigi Insabato
Department of Biomorphological
and Functional Sciences
Pathology Section
University of Naples "Federico II",
via S. Pansini 5
80131
Naples
Italy
Tel.: +39 0817463442
Fax: +39 0817463475
E-mail: insabato@unina.it