

OPEN

Autologous Fat Grafting in Facial Volumetric Restoration

Piombino Pasquale, MD, PhD,* Marenzi Gaetano, DDS, PhD,[†]
Dell'Aversana Orabona Giovanni, MD, PhD,[‡] Califano Luigi, MD, DMD,[§]
and Sammartino Gilberto, MD, DMD^{||}

Abstract: The authors reported their surgical experience about structural fat grafting in the management of facial volumetric deficit. The purpose of this study was to assess the real indications, cosmetic results, complications, and global patient satisfaction of the Coleman technique in redefining facial contours in congenital and postoperative deformities. A retrospective analysis of 32 patients grafted according to Coleman's technique was performed, and the long-term outcomes and patient satisfaction were evaluated. The mean postoperative clinical follow-up was 14 months. The morphological changes were analyzed by comparing the photographic presurgical facial contour and the postoperative correction of soft tissue defects. All consecutive cases reported showed a progressive fat resorption for 3 months after surgery and its stable integration only after this period. Best results were performed in the treatment of genetically determined syndromes, such as the Franceschetti and Romberg syndromes. The authors suggest this surgical technique also for the treatment of unaesthetic cutaneous abscess cavity after incision and drainage. Unsatisfactory outcomes were obtained in the treatment of the posttraumatic facial scar, which needed more surgical procedures.

Key Words: Lipofilling, lipostructure, autologous fat grafting, facial asymmetry

(*J Craniofac Surg* 2015;26: 756–759)

The use of adipose tissue transfer for the correction of maxillofacial defects was first reported by Neuber and proposed for the aesthetic treatment of facial soft tissue deficiency.¹ This was based on the belief that fat is an ideal filler: natural, stable, and without the complications of the earlier fillers.² It is autologous and completely biocompatible, in most patients available in sufficient quantities, naturally integrated into the host tissue, removable if

necessary, and potentially permanent.³ The clinical success has been limited due to the lack of a real vascular connection between the fat grafting and the surrounding tissues in the receiving site. From that time, several surgical techniques have been described to improve the graft aesthetic result and its long-term survival.^{4–8} At the end of the 1980s, Coleman proposed an original fat grafting reported extensively in the literature as lipostructure: intact fat parcel, harvested with specific cannulas and centrifuged, were injected into multiple tissue planes other than just the subdermal space favoring the vascularization of the fatty tissue.^{2,9–11} The design of a new small blunt cannula, the fat centrifugation, has become the Coleman technique, an elective therapy of many craniofacial deformities.¹² In recent years, maxillofacial and craniofacial applications have been reported and described: localized tissue atrophy, tissue loss after trauma, post-tumor resection, congenital complex craniofacial deformities, burns, and hemifacial asymmetry (eg, Romberg syndrome, scleroderma).^{12–16} Recent studies have shown that human adipose tissue represents a rich source of adipose stem cells, featuring secretion of angiogenic and anti-apoptotic factors in animals.^{17,18} Some authors have reported the differentiation of adipose-derived cells into chondrocytes, myocytes, osteoblasts, and, most recently, neural progenitor cells.¹⁹ First introduced as a method for improving facial aesthetics, this has evolved into more complex reconstructive procedures to improve volumetric restoration. Many authors considered the Coleman technique an excellent surgical solution for facial reconstruction and re-contouring with natural and long-lasting results.^{4,20} The authors reported their experience in redefining facial contours in congenital and postoperative deformities with Coleman's technique.

PATIENTS AND METHODS

A retrospective evaluation was designed to analyze indications, cosmetic results, complications, graft viability, and global patient satisfaction. From February 2010 to July 2013, 32 consecutive patients (22 females and 10 males) with a facial asymmetry of the soft tissues after trauma, tumor resection, congenital deformities, and previous surgical treatment of abscess were screened to our Department (Table 1). This retrospective study was conducted in accordance to the requirements of Helsinki Declaration of 1975 as revised in 2008. The patients were verbally informed about the sample to be taken and gave their written consents. Preoperatively, a clinical and radiographic evaluation of the defect was performed; an accurate photographic documentation was also obtained (Figs. 1, 2, 3). All 32 patients selected were treated in general anesthesia. The fat was harvested from the abdomen in local anesthesia using 0.5% lidocaine with 1:200,000 epinephrine before going to the operating room. By grasping the skin, the surgeon lifts away the subcutis from the underlying structures, and after a small (about 2 mm) incision in the donor site, blunt cannulas, with a diameter of 1.5 mm, were inserted. With a gentle negative pressure, a different (70 to 180 mL) amount of fat was harvested in relation to the 3-dimensional facial defect. Coleman emphasizes the importance of centrifugation at 3000 rpm for 3 minutes to remove

From the *Ear Nose Throat Department, Second University of Naples, Naples, Italy; [†]Oral Surgery Division; [‡]Division of Maxillofacial Surgery; [§]Division of Maxillofacial Surgery; and ^{||}Oral Surgery Division, Department of Neurosciences, Reproductive and Odontostomatologic Sciences, University of Naples "Federico II", Naples, Italy. Received September 22, 2014.

Accepted for publication January 31, 2015.

Address correspondence and reprint requests to Dell'Aversana Orabona Giovanni, MD, PhD, Department of Neurosciences, Reproductive and Odontostomatologic Sciences, University of Naples "Federico II", Via Pansini, 5 80131 Naples, Italy; E-mail: gdorabon@yahoo.it

The authors report no conflicts of interest.

This is an open access article distributed under the terms of the Creative Commons Attribution-NonCommercial-NoDerivatives 4.0 License, where it is permissible to download and share the work provided it is properly cited. The work cannot be changed in any way or used commercially.

Copyright © 2015 by Mutaz B. Habal, MD

ISSN: 1049-2275

DOI: 10.1097/SCS.0000000000001663

TABLE 1. Population Demographics, Reason of Surgical Treatment, Time of Follow-Up, and Satisfaction of the Patients

No. Patients	Sex	Mean Age	Cause of Facial Defect	Mean Follow-Up	Satisfaction on VAS
3	Males	30	Trauma	15	9.3
2	Females	23	Scar	13	5.1
3	2M-1F	34	Post-mandibular resection	24	8.2
7	5M-2F	19	Franceschetti syndrome	10	9.4
8	6M-2F	25	Abscess	12	9.2
4	2M-2F	21	Rosenthal syndrome	13	8.5

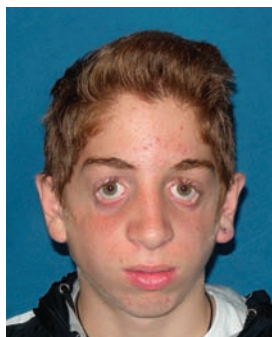


FIGURE 1. Preoperative frontal projection of a 15-year-old man affected by Franceschetti syndrome with the classic bilateral facial defects.

the non-living components (oil, blood, water, and lidocaine) from the suctioned aspirate.^{3,9,10} This procedure obtained highly purified fat tissue, preserving the integrity of the adipocyte wall but separating the fluid fat portion from the serous bloody part. This purified body fat was put in 1-mL syringes and aseptically re-injected using a 17-gauge blunt tip cannula. The cannula inserted through small skin incision (2 mm) layered the fat in small aliquots (0.1 mL) with a linear deposition into the facial area requiring enhancement working from the underlying periosteum up to the subdermis. All fat layers were grafted slowly from the deep to superficial layers trying to preserve fat cell survival and architecture. In the treatment of the posttraumatic facial scar, a release with blade of the scar contracture was obtained before. In post-surgery phase, aside from systemic antibiotic prophylaxis (1 g of amoxicillin, twice a day, for 7 days) in donor site, heparin (4000 IU) was locally administered and a compression dressing was applied. All patients were discharged 2 days after surgery without any adverse reactions. The mean postoperative clinical follow-up was 14 months. Postoperative photograph was performed at 1, 3, and 6 months. Patient satisfaction was evaluated using a Visual Analogue

Scale (VAS) ranging from 1 (least satisfied possible) to 10 (most satisfied possible) at 6 months after surgery.

RESULTS

The study comprised 32 patients, but only 27 completed the post-operative follow-up and we reported only their data; after the first follow-up, 5 (1 female and 4 males) patients were not available to continue the study. We analyzed the morphological changes by comparing the photographic presurgical facial contour and the postoperative correction of facial soft tissue deficits. Table 1 reports the indications for fat transfer. Due to its ease of access and availability, in all cases reported, the donor site was the abdominal wall. In all cases, no intraoperative complications can be referred. After 6 months post-surgery, in 21 cases, excellent integration of the new fat in the recipient sites was observed and a satisfactory aesthetic result was obtained (Figs. 4, 5). In 6 patients (2 facial scars, 2 Franceschetti syndromes, 1 post-mandibular resection, 1 zygomatic trauma) for assuring a satisfactory aesthetic result, it was necessary to suggest a second fat transfer (Fig. 6). In fact, after 6 months, in these patients, the graft showed a progressive resorption and an unaesthetic dispersion to the neighboring tissues. One patient did not give consent for a second surgical treatment (post-mandibular resection). The retrospective analysis of photographic documentation of all cases reported showed a progressive fat resorption for 3 months after surgery and its stable integration only after this period. Few post-surgery complications associated to autologous fat transfer were reported; in 7 cases, the recipient site presented edema and bruising minimized with an anti-inflammatory therapy (400 mg ibuprofen, 2 times daily, for 10 days). No infections or damages to underlying structures were reported.

High patient satisfaction was reported (8.2 average on VAS). Especially the patients with genetic syndromes evidenced their satisfaction after the surgical treatment. Also, the patients affected by facial deficit due to previous surgical treatment of dental abscess were very satisfied.



FIGURE 2. A 30-year-old woman with Romberg syndrome with the atrophy on the left side of the face. The preoperative frontal projection.

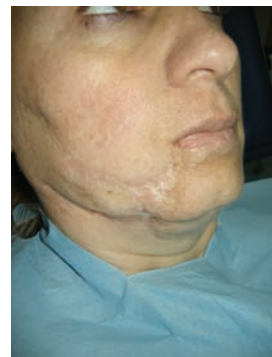

FIGURE 3. A 52-year-old woman with posttraumatic facial scar in the left hemimandibular region.

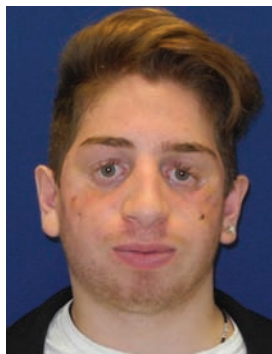


FIGURE 4. The facial aesthetic improvement 6 months after the Franceschetti syndrome surgical treatment.

DISCUSSION

Several authors promoted fat as an ideal filler: autologous, biocompatible, stable, in most patients available in sufficient quantities, naturally integrated, and easily removable if necessary.^{2,3,9-12} Some authors^{3,12} add that it is potentially permanent too, but others^{21,22} claim results are inconsistent and uncertain. From Coleman's technique, different approaches for fat harvesting, processing, and injection were suggested for improving the cosmetic outcome and graft survival.²²⁻²⁸ Recently, immunohistochemical studies of the extracellular matrix of the liposiphate showed the presence of adipose-derived stem cells.¹⁷⁻¹⁹

For its volumetric qualities and regenerative capacity, fat harvesting was suggested in many facial asymmetries: after trauma, post-tumor resection, congenital complex, and hemifacial asymmetry (Franceschetti and Romberg syndromes).^{4,13-16,29-34} Our best results, following the traditional Coleman technique, were performed in the treatment of genetically determined syndromes, such as the Franceschetti and Romberg syndromes. Autologous fat transportation appears, particularly indicated in complex reconstructive surgery, as a powerful tool to improve facial aesthetics.^{4,31-33} The patients expressed their satisfaction as reported in Table 1. Also, facial asymmetry after surgical therapy of dental abscess was treated with the same technique. In these clinical cases, the soft tissue deficit was limited and able to receive the harvested fat, improving the facial contour. Different satisfactory outcomes were obtained in the treatment of the posttraumatic facial scar, which needed more surgical procedures. In these cases, it was more difficult to assure an adequate fat subdermic reinjection and the aesthetic modeling of inextensible tissue appears more complex and unpredictable.³⁵



FIGURE 5. The postoperative facial aesthetic improvement 6 months after 2 Romberg syndrome surgical treatments.

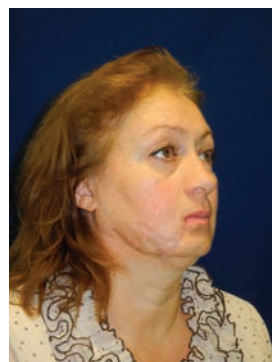

FIGURE 6. The low aesthetic improvement of the posttraumatic facial scar obtained 6 months after the second surgical treatment.

CONCLUSIONS

The authors suggest autologous fat grafting for the aesthetic treatment of many facial defects. Best results are reported in the treatment of genetically determined syndromes (Franceschetti, Romberg) and for unaesthetic cutaneous abscess cavity after incision and drainage. Unsatisfactory outcomes are reported in the treatment of the posttraumatic facial scar, which needed more surgical procedures.

REFERENCES

1. Neuber GA. Fettransplantation. *Chir Kongr Verhandl Dtsch Gesellsch Chir* 1893;22:66
2. Coleman SR. Structural fat grafts: the ideal filler? *Clin Plast Surg* 2001;28:111-119
3. Coleman SR. Structural fat grafting: more than a permanent filler. *Plast Reconstr Surg* 2006;118(3 Suppl):108-120
4. Clauser LC, Tienghi R, Consorti G. Parry-Romberg syndrome: volumetric regeneration by structural fat grafting technique. *J Craniomaxillofac Surg* 2010;38:605-609
5. Asken S. Autologous fat transplantation: micro and macro techniques. *Am J Cosmet Surg* 1987;4:111-121
6. Hudson DA, Lambert EV, Bloch CE. Site selection for fat autotransplantation: some observations. *Aesthetic Plast Surg* 1990;14:195-197
7. Billings EJ, May JJ. Historical review and present status of free fat graft autotransplantation in plastic and reconstructive surgery. *Plast Reconstr Surg* 1989;83:368-381
8. Allen RJ, Canizares O, Scharf C, et al. Grading liposiphate: is there an optimal density for fat grafting? *Plast Reconstr Surg* 2013;131:38-45
9. Coleman SR. Long-term survival of fat transplants: controlled demonstrations. *Aesthetic Plast Surg* 1995;19:421-425
10. Coleman SR. Facial recontouring with liposiphate. *Clin Plast Surg* 1997;24:347-367
11. Coleman SR. Structural fat grafting. *Aesthet Surg J* 1998;18:386-388
12. Arcuri F, Bruccoli M, Baragiotta N, et al. The role of fat grafting in the treatment of posttraumatic maxillofacial deformities. *Craniomaxillofac Trauma Reconstr* 2013;6:121-126
13. Mojallal A, Foyatier JL. The effect of different factors on the survival of transplanted adipocytes. *Ann Chir Plast Esthet* 2004;49:426-436
14. Clauser L, Sarti E, Dallera V, et al. Integrated reconstructive strategies for treating the anophthalmic orbit. *J Craniomaxillofac Surg* 2004;32:279-290
15. Clauser L, Polito J, Mandrioli S, et al. Structural fat grafting in complex reconstructive surgery. *J Craniofac Surg* 2008;19:187-191
16. Mojallal A1, Shipkov C, Braye F, et al. Influence of the recipient site on the outcomes of fat grafting in facial reconstructive surgery. *Plast Reconstr Surg* 2009;124:471-483
17. Aust L, Devlin B, Foster SJ, et al. Yield of human adipose derived adult stem cells from liposuction aspirates. *Cytotherapy* 2004;6:7-14
18. Strem BM, Hicok KC, Zhu M, et al. Multipotential differentiation of adipose tissue-derived stem cells. *Keio J Med* 2005;54:132-141

19. Kokai L, Rubin P, Kacey G. The potential of adipose derived adult stem cells as a source of neuronal progenitor cells. *Plast Reconstr Surg* 2005;116:1453–1460
20. Clauser L, Tieghi R, Mandrioli S, et al. Facial lipostructure in complex reconstructive surgery. *Riv Ital Chir Plast* 2005;37:75–79
21. Clauser LC, Tieghi R, Galiè M, et al. Structural fat grafting: facial volumetric restoration in complex reconstructive surgery. *J Craniofac Surg* 2011;22:1695–1701
22. De la Fuente A, Tavora T. Fat injections for the correction of facial lipodystrophies: a preliminary report. *Aesthetic Plast Surg* 1988;12:39–43
23. Ellenbogen R. Free autogenous pearl fat grafts in the face a preliminary report of a rediscovered technique. *Ann Plast Surg* 1986;16:179–194
24. Karacalar A, Orak I, Kaplan S, et al. No-touch technique for autologous fat harvesting. *Aesthetic Plast Surg* 2004;28:158–164
25. Kaufman MR, Miller TA, Huang C, et al. Autologous fat transfer for facial recontouring: is there behind the art? *Plast Reconstr Surg* 2007;119:2287–2296
26. Calabria R, Hills B. Fat grafting: fact or fiction? *Aesthet Surg J* 2005;25:55
27. Rohrich RJ, Sorokin ES, Brown SA. In search of improved fat transfer viability: a quantitative analysis of the role of centrifugation and harvest site. *Plast Reconstr Surg* 2004;113:391–395
28. Toledo LS. Syringe liposculpture. *Clin Plast Surg* 1996;23:683–693
29. Amar RE. Adipocyte microinfiltration in the face or tissue restructuration with fat tissue graft. *Ann Chir Plast Esthet* 1999;44:593–608
30. Guichard S, Arnaud E. Chirurgie reconstructrice des tissus mous dans les microsomies hemifaciales. *Ann Chir Plast Esthet* 2001;46:551–563
31. Onesti MG, Monarca C, Rizzo MI, et al. Minimally invasive combined treatment for Parry-Romberg syndrome. *Aesthet Plast Surg* 2009;33:452–456
32. Hoehnke C, Eder M, Papadopulos NA, et al. Minimal invasive reconstruction of post-traumatic hemi-facial atrophy by 3-D computer-assisted lipofilling. *J Plast Reconstr Aesthet Surg* 2007;60:1138–1144
33. Grimaldi M, Gentile P, Labardi L, et al. Lipostructure technique in Romberg syndrome. *J Craniofac Surg* 2008;19:1089–1091
34. Ye XD, Li CY, Wang C, et al. Superficial temporal fascial flap plus lipofilling for facial contour reconstruction in bilateral progressive facial hemiatrophy. *Aesthet Plast Surg* 2010;34:534–537
35. Guisantes E, Fontdevila J, Rodriguez G. Autologous fat grafting for unaesthetic scars correction. *Ann Plast Surg* 2012;69:550–554