

Facial osteomas: fourteen cases and a review of literature

G. DELL'AVERSANA ORABONA¹, G. SALZANO¹, G. IACONETTA²,
P. PIOMBINO¹, L. PONZO¹, A. SANTELLA¹, F. ASTARITA¹, D. SOLARI^{1,3},
F.A. SALZANO⁴, L. CALIFANO¹

¹Division of Maxillo-Facial surgery, Department of Neurosciences, Reproductive and Odontostomatological Sciences, Università degli Studi di Napoli Federico II, Naples, Italy

²Division of Neurosurgery, Università degli Studi di Salerno, Italy

³Division of Neurosurgery, Department of Neurosciences, Reproductive and Odontostomatological Sciences, Università degli Studi di Napoli Federico II, Naples, Italy

⁴Division of ENT surgery, Department of Surgery, Oncological and Odontostomatological Sciences, Università degli Studi di Palermo, Italy

Abstract. – OBJECTIVE: Osteomas are benign tumors that frequently affect the cranio-facial region, especially the temporal bones, jaw and sinus. This lesion very rarely involves the maxillary bones. The aim of our study is to describe our surgical case series and to evaluate the diagnosis and management of peripheral craniofacial osteomas with a review of the literature.

PATIENTS AND METHODS: We retrospectively analyzed a series of 14 patients that underwent surgery for the removal of a cranio-facial osteoma, 10 cases were peripheral osteoma of the lower jaw and 4 were peripheral osteomas of the upper jaw. The 14 patients included 8 females and 6 males, with a mean age of 42 years. The median follow up period was 48 months.

RESULTS: All patients received a total surgical removal and we did not have any intraoperative complications with optimal cosmetic and functional results. Pain resolved in all cases and a single case postoperative dysesthesia occurred. NO recurrence has been detected at last follow-up visit.

CONCLUSIONS: Osteomas must be well identified and differentiated from other solid diseases of the bone and should be treated if symptomatic. The elective treatment is surgical removal, resulting in a complete resolution of the pathology.

Key Words:

Craniofacial osteoma, Peripheral osteoma, Gardner's syndrome.

Introduction

Osteomas are benign tumors that could affect the cranio-facial region, especially the temporal bones, jaw and sinuses. This tumor may consist of

a composed, compact or cancellous bone cells, being solitary or multiple, especially when presenting into Gardner's syndrome¹. Usually 3 types of osteomas could be identified: (1) the central osteoma arising from the endosteum; (2) the peripheral osteoma deriving from the periosteum and (3) the extraskeletal soft tissue osteoma, which usually develops within the muscles². Clinically most of the lesions are asymptomatic, but in some cases they can cause pain, trismus (when also the nerve is involved) limited mandibular movements, occlusion disturbances, and facial asymmetry, especially when the mandibular condyle is involved³. Usually, an osteoma is diagnosed when it appears clearly visible at inspection or it can be incidentally discovered at Opx or facial CT exams. At radiological exams this lesion figures out as an oval radiopaque⁴ mass, well-circumscribed, attached by a broad base or pedicle to the bone cortex (mushroom-like mass)^{5,6}. Histological classification differentiates between two types of osteomas: compact osteomas or "ivory" are made of mature lamellar bone and they do not harvest any fibrous component. On the other side, trabecular osteomas are composed of cancellous trabecular bone with bone-marrow surrounded by a cortical bone margin^{3,5-10}. In the pertinent literature there have been described 132 cases of osteomas of the craniofacial region and most of these were localized in the mandibular or frontal regions, whereas appeared to be a rare entity in maxillary bones⁵⁻¹⁰.

The aim of our study is to describe the variable clinical presentation, diagnosis and management of a series of 14 cases that underwent surgical removal of an osteoma of the maxillary bones, along with a review of the literature.

Patients and Methods

We analyzed a series of 14 patients, 8 women and 6 men with a mean age of 42 years (range 26 and 64 years), with an osteoma of the cranio-facial region, treated surgically at the Maxillofacial Surgery Department of the University Federico II of Naples, between May 2000 and March 2010. The series consisted of 10 peripheral osteomas of the lower mandibular bone and 4 were peripheral osteomas of the maxillary bone (Table I). All patients complained of local pain. Opx and a CT were performed to rule out the diagnosis. Pathological report confirmed diagnosis of osteomas lining out 9 cases of compact hysto-type and 5 of cancellous hystotype. Mean follow-up was of 48 months (range). We herein report the three most representative cases.

Results

All patients underwent intraoral approach for the removal of an osteoma of the maxillary bones; total removal of the lesion was achieved in all cases. Of the 14 cases of our series, 3 involved the mandibular angle area, 7 the anterior body, 4 the alveolar processes. Pain completely resolved immediately after surgery in all cases, as well as all mouth opening functional limitations. Nine patients out of the eleven (9/11, 81.8%) presenting preoperatively facial swelling had complete cosmetic and functional recovery, whilst all patients with facial asymmetry had complete restoration. We did not report any intraoperative complication, whereas transient

dysesthesia of the right V3 branch of the trigeminal nerve occurred postoperatively in a single case (1/14, 7.14%) presenting osteoma of the right mandible angle area. There were no recurrences at last follow up visit of 4 years.

Illustrative Cases

Case 1

A 26-year-old male patient was complaining of pain in the right half mandible since 5 years and presented swelling of the right posterior cheek. An Opx and a CT scan (Figure 1 A-B) showed the presence of a thickened bony area occupying the right mandibular angle. There were no symptoms or neurologic defects related to the lesion and there were no other lesions in the facial or cranial bones. The patient underwent surgical removal of the neoplasia. The surgical approach accounted on an intra-oral route in order to maximize the cosmetic result (Figure 1 C). An immediate postoperative Opx (Figure 1 D) confirmed the complete removal of the pathology. Two days after surgery dysesthesia along the right V3 branch of the trigeminal nerve occurred: steroid therapy along with B group vitamins support was administered and after two months symptoms totally relieved. Pathology report disclosed a diagnosis consistent with an osteoma of compact type.

Case 2

A 54 yo male patient noted the presence of two lesions growing in right maxilla and started complaining of pain seven months prior to hospi-

Table I. Clinical data of the fourteen patients with osteomas of our series.

Case	Age/Sex	Location	Size (cm)	Presenting sign	Complications	Outcome
1	54/F	Right maxilla (2 lesions)	1.5-1.7	Pain	None	Complete recovery
2	26/M	Right mandible angle	2.3	Swelling	V3 dysesthesia	Complete recovery
3	26/F	Right TMJ	2.0	Swelling	None	Persistency of swelling
4	64/M	Anterior body	3.4	Facial asimmetry	None	Complete recovery
5	39/F	Anterior body	2.5	Pain	None	Complete recovery
6	37/F	Anterior body	2.6	Swelling	None	Complete recovery
7	46/M	Left mandible condyle	1.0	Swelling	None	Complete recovery
8	49/M	Right mandible condyle	1.5	Swelling	None	Complete recovery
9	57/F	Alveolar process	1.2	Swelling	None	Complete recovery
10	29/F	Left mandible angle	1.1	Pain	None	Complete recovery
11	39/F	Alveolar process	2.6	Swelling	None	Persistency of swelling
12	61/M	Alveolar process	3.1	Facial asimmetry	None	Complete recovery
13	28/F	Left mandible angle	3.8	Swelling	None	Complete recovery
14	39/M	Alveolar process	2.5	Swelling	None	Complete recovery

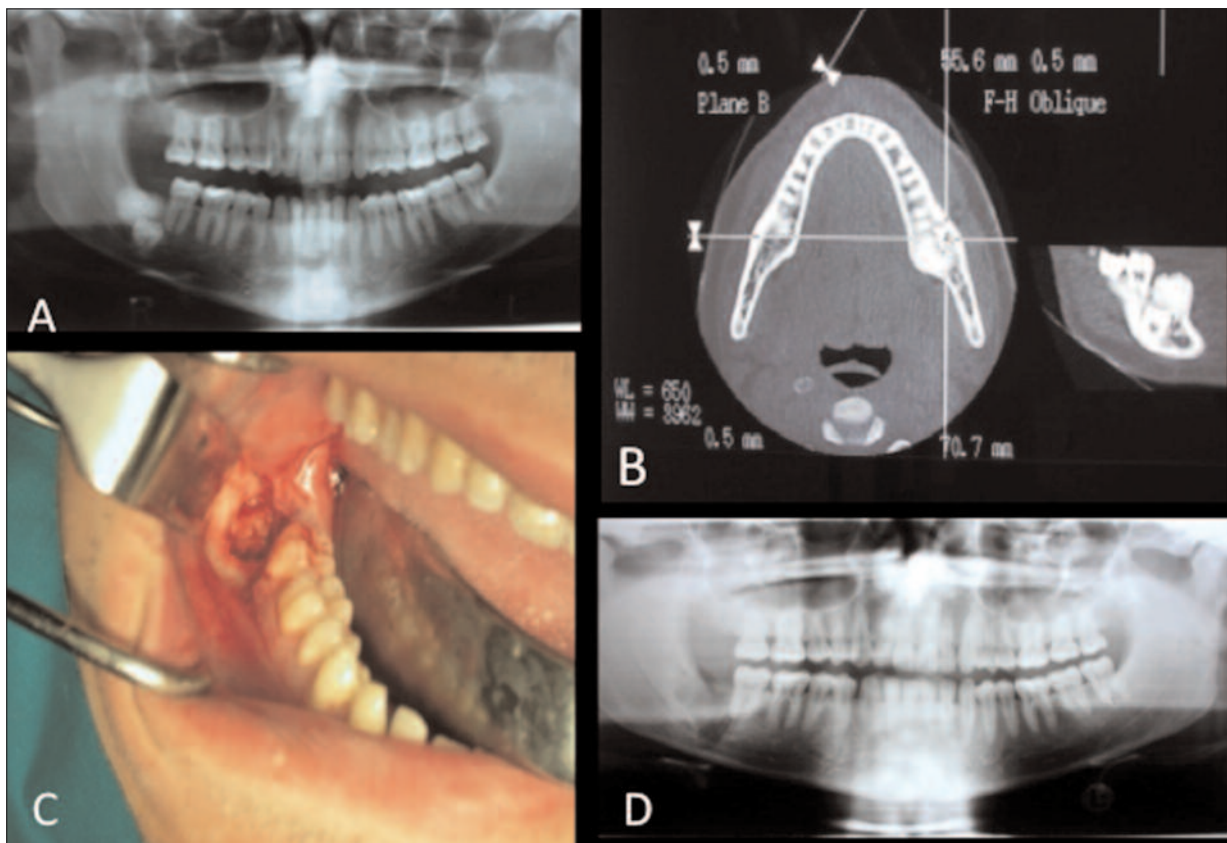


Figure 1. *A*, Pre-operative Opx showing radiolucent area at right mandible angle. *B*, Pre-operative CT scan showing an hyperosteoitic lesion in the right mandibular angle. *C*, Intraoperative image revealing the exposure of the lesion via an intraoral approach. *D*, Post-operative Opx showing the empty area after tumor removal.

tal admission; no facial asymmetry was clinically visible. Suddenly, he noted increase of thickness on both sides of the upper jaws. CT scan showed two hyperdense lesions at level of lateral arches of the upper jaws (Figure 1 A-B). Both lesions (Figure 2 C-D) were completely removed via an intraoral approach at the same time (Figure 2 E-F). Histological examination showed osteoma of compact type for both. The postoperative course was uneventful and at the 48-month follow up the areas healed.

Case 3

A female patient, aged 26, was referred to our department complaining of diffuse pain at right Temporo-mandibular joint area, associated with local swelling. Opx and CT scans ruled out a bony lesion involving the outer aspect of the right ascending branch of the mandible (Figure 3 A-B). Intraoral approach was adopted to completely remove the lesion (Figure 3 C). No intraoperative complication occurred; although pa-

tient was relieved from pain immediately, facial swelling did not improve (Figure 3 D). At last follow up recurrence was not detected and swelling was noted.

Discussion

Osteoma is a benign, slow growing lesion that could affect the craniofacial region very rarely; indeed, to our knowledge, 132 cases of osteoma of the jaws have been reported in the pertinent literature^{3,5-36,38,40,41}. Females present a higher incidence rate, with no predilection for any specific age range. Concerning the etiopathogenesis there are several theories, which received some credit along the years. It has been pointed out that they could be congenital²⁹⁻³¹, develop as neoplastic mass or, more likely, as inflammatory lesions^{3,32}. However, a common path underlying the developmental process of osteomas has been recognized: it has been supposed that a combination of a trauma and muscle activity can initiate an osteogenic

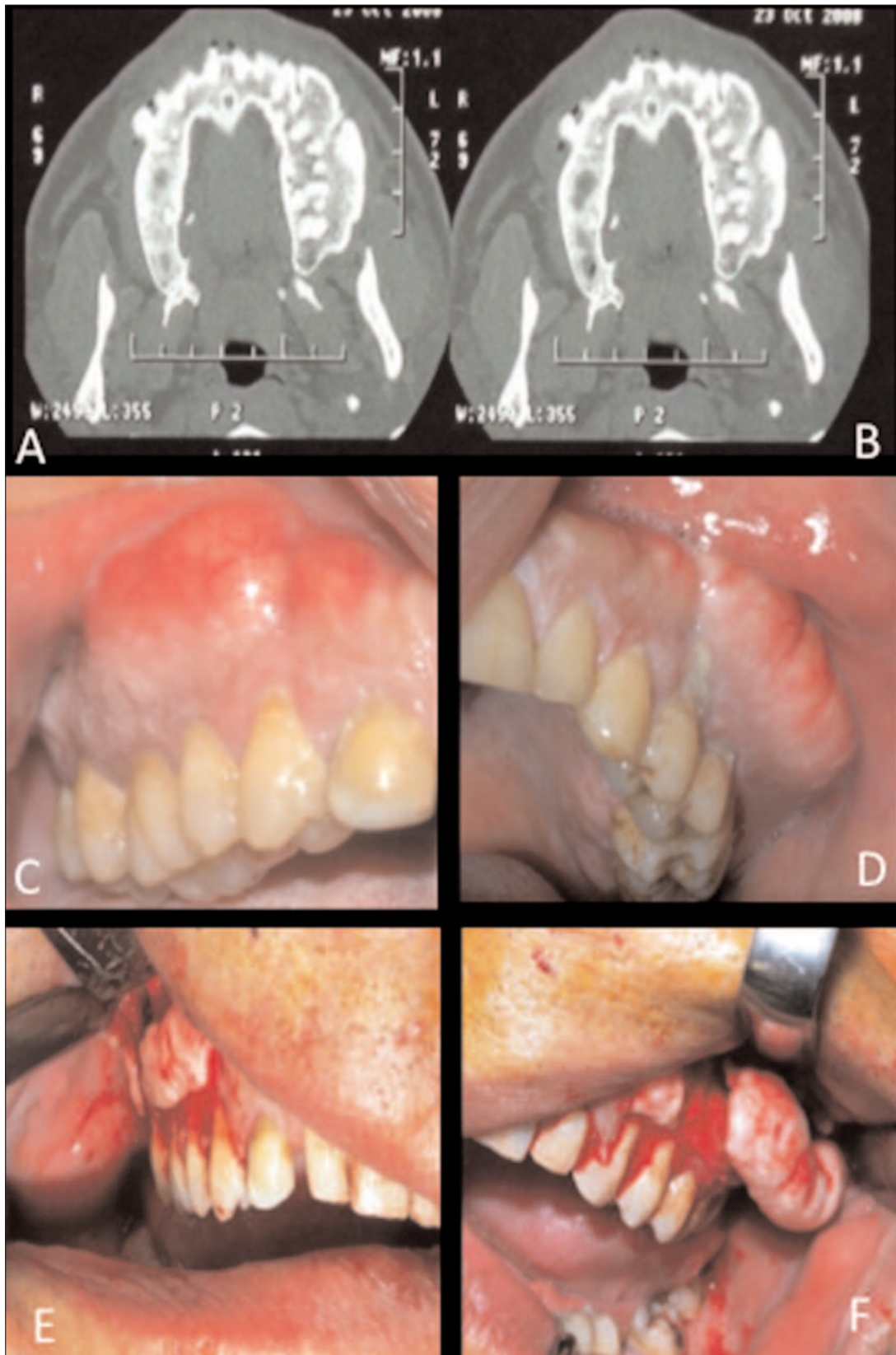


Figure 2. *A, B*, CT scan showing two hyperdense bony lesions in the upper jaw. *C, D*, Pre-operative image of intraoral mucosa distorted by lesions in both sides. *E, F*, Intra-operative image showing the exposure of the lesions: both appear exofitic tumors.

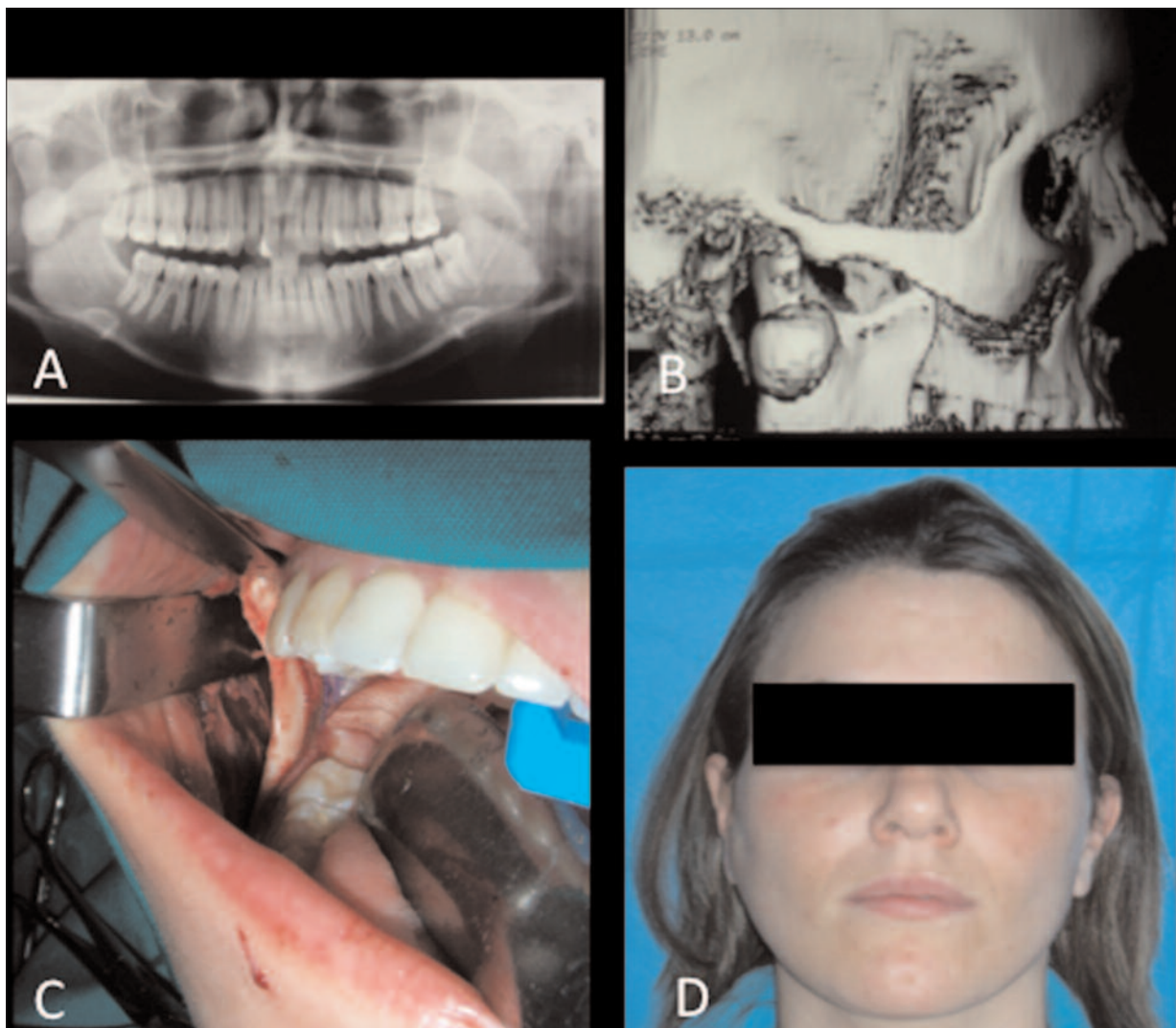


Figure 3. *A*, Pre-operative Opx showing radiolucent area at right mandible angle. *B*, Pre-operative CT (3D rendering of 1 mm thin-slice scan) showing a round mass at the level of the ascending branch of the mandibular bone. *C*, Intra-operative image: intraoral approach was performed to expose the outer aspect of the right mandibular ramus. *D*, Post-operative image of the patient that did not recover completely from facial swelling.

reaction. Usually these lesions are diagnosed when they become visible or figure out with local pain; on the contrary they can be incidentally discovered at radiological examination³³⁻³⁵. Differential diagnosis should take into account several inflammatory and neoplastic pathologic entities, such as exostosis, chronic focal sclerosing osteomyelitis, ossifying fibroma, chondroma, osteosarcoma, Paget's disease, fibrous dysplasia and odontoma³⁶. Osteomas can be classified as central or peripheral; they occur mostly in the head and neck region, often involving the paranasal sinuses, above all the frontal sinuses. The peripheral osteomas have been described in

the jaw bones, but this localization seems very uncommon. Aside from those lesions reported as entities of Gardner's syndrome, peripheral osteomas of the jaws account for 69 cases³. 63 of them were located in the mandibular bones. Concerning site of origin, there is a certain predilection for the mandibular body (4 cases anterior region, posterior region 19 cases), followed by the condyle (18 cases), the angle (9 cases), ascending ramus (7 cases), coronoid process (5 cases) and sigmoid notch (1 case)³. On the other hand, of the 6 osteomas of the upper jaw, 4 were involving the alveolar process and 2 in the hard palate¹². The patients in our series presented sim-

ilar distribution with 10 cases involving the lower jaw and only 4 the upper jaw. The most common symptom was local pain, although we noticed further symptoms such as headache, facial asymmetry, limited mouth opening and trismus³, which seldom appeared in the literature. These symptoms have to be directly related to the “mass effect” of the lesion impinging vital structures³⁷. Accordingly, a flow chart for osteoma treatment could be drawn: when the osteoma determines cosmetic disfigurement, limitations or loss of functions, it shows significant volume increase, cogent symptomatology, and/or severe pain refractive to medical therapy should be treated surgically. On the other side, when asymptomatic, there is no univocal consensus in regards¹², with little more evidence in favor of watchful waiting. Indeed, there are no reports of malignant transformation of a peripheral osteoma^{5,39-41}. Surgical treatment should account on radical surgical removal, extended also to the surrounding normal bone^{3,25}, with the intraoral approach being preferred for aesthetic reasons and the extraoral reserved for those larger tumors, when a larger exposure is required³⁸. As a matter of facts, the occurrence of several complications could overburden this surgery. Indeed, in our series a very prolonged V3 branch dysesthesia occurred although the patient underwent a very accurate preoperative work-up and a cautious intra-operative dissection was carried out.

In these regards, thanks to recent technological advances, it should be advisable to have a high quality CT scan prior than the surgical procedure¹¹ in order to rule out pearly all anatomical spatial relationships and eventual keypoints. Furthermore, recent literature reports the advantages of the use of piezo-surgery in the dissection of these lesions. Piezo-surgery allows removal of the bone without any damaging to soft tissues and nerves, reducing post-operative pain, dysesthesia and swelling⁴²⁻⁴⁶.

Finally, it should be reminded that recurrence are very rare, with a single case occurred 9 years after the surgical treatment, described by Bosshardt et al⁷. Over a mean follow up of 48 months we did not report any recurrence.

Conclusions

Craniofacial osteomas are more frequent in the mandible, with no predilection for any specific age range. In this area, they mainly occur in the

body, condyle, angle, ascending ramus, coronoid process and sigmoid notch. These tumors must be differentiated from other diseases of the bone and should be treated surgically, when symptomatic, minding the functional and aesthetic results.

Conflict of Interest

The Authors declare that there are no conflicts of interest.

References

- 1) GARDNER EJ, PLENK HP. Hereditary pattern for multiple osteomas in a family group. *Am J Hum Genet* 1952; 4: 31-36.
- 2) BODNER L, GATOT A, SION-VARDY N, FLISS DM. Peripheral osteoma of the mandibular ascending ramus. *J Oral Maxillofac Surg* 1998; 56: 1446-1449.
- 3) KAPLAN I, CALDERON S, BUCHNER A. Peripheral osteoma of the mandible: A study of 10 new cases and analysis of the literature. *J Oral Maxillofac Surg* 1994; 52: 467-470.
- 4) REGEZI JA, SCIUBBA J. *Oral Pathology* (2nd ed). Philadelphia, PA, Saunders, 1993; p. 407.
- 5) KASHIMA K, RAHMAN OIF, SAKODA S, SHIBA R. Unusual peripheral osteoma of the mandible: report of 2 cases. *J Oral Maxillofac Surg* 2000; 58: 911-913.
- 6) SAYAN NB, COOK C, KARASU HA, GUNHAU O. Peripheral osteoma of the maxillofacial region: a study of 35 new cases. *J Oral Maxillofacial Surg* 2002; 60: 1299-1301.
- 7) BOSSHARDT L, GORDON RC, WESTERBERG M, MORGAN A. Recurrent peripheral osteoma of mandible: report of a case. *J Oral Surg* 1971; 29: 446-450.
- 8) SCHNEIDER LC, DOLINSKY HB, GRODJESK JE. Solitary peripheral osteoma of the jaws: Report of a case and review of literature. *J Oral Surg* 1980; 38: 452-455.
- 9) KONDOH T, SETO K, KOBAYASHI K. Osteoma of the mandibular condyle: report of a case with a review of the literature. *J Oral Maxillofac Surg* 1998; 56: 972-979.
- 10) LARREA-OYARBIDE N, VALMASEDA-CASTELLON E, BERINI-AYTES L, GAY-ESCOODA C. Osteomas of the craniofacial region. Review of 106 cases. *Oral Pathol Med* 2008; 37: 38-42.
- 11) DEL BALSAMO AM, WERNING JT. The role of computed tomography in the evaluation of cemento-osseous lesions. *Oral Surg Oral Med Oral Pathol* 1986; 62: 354-357.
- 12) JOHANN AC, DE FREITAS JB, DE AGUIAR MC, DE ARAÚJO NS, MESQUITA RA. Peripheral osteoma of the mandible: case report and review of the literature. *J Craniomaxillofac Surg* 2005; 33: 276-281.
- 13) BIRKHOLZ H. Periosteal osteoma. *Oral Surg Oral Med Oral Pathol* 1980; 50: 384.

- 14) YASSIN OM1, BATAINEH AB, MANSOUR MJ. An unusual osteoma of the mandible. *J Clin Pediatr Dent* 1997; 21: 337-340.
- 15) WEINBERG S. Osteoma of the mandibular condyle: report of case. *J Oral Surg* 1977; 35: 929-932.
- 16) WANG-NORDERUD R, RAGAB RR. Osteoma of the mandibular condyloid process. Case report. *Scand J Plast Reconstr Surg* 1976; 10: 77-81.
- 17) THOMA KH. Case 39: osteoma of mandible. *AM J Orthodont* 1944; 30: 234-238.
- 18) SEYMOUR RA. Osteoma of the condyle. *Oral Surg Oral Med Oral Pathol* 1981; 52: 223.
- 19) SEWARD MHE. An osteoma of the maxilla. *Br Dent J* 1965; 5: 27-30.
- 20) BRANDON SA. Osteoma of the mandible. *J Oral Surg* 1950; 8: 153-154.
- 21) ORD RA, RENNIE JS, MACDONALD DG, MOOS KF. Cancellous osteoma of the coronoid process: report of a case. *Br J Oral Surg* 1983; 21: 49-55.
- 22) NOREN GD, ROCHE WC. Huge osteoma of the mandible: report of case. *J Oral Surg* 1978; 36: 375-377.
- 23) NELSON DF, GROSS BD, MILLER FE. Osteoma of the mandibular condyle: report of case. *J Oral Surg* 1972; 30: 761-763.
- 24) MACLENNAN WD, BROWN RD. Osteoma of the mandible. *Br J Oral Surg* 1974; 12: 219-224.
- 25) CUTILLI BJ, QUINN PD. Traumatically induced peripheral osteoma. Report of a case. *Oral Surg Oral Med Oral Pathol* 1992; 73: 667-669.
- 26) FICKLING BW. Osteoma of mandible. *Proc R Soc Med* 1951; 44: 56-57.
- 27) KURITA K, KAWAI T, IKEDA N, KAMEYAMA Y. Cancellous osteoma of the mandibular coronoid process: report of a case. *J Oral Maxillofac Surg* 1991; 49: 753-756.
- 28) GREEN AE, BOWERMAN JE. An osteoma of the mandible. *Br J Oral Surg* 1974; 12: 225-228.
- 29) PELO S, SPOTA A, GORI P, GIULIANI G. Osteomas of the facial massif. *Minerva Stomatol* 1988; 37: 875-886.
- 30) ALAERTS J. 2 cases of ethmoido-frontal osteoma. *Acta Otorhinolaryngol Belg* 1972; 26: 294-302.
- 31) BARAGLIA M, UNGARI L, PESUCCI B, PONTI G, CORBI S, SECONDARI C. Osteomas of the mandibular condyle. A case report of particular surgical interest. *Minerva Stomatol* 1985; 34: 275-278.
- 32) DUBIN J, BORNHAUSER X, DESNOS J. Osteoma of the paranasal sinuses. *J Fr Otorhinolaryngol Audiophonol Chir Maxillofac* 1977; 26: 573-589.
- 33) SKOLNICK IM. Osteoma of the mandible. A case report. *N Y State Dent J* 1972; 38: 9-14.
- 34) PIATTELLI A, SCARANO A, DI ALBERTI L, PIATTELLI M. Osteoma of the mandible. A case report. *Acta Stomatol Belg* 1995; 92: 13-16.
- 35) DISPENZA C, SARANITI C, FERRARA S, MARTINES F, CARAMANNA C, SALZANO FA. Frontal sinus osteoma and palpebral abscess: case report. *Rev Laryngol Otol Rhinol (Bord)* 2005; 126: 49-51.
- 36) DEL VECCHIO A, AGRESTINI C, SALUCCI P, MANICONE AM, DELLA ROCCA C. Osteomas and exostoses of the facial structures: a morphological study and the etiopathogenetic considerations. *Minerva Stomatol* 1993; 42: 533-540.
- 37) ELLER R, SILLERS M. Common fibro-osseous lesions of the paranasal sinuses. *Otolaryngol Clin North Am* 2006; 39: 585-600.
- 38) LONGO F, CALIFANO L, DE MARIA G, CICCARELLI R. Solitary osteoma of the mandibular ramus: report of a case. *J Oral Maxillofac Surg* 2001; 59: 698-700.
- 39) AGHABEIGI B, EVANS AW, CREAN SJ, HOPPER C. Simultaneous repair of an orbital floor fracture and removal of an ethmoid osteoma: case report and review of the literature. *Int J Oral Maxillofac Surg* 2003; 32: 94-96.
- 40) SWANSON KS, GUTTU RL, MILLER ME. Gigantic osteoma of the mandible: report of a case. *J Oral Maxillofac Surg* 1992; 50: 635-638.
- 41) SAYAN NB, UÇOK C, KARASU HA, GÜNHAN O. Peripheral osteoma of the oral and maxillofacial region: a study of 35 new cases. *J Oral Maxillofac Surg* 2002; 60: 1299-1301.
- 42) SALAMI A, DELLEPIANE M, SALZANO FA, MORA R. Piezosurgery in the excision of middle-ear tumors. Effects on mineralized and non-mineralized tissues. *Med Sci Monit* 2007; 13: P125-129.
- 43) DELLEPIANE M, MORA R, SALZANO FA, SALAMI A. Clinical evaluation of piezoelectric ear surgery. *Ear Nose Throat J* 2008; 87: 212-216.
- 44) SALAMI A, DELLEPIANE M, SALZANO FA, MORA R. Piezosurgery in endoscopic dacryocystorhinostomy. *Otolaryngol Head Neck Surg* 2009; 140: 264-266.
- 45) CRIPPA B, SALZANO FA, MORA R, DELLEPIANE M, SALAMI A, GUASTINI L. Comparison of postoperative pain: piezoelectric device versus microdrill. *Eur Arch Otorhinolaryngol* 2011; 268: 1269-1282.
- 46) YANG BE, GIROD S. Efficacy of bone healing in calvarial defects using piezoelectric surgical instruments. *J Craniofac Surg* 2014; 25: 149-153.