

Neodymium: Yttrium-Aluminum-Garnet Long Impulse Laser for the Elimination of Superfluous Hair: Experiences and Considerations from 3 Years of Activity

G.A. Ferraro, M.D., Ph.D., A. Perrotta, M.D., F. Rossano, M.D., and F. D'Andrea, M.D.

Naples, Italy

Abstract. This study examined the results obtained with a modern apparatus for laser hair removal (neodymium: yttrium-aluminum-garnet [Nd:YAG] laser at long impulses with a wave-length of 1,064 nm; Q-switched laser) over a follow-up period of 3 years. A large heterogeneous group of 480 patients was taken into consideration. These patients were treated according to a standard protocol with monthly checkups and a personalized protocol at deferred appointments. The results, discovered by means of the most objective procedure possible, were retrieved and put into a graph showing two different curves for the repopulation of hair. In their clinical travels, the authors observed an average variable regrowth of 40% to 65%, allowing them to affirm that laser hair removal using Nd:YAG at long impulses is decisively efficient in obtaining long-term results. The use of a protocol (denominated “prolonged monthly checkup”) with laser sessions at ever-decreasing periods permits, among other things, more outstanding and advantageous results for the patient. Thanks to more efficiently synchronized phases of the biologic hair cycle, this shortens and moves the telegenic phases closer and also renders the anagenic phases (those in which the selective photoermolysis on the pilipheric follicle proves to be efficient) more efficient. Personalization of the treatment relative to the monthly health checkup sessions is of fundamental importance to the scope of obtaining the best results in terms of cost–benefit rate, provided submassimal fluxes are (i.e., those well-tolerated by the patient) used. All this allows hair removal that is not definitive, but which becomes progressively permanent (i.e., characterized by ever-growing periods of lack of hair sustained by sporadic

maintenance laser sessions based on the individual’s necessity).

Key words: Hair removal—Laser hair removal—Long-term epilation

Laser hair removal was introduced recently in Italy, prompting much fuss from the beginning. Presented as the first hair removal method of medical interest capable of resolving the problem of superfluous hair in a definitive manner, it instantly interested multitudes of dermatologists as well as aesthetic and plastic surgeons [6].

The costs are not exactly cheap for the laser apparatus and relative treatments. It also is difficult to manage a patient who could be potentially dissatisfied, but laser hair removal has nevertheless focused the attention of surgeons on the real efficiency of these treatments in comparison with other methods (e.g., diadermocoagulation). The laser procedure has been elevated to the range of scientific methods of exclusive medical relevance.

Actually, laser hair removal, together with other aesthetic parasurgical treatments that apply a band of light at a high energy level (e.g., laser resurfacing, photocoagulation lasers of vascular fissures, laser rejuvenation) can be considered a useful method for completing the activities of the modern plastic and aesthetic surgeon.

The real problem with the modern laser apparatus (e.g., neodymium: yttrium-aluminum-garnet [Nd:YAG], “alessandrite,” Ruby, Diodes) for the elimination of superfluous hair is not really in the immediate efficiency or rapidity of the treatment, but rather in the interval required to reach a “definitive” hair removal or at least a “progressively permanent” one.

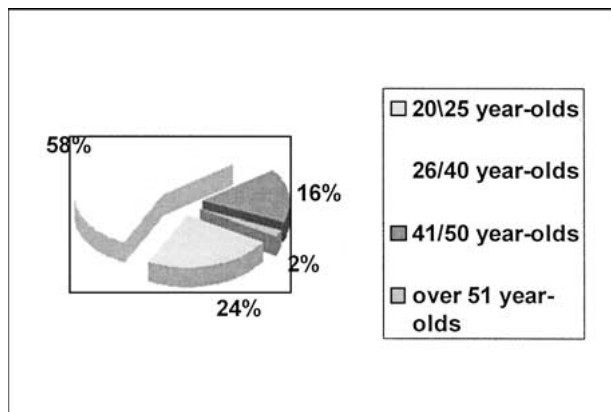


Fig. 1. Clinical caustriy.

Type of bodily hair




Fig. 2. Phototype of hair.

Materials and Methods

In our study, we considered the results achieved using one of the most modern machines for laser hair removal through a long-term follow-up period, which is something new in today's medical literature [Fig. 4]. A large and heterogeneous group of patients was taken into consideration (480 patients, 44% of the male gender) [Fig. 1]. These patients were covered with a normal amount of body hair or had parapsychologic conditions (hypertrichosis, hirsutism, transsexuality), with red, brown, black, or blond hair [Fig. 2] (72% dark-haired, 8% red, 20% blond) ($\sigma = 10,54$) in various body regions [Fig. 3]. They were exposed to a treatment for laser hair removal using a Nd:YAG laser source for long impulses that had a wave length of 1,064 nm (Q-switched laser), a variable fluency of 40 to 70 J/cm², an impulse length of 4 ms, and variable spot of 4 to 6 mm. This treatment operated by inducing selective photothermosis into radiated hair. We chose this particular equipment because it is extremely maneuverable, reliable and versatile (its software is easily capable of commuting "depilatory" mode to "vasculary" mode,

Area of treatment

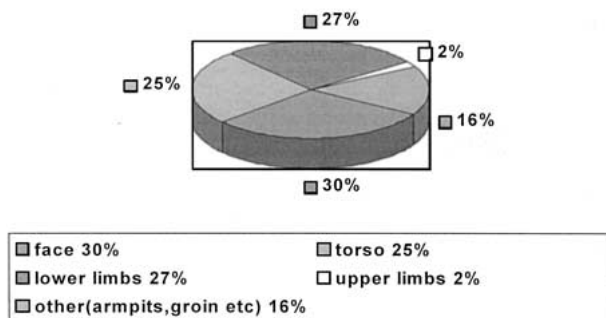


Fig. 3. Treated body area.

Average regrowth in one year

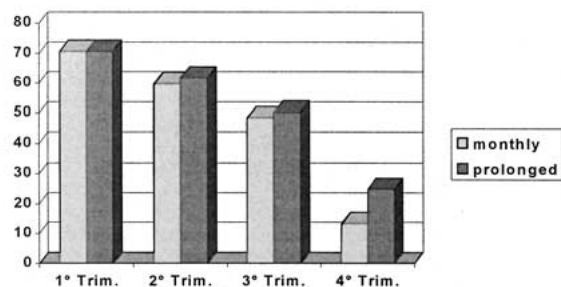


Fig. 4. Average regrowth in 1 year from the beginning of the treatment.

which enables the user to treat small angiomas, capillary telangecestasy, and the like with the same machine).

The laser source we used can penetrate the cutis up to a depth of 5 to 7 mm, so the risk of producing permanent damage to the radiated cutis is indeed minimal. The ratio for the dispersion of such rays on human tissue is low also because the ratio for absorption of the melanin is less than 1,064 nm [5,7].

All of the patients were subjected to a preliminary clinical examination that evaluated eventual endocrine disorders as well as pharmacologic therapies and others. They also underwent a scrupulous visual and photographic examination of the zone to be treated for calculation the hair concentration. Finally, a personal information file was compiled that contained various information such as type of bodily hair (color, density type and distribution of hair), area of treatment, date and length of treatment, laser setting, opinions of the patient and the operators about the results obtained on each occasion (integrated with digital photographs of high definition), and the eventual collateral effects [Fig. 8]. Collection of the

Average regrowth in two years

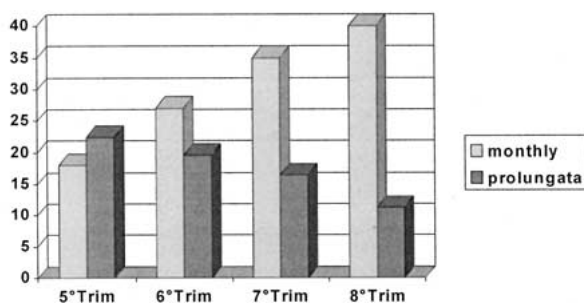


Fig. 5. Average regrowth in 2 years from the beginning of the treatment.

Area of treatment

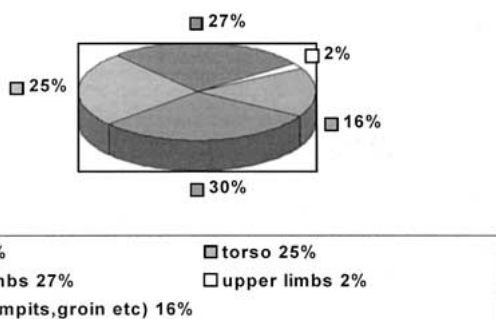


Fig. 6. Average regrowth in 3 years from the beginning of the treatment.

clinical results involved an evident difficulty connected with the impossibility of quantifying the regrowth of hair. To obviate this problem, we used criteria of objective examinations (a count of the impulses needed to complete the treatment, measurement of the required time, photographic comparisons) and subjective criteria (observations of the patient and various operators of the apparatus), opportunely integrated. The protocol of the treatment implemented was according to the following schema.

Pretreatment

The patient was shaved with razor blade, and local anesthetic (eutectic mixture of local anesthetics) was applied. Gel was chilled for ecography.

Posttreatment

Ice was applied for a couple of seconds, and a local decongestant in gel (e.g., Resurgil) was applied. Total solar protection cream was used.

Regrowth in the follow-up

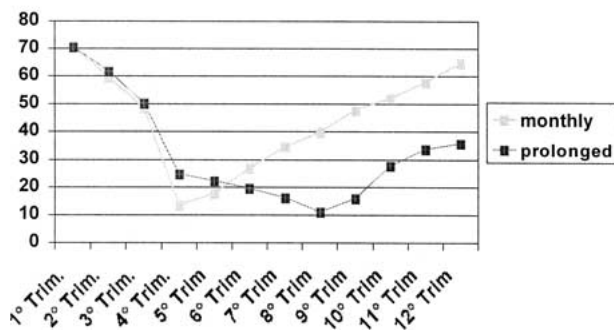


Fig. 7. Comparison of the repopulation curve for two protocols.

Discussion

The long-impulse Nd:YAG laser is efficient for hair of all colors except white, but it is particularly valid for dark hair. It therefore obtains results that are to a certain extent homogenous, unlike other laser sources that have almost zero collateral effects [2,5,7]. Our experience, shows that even if hair is not completely and permanently deactivated after the first sessions of follicle, photodermolysis its vital cycle certainly is reduced, provoking progressive synchronization of the biologic cycles, with telogenic phases becoming briefer and closer, although slight individual variations have been observed. If the hair removal efficiency of the laser source is at its highest, with the hair in an analgenic phase rather than a briefer telegenic phase, despite different lengths in the different bodily regions, reduction of the hair's vital cycle through the induction of a briefer telegenic phase enables prolonging the interval between one session and the next. This enhances the long-term results, producing stability and improving the cost-benefit rate for the treatment [1,3].

For patients followed with 10 to 12 monthly checkup sessions, we observed (during a follow-up period of 36 months) an average regrowth of 65%, as compared with the initial conditions. For the patients exposed to a "prolonged" treatment (the first four monthly checkup sessions and the following session over longer intervals, defined according to individual regrowth, on the average, about 40–90 days), we observed that the hair became progressively infrequent, sparse, and weak, with slow growth and with even longer periods of complete lack of hair. For these patients, the distinct improvement obtained permitted us to obtain an average regrowth of less than 40% during the same follow-up period. This growth was sometimes reached with a minor number of sessions (8 to 10 sessions [95. Figs. 5–7]).

Discovered collateral effects

Erythema
 Small blisters and transitory scabs (11%)
 Cutaneous hypopigmentation (4%)
 Hyperpigmentation (2%)

Fig. 8. Discovered collateral effects.

Conclusions

In our experience, the average regrowth has been 40% to 65%. We can therefore affirm that laser depilation by means of Nd:YAG at long impulses is decisively efficient in obtaining long-lasting, although not definitive, results [1,3,7]. The use of a protocol (denominated "prolonged checkup" with laser sessions at successively longer intervals allows, among other things, more outstanding and advantageous results for the patient:

- The number of sessions is reduced by 20% to 35%.
- The number of laser impulses used is minor, with a minor use of the apparatus.
- The number of collateral effects is minor.
- The total cost of the treatment is reduced by approximately 25%, all to the advantage of the patient.
- The length of the treatment is altogether less, to the advantage of the machine operators and to the satisfaction of the patients.

The comparison between the two regrowth curves is evidence that in the first group of patients, after the suspension of treatments, the regrowth of hair is highly decelerated but constant, progressively allowing repopulation. The second regrowth curve shows results that are decisively more stable with time. With suspension of the treatments, it is shown to have a plateau after an initial light regrowth.

These findings enable us, after the initial period of monthly laser sessions, to prolong the time successively between one session and the next, personalizing the treatment until a depilation is obtained. This depilation is not definitive, but progressively becomes permanent. That is, it is characterized by periods of lack of hair, which become longer and longer, and it is sustained by sporadic laser retention sessions according to the necessity of the individuals.

References

1. Bencini PL, Luci A, Galimberti M, Ferranti G: Long-term epilation with long-pulsed Neodimium:YAG laser. *Dermatol Surg* **25**:175-178, 1999
2. Kilmer SL, Anderson RR: Clinical use of the Q-switched ruby and Q-switched Nd:YAG (1,064 nm and 532 nm) lasers for treatment of tattoos. *J Dermatol Surg Oncol* **19**:330, 1993
3. Lin TD, Manuskiatti W, Dierickx CC, Farinelli W, Fischer ME, Flotte T, Baden HP, Anderson RR: Hair growth cycle affects hair follicle destruction by ruby laser pulses. *J Invest Dermatol* **111**:107-113, 1998
4. Olsen EA: Methods of hair removal. *J Am Acad Dermatol* **40**:143-155, 1999
5. Sliney DH: Laser-tissue interactions. *Clin Chest Med* **6**:203, 1985
6. Wheeland RG: Clinical uses of lasers in dermatology. *Lasers Surg Med* **16**:2, 1995
7. Wimmershoff MB, Scherer K, Lorenz S, Landthaler M, Hohenleutner U: Hair removal using a 5-msec long-pulsed ruby laser. *Dermatol Surg* **26**:205-209, 2000