

Correction of Prominent Ears with a New Splinting Technique

Giuseppe A. Ferraro, M.D., Fernando Rossano, M.D., and Francesco D'Andrea, M.D.

Department of Plastic and Reconstructive Surgery, Second University of Naples, Naples, Italy

Abstract. Correction of prominent ears represents one of the main applications in plastic surgery. Apart from its cosmetic nature, this operation is important because of the psychological distress that the deformity causes patients. In this study, 40 patients who underwent treatment for prominent ears in our department were evaluated. The classical surgical technique described by Chongchet followed by a new splinting procedure was performed. The advantages of this technique are described in comparison with traditional methods.

Key words: Elastic splint—Otoplasty—Plastic surgery—Polyvinylsiloxane—Prominent ears

The normal external ear makes a 23° angle with the temporal surface of the head. If the angle is more obtuse, ears can appear excessively prominent when viewed from the front. Such a large angle is attributable to two main factors, either isolated or associated: (a) excessive growth of the concha and an absent or insufficient curve of the antihelix [8].

Table 1. Patient data

No. of patients	40
Male: n (%)	26 (65)
Female: n (%)	14 (35)
Minimum age (years)	8
Maximum age (years)	30
Average age (years)	17
No. of surgically treated ears	80
Prominent ear (%)	75
Isolated concha hypertrophy (%)	25

Surgical correction aims to reestablish the normal antihelix fold and to reduce excessive development of the concha, thus bringing the auricle closer to the mastoid. Numerous procedures and techniques are used for this purpose [1–5,7,9]. The most common procedures are based on the concept demonstrated by Gibson and Davis in 1958 [6], whereby the lamina is partially cut on one side so that it folds

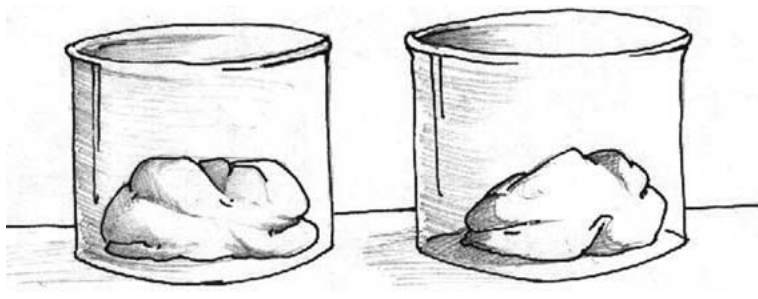


Fig. 1. Base paste and catalyst in appropriate containers.

Correspondence to Giuseppe A. Ferraro M.D., Centro Direzionale di Napoli, Isola B/8, 80143 Napoli, Italy; *email:* gaferraro@libero.it

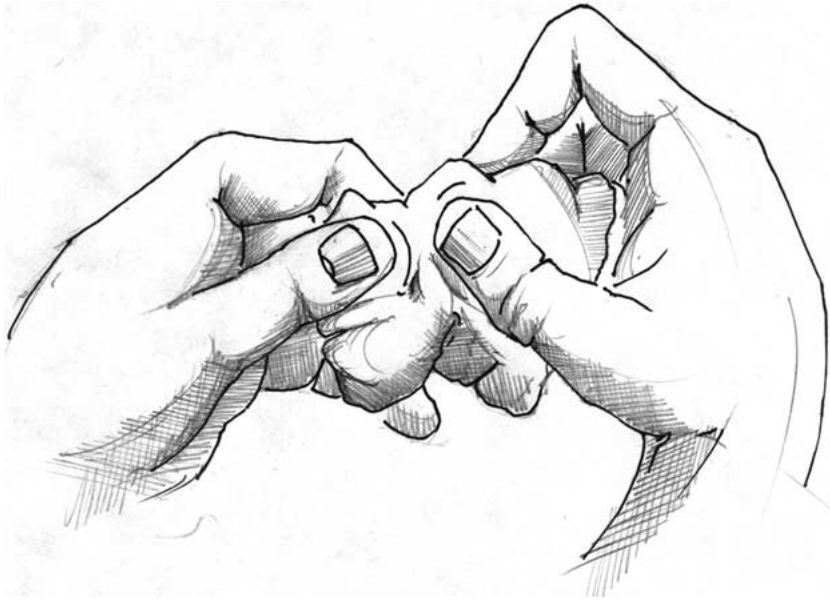


Fig. 2. Mixing phase.

Table 2. Characteristics of the product

Composition	Polyvinylsiloxane
Recovery for deformation	> 99%
Linear dimensional change (shrinkage)	24 h < 0.2%; 336 h (2 weeks) < 0.3%
Maximum strain in compression	1.0– 3.0%

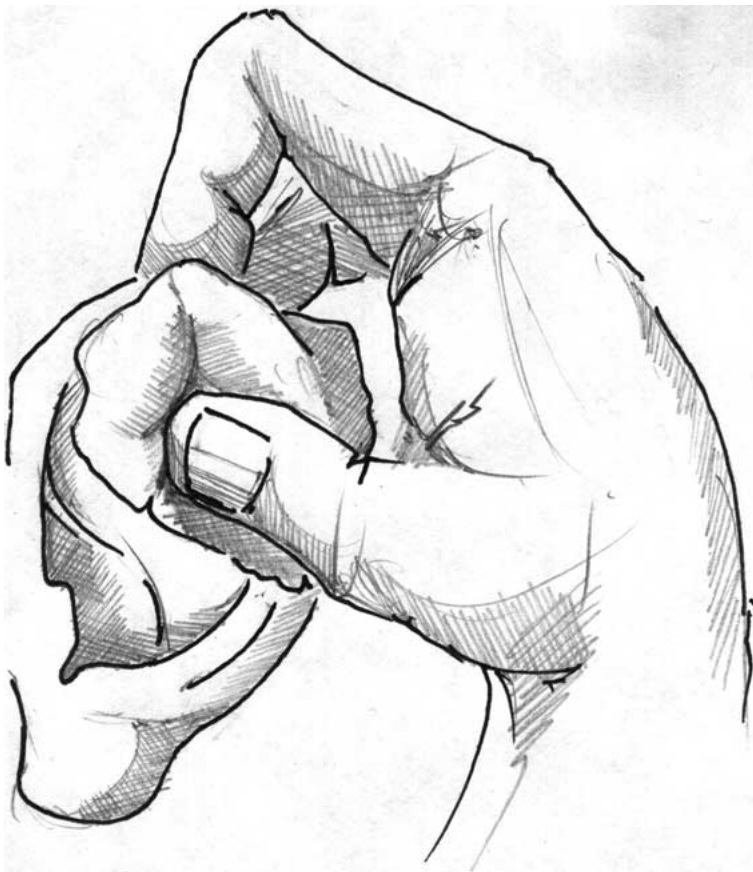

Fig. 3. Application and modeling phases of the splint on the ear.



Fig. 4. Complete splinting apparatus: splints *in situ* and elastic bandage for covering.

spontaneously to the other side as the elastic fibers running parallel to the remaining intact surface retract. It is a very simple and widely consolidated technique. The technique involves a retroauricular incision and exposure of cartilage, which then is stripped cutaneously through parallel partial-thickness incisions of the anterior face. This allows for shaping of the newly desired form.

Traditionally, to avoid hematomas and maintain the new position, dressings start with fluffy cotton padding covered by a bulky turban-like bandage, which is held *in situ* for at least 7 to 10 days.

This containment procedure presents various drawbacks resulting from both postoperative recovery and patient compliance. The fluffy gauze is not very effective in maintaining the new auricular shape. In fact, it easily absorbs blood and other biologic liquids, becomes rigid, and adheres to the wounds. Because this dressing is not easily removed, and because the turban bandage must be maintained for 7 to 10 days, the postoperative recovery is not easily controlled during this period.

A new approach for postoperative dressings was studied. This new approach consists of a splint made of a new plastic material modeled directly on the patient's ear. A simple elastic bandage is used for a period of only 3 days.

Materials and Methods

The study investigated 40 patients of both sexes with prominent ear deformities treated consecutively. The patients ranged in age from 8 to 30 years. The patient data are shown in Table 1.

All the patients were treated with traditional Chongchet otoplasty followed by application of the splint. The splint used in this study is made of a paste-paste system in polyvinylsiloxane, with the one paste acting as the base and the other as a catalyst (Fig. 1). When the two pastes are mixed in the appropriate proportion (1:1) (Fig. 2), they form a final product that remains malleable for about 4 to 5 min. After this, it becomes a solid with optimum cast properties, but with sufficient elasticity. The characteristics of the product are specified in Table 2.

During the plastic phase, the mixture was applied to the ears and modeled by hand according to the form and specific requirements of each patient (Fig. 3). Once modeled, the splint was left *in situ*, and the ears were covered with an elastic bandage for 3 days (Fig. 4). Behind the auricle, a fluffy gauze dressing was applied for two reasons: to keep the ear away from the mastoid so that the concha would maintain its new shape and to avoid adherences to the wound.

The first clinical follow-up visit took place on the fourth day, at which time the bandages and splints were removed. The patients were given the splints and bandages and instructed to wear them during sleep periods only for 7 more days.

Results

At the first follow-up visit 4 days after the operation, the splints were easily removed. Not having absorbed blood or other biologic liquids, they did not adhere to the tissues, so a correct, total, and painless removal was performed.

Despite the complete detachability of the splint, regular postoperative follow-up evaluation during the recovery period was possible without trauma to the patient. Consequently, the possible formation of hematomas was easily monitored and controlled.

Because of the splints' long-term compliancy and elasticity, no cases or signs of decubitus phenomena on the splinted structures were noted, and the splints kept the ears in the desired shapes. As a matter of fact, once removed from the ears, the

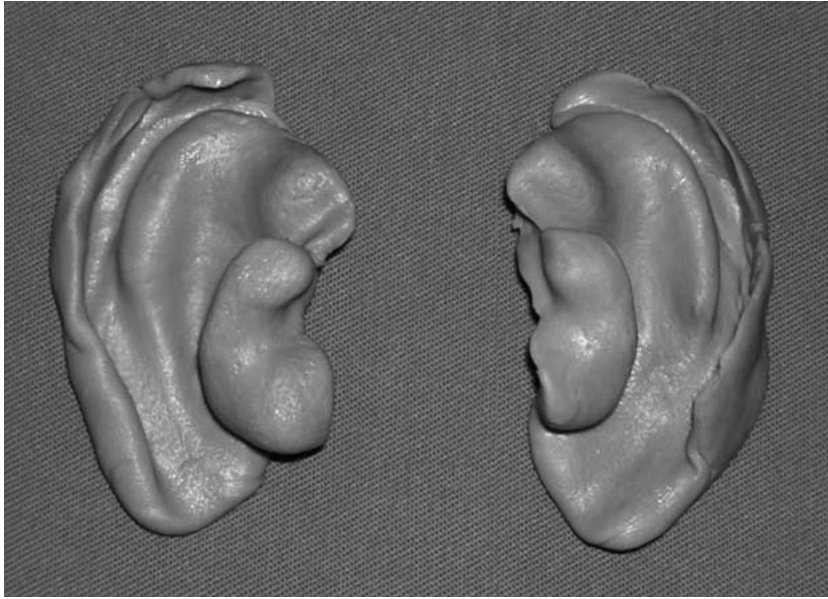


Fig. 5. Splints after removal.

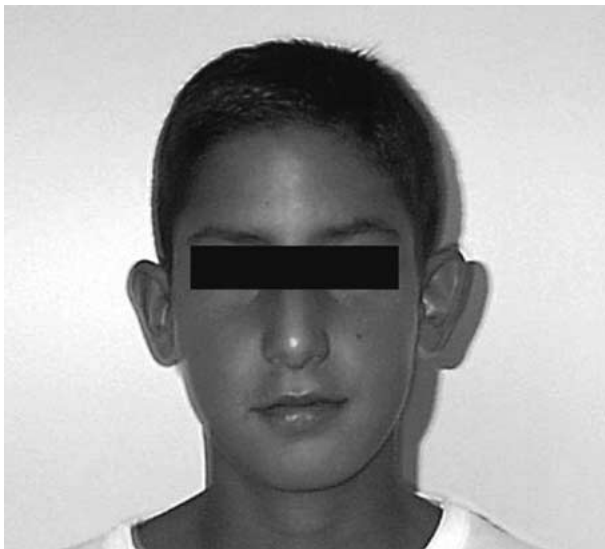

Fig. 6. Preoperative front view.

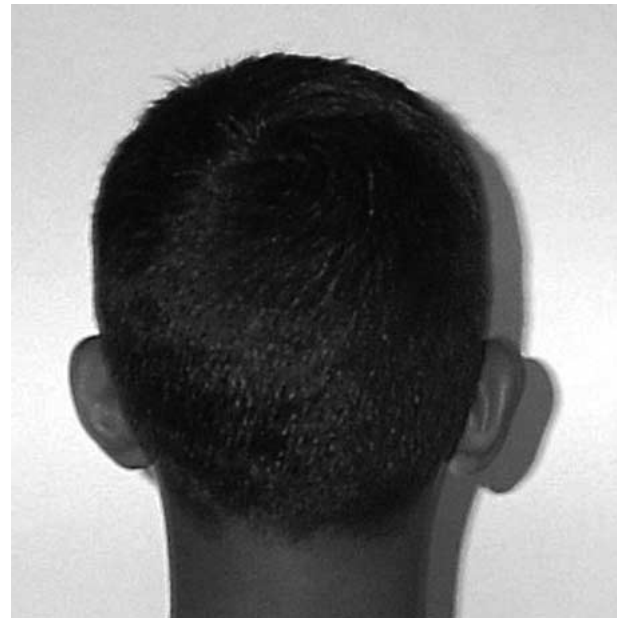

Fig. 7. Preoperative back view.

splints perfectly retained their original form (Fig. 5). Thus patients were easily trained on how to reposition the splint at home. When interviewed about any difficulties or discomfort encountered with nighttime use of the splints, the patients responded negatively.

In comparison with the classical method, there was much less reluctance among patients in resuming their daily outdoor activities while wearing the apparatus, even within the first 3 days. Finally, the result can be considered successful, with an absence of complications (hematomas or adhesions to the splint structures) and better patient compliance in the postoperative period (Figs. 6–11).

Advantages

The study results confirm the validity of the experimental method, as compared with the classical technique. The advantages of this procedure can be easily summarized as offering

- Simple and traditional surgical technique that can be personalized
- Prompt availability of highly malleable plastic material according to individual requirements
- Well-tolerated material that it does not adhere to the skin or absorb blood or other biologic liquids

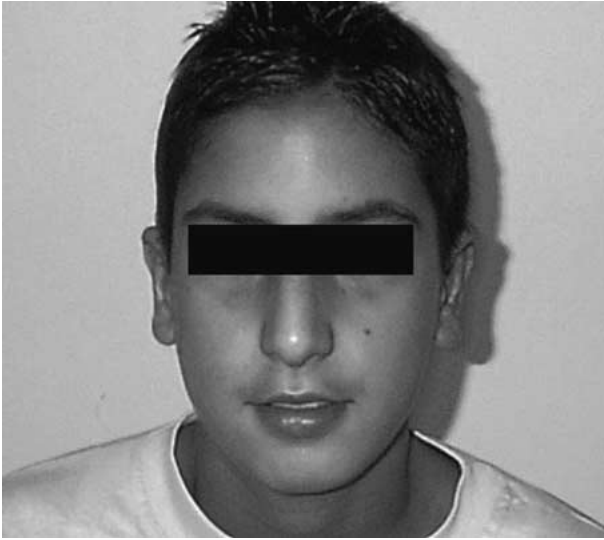

Fig. 8. Front view 1 month after surgery.

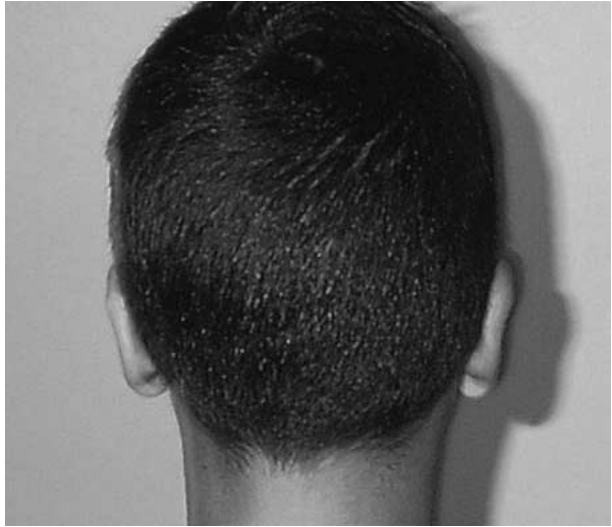

Fig. 9. Back view 1 month after surgery.

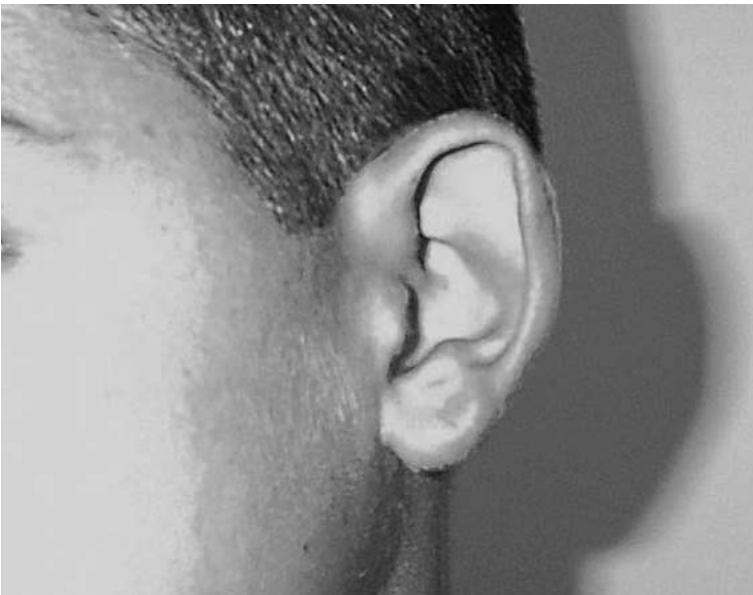

Fig.10. Preoperative lateral view.

- Absence of decubitus phenomena
- Personalized splinting apparatus with cast properties
- Easier postoperative follow-up evaluation of eventual hematomas
- Quicker and better-tolerated postoperative period
- More brilliant results.

References

1. Chongchet V: A method of antihelix reconstruction. *Br J Plast Surg* **16**:268, 1963
2. Converse JM, Nigro A, Wilson FA, Johnson N: A technique for surgical correction of loop ears. *Plast Reconstr Surg* **15**:411, 1955
3. Corchado C: A surgical technique for the correction of all types of prominent ears? *Plast Reconstr Surg* **106**:948, 2000
4. Erol OO: New modification in otoplasty: Anterior approach. *Plast Reconstr Surg* **107**:193, 2001
5. Furnas DW: Correction of prominent ears by chonchamastoid sutures. *Plast Reconstr Surg* **42**:189, 1968
6. Gibson T, Davis WB: The distortion of autogenous cartilage grafts: Its cause and prevention. *Br J Plast Surg* **10**:257, 1958
7. Mustarde JC: The correction of prominent ears by buried mattress sutures: A ten-year survey. *Plast Reconstr Surg* **39**:382, 1967
8. Paletto EA: *Trattato di Tecnica Chirurgica*. Vol. 9 Chirurgia Plastica, Torino, Utet, pp 241–242, 1986
9. Stenstrom SJ: A natural technique for correction of congenitally prominent ears. *Plast Reconstr Surg* **32**:509, 1963

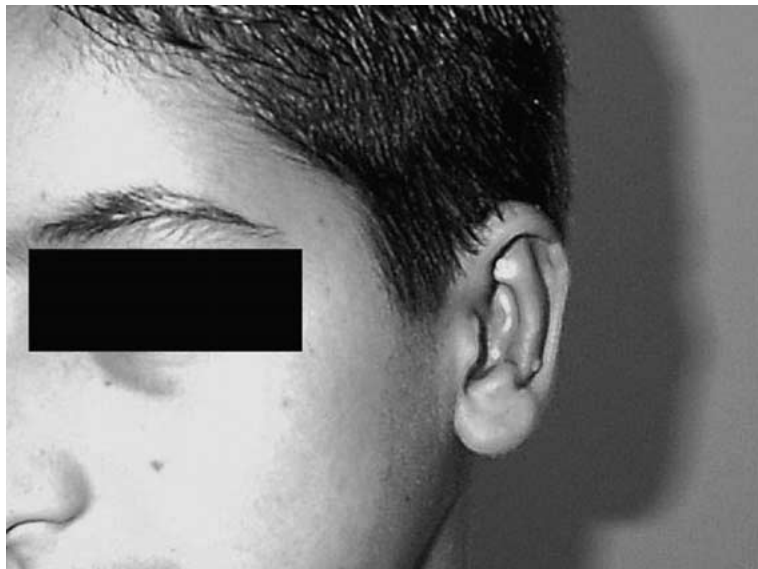

Fig.11. Lateral view after removal of splints 7 days after surgery.