
Odontogenic keratocyst and uterus bicornis in nevoid basal cell carcinoma syndrome: case report and literature review

Luca Ramaglia, MD, DDS,^a Fabio Morgese, DDS,^b Marcella Pighetti, MD, PhD,^c
and Raffaele Saviano, DDS,^d Napoli, Italy
UNIVERSITÀ DI NAPOLI "FEDERICO II"

Nevoid basal cell carcinoma syndrome (NBCCS), an autosomal dominant disorder with a high degree of penetrance and variable expressivity, is characterized by basal cell carcinomas, odontogenic keratocysts, palmar and/or plantar pits, and ectopic calcifications of the falx cerebri. More than 100 minor criteria have been described, but 2 major and 1 minor criteria or 1 major and 3 minor criteria are necessary for the diagnosis. In this report we present an 8-year-old girl affected by NBCCS showing a uterus bicornis, a hitherto unreported association. However, further research is needed to confirm the association between NBCCS and mullerian fusion defects and to assess the hypothesis that focuses on chromosome 9 the mutant gene for NBCCS and fusion defects of female genital tract. (*Oral Surg Oral Med Oral Pathol Oral Radiol Endod* 2006;102:217-9)

Nevoid basal cell carcinoma syndrome (NBCCS) is an autosomal dominant disorder with a high degree of penetrance and a variable expressivity characterized by several development defects and a predisposition to cancer.¹⁻⁵ Prevalence of NBCCS ranges from 1 in 56,000 subjects in England to 1 in 164,000 in Australia with males and females equally affected.³

The syndrome, first delineated by Gorlin and Goltz,¹ is characterized by basal cell carcinomas, odontogenic keratocysts, palmar and/or plantar pits, and ectopic calcifications of the falx cerebri.⁶ These traits are considered major clinical diagnostic criteria.⁷ Basal cell carcinomas, reported in approximately 76% of NBCCS cases, affect primarily the face and back, followed by the chest.⁸ Although detected in very young patients, basal cell carcinomas usually appear between the ages of 17 and 35 years and their number can range from few to more than a thousand. About 0.5% of all basal cell carcinomas may be attributed to this syndrome. Seventy-five percent of patients affected by NBCCS show odontogenic keratocysts, often multiple and bilateral. They are mainly located in the premolar area, may displace teeth with consequent malocclusion, and can be unilocular or multilocular with a preference for

the mandible. Jaw cysts are often asymptomatic but occasionally they may present pain, swelling, intraoral drainage, visual disturbance, or paresthesiae. Furthermore, they may cause pathologic fractures of the mandible or facial distortion. Pitting of the palms and soles is very specific for NBCCS, and is caused by a partial or complete absence of stratum corneum; therefore they are permanent, not palpable, asymptomatic, and appear as shallow depressions measuring 1 to 3 mm in depth and 2 to 3 mm in diameter.⁹

More than 100 minor criteria have been described for NBCCS but cardiac or ovarian fibroma, macrocephaly, bifid ribs, kyphoscoliosis, cleft palate, and medulloblastoma are the most frequent. In particular, about 1% to 2% of all medulloblastomas may be attributed to this syndrome. Incidence of medulloblastoma in NBCCS is 3% to 5% with a male-to-female ratio of 3:1. Other features of the syndrome may include bridging of the sella turcica, mild mandibular prognathism, lateral displacement of the inner canthi, frontal and biparietal bossing, imperfect segmentation of cervical vertebrae, lymphomesenteric cysts that tend to calcify, short fourth metacarpal, fibrosarcoma, meningiomas, rhabdomyosarcomas, strabismus, dystrophic canthorum, ocular hypertelorism, congenital blindness, spina bifida occulta, pectus deformity, high arched eyebrows and palates, narrow sloping shoulders, immobile thumbs, low-pitched voice in females, kidney anomalies, and hypogonadism in males. In addition, patients with NBCCS are often taller and occasionally exhibit features similar to acromegaly.⁹

Diagnosis of NBCCS may be difficult because of the variability of expressivity and because of different ages of onset for the different traits of this disorder. However, 2 major and 1 minor criteria or 1 major and 3 minor criteria are necessary for the diagnosis.⁷ Average age for

^aAssociate Professor, Dipartimento di Scienze Odontostomatologiche e Maxillo-Facciali, Università di Napoli "Federico II."

^bResident Student, Dipartimento di Scienze Ostetriche e Ginecologiche, Università degli Studi di Napoli "Federico II."

^cAssistant Professor, Dipartimento di Scienze Ostetriche e Ginecologiche, Università di Napoli "Federico II."

^dPhD Student, Dipartimento di Scienze Ostetriche e Ginecologiche, Università di Napoli "Federico II."

Received for publication May 10, 2005; returned for revision May 10, 2005; accepted for publication Aug 12, 2005.

1079-2104/\$ - see front matter

© 2006 Mosby, Inc. All rights reserved.

doi:10.1016/j.tripleo.2005.08.009

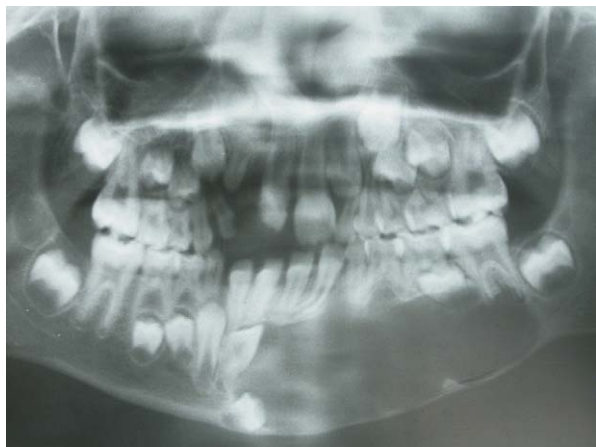

Fig. 1. Dental panoramic radiography.

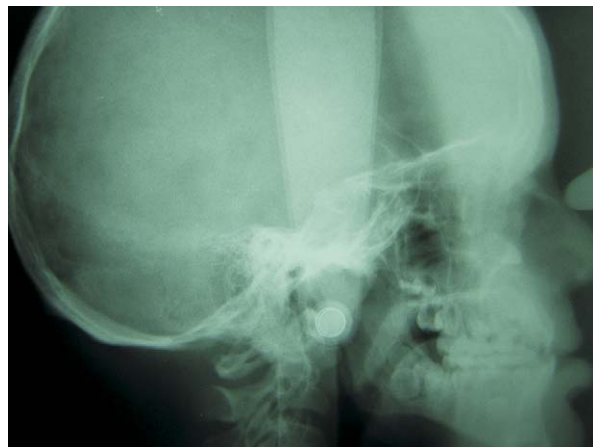

Fig. 3. Lateral cephalogram.

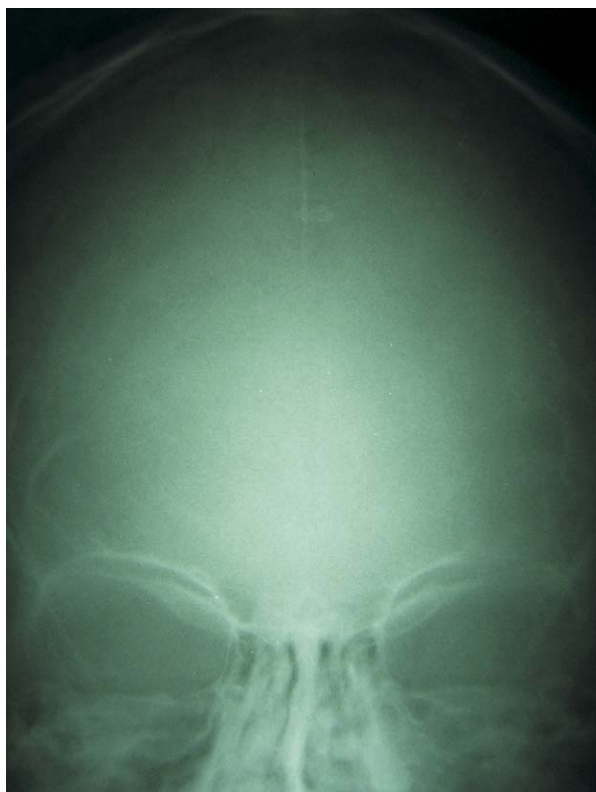

Fig. 2. Frontal cephalogram.

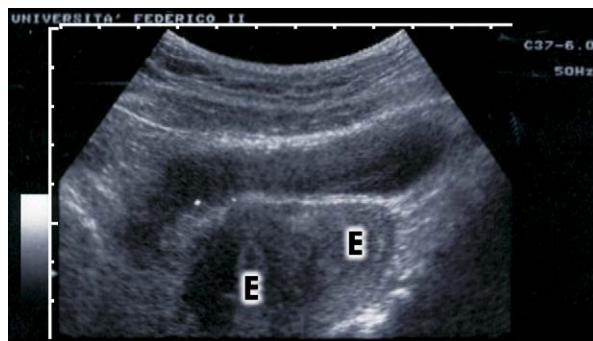


Fig. 4. Transabdominal ultrasonography (E = endometrium).

diagnosis of NBCCS is 13 years while average age for detection of basal cell carcinoma is 20 years. The clinical expression of the syndrome varies among individuals within the same family and even more among families.⁹

NBCCS seems to be caused by constitutional aberrations of gene *PTCH* mapped to the long arm of chromosome 9 locus 9q22.3-q31 with no apparent heterogeneity.^{10,11} In fact, about 60% to 85% of subjects

fulfilling diagnostic criteria show the gene defect.¹¹ Chenevix-Trench et al.² reported that about 70% to 80% of probands have inherited the condition from a parent and about 20% to 30% of probands have a de novo mutation. Since a reduction in expression of the *PTCH* gene can produce development abnormalities and its complete loss contributes to a neoplastic transformation of some cells, the end product of this gene is supposed to play a role as tumor suppressor.¹²

In this report we present a young subject affected by NBCCS showing a large odontogenic keratocyst, craniofacial and dental anomalies, and a uterus bicornis, a hitherto unreported association.

CASE REPORT

An 8-year-old girl was referred to the Department of Oral Surgery at University of Napoli "Federico II," Italy, requiring treatment for a large mandibular osteolytic lesion (Fig. 1). At the clinical examination she showed frontal bossing, macrocephaly and hypertelorism, signs of corrective surgery for cleft lip and palate, dentoskeletal class III malocclusion with molar crossbite due to an underdeveloped maxilla, palmar and plantar pits, and brown basal cell nevi with variable diameter (2 to 4 mm) at the dorsal region of the body. The mandibular

neof ormation was surgically removed and the histological analysis confirmed the diagnosis: odontogenic keratocyst. The presence of minor and major criteria allowed the diagnosis of NBCCS. The observation of abnormal phenotypes in previous generations within the same family confirmed the diagnosis. The patient underwent further radiological examinations. Calcification of the falx cerebri (Fig. 2), bridging of sella turcica (Fig. 3), and scoliosis were observed. The neurological examination showed a clear neurological defect.

Since in the literature an ovarian fibroma, often bilateral, is reported in association with NBCCS, an ultrasound pelvic examination was also performed. This examination showed a normal ovarian apparatus but a bicornis uterus with 2 separate uterine cavities (Fig. 4). Urinary tract anomalies were not detected.

DISCUSSION

Recently, Kimonis et al.¹³ have described a septate uterus in a woman with NBCCS but the association of the syndrome with a bicornis uterus has never been reported.

Congenital anomalies of the mullerian system are common but the prevalence of fusion defects of the mullerian ducts is only 0.1%.¹⁴⁻¹⁷ In this regard, Verp et al.¹⁸ have reported a familial aggregate but no formal genetic investigations have been performed. Furthermore, clinical studies have shown that fusion defects of the mullerian system may be associated with pelvic pain and reproductive failure.

The cause of congenital uterine anomalies is actually unknown. The female genital tract develops from the pair of mullerian ducts that subsequently fuse, starting from the 10th to the 17th week of pregnancy. This process is completed just prior to term.¹⁹

In the present clinical case many criteria allowed a diagnosis of NBCCS, but for the first time an incomplete mullerian fusion with an uterus bicornis was associated with this genetic disease. Moreover, it is interesting to speculate on the association of NBCCS and defects of the female genital tract to locate chromosome 9 the mutant gene for incomplete mullerian fusion and NBCCS. However further research is needed to confirm this hypothesis and the association between NBCCS and mullerian fusion defects.

REFERENCES

- Gorlin RJ, Goltz RW. Multiple nevoid basal-cell epithelioma, jaw cysts and bifid rib: a syndrome. *N Engl J Med* 1960;262:908-12.
- Chenevix-Trench G, Wicking C, Berkman J, Sharpe H, Hockey A, Haan E, et al. Further localisation of the gene for nevoid basal

cell carcinoma syndrome (NBCCS) in 15 Australasian families: linkage and loss heterozygosity. *Am J Hum Genet* 1993;53:760-7.

- Gorlin RJ. Nevoid basal cell carcinoma (Gorlin) syndrome. *Genet Med* 2004;6:530-9.
- Bonifas JM, Bare JW, Kerschmann RL, Master SP, Epstein EH Jr. Parental origin of chromosome 9q22.3-q31 lost in basal cell carcinomas from basal cell nevus syndrome patients. *Hum Mol Genet* 1994;3:447-8.
- Bale AE. Variable expressivity of patched mutations in flies and humans [editorial]. *Am J Hum Genet* 1997;60:10-2.
- Gorlin RJ, Pindborg JJ, Cohen MM Jr. Syndromes of the head and neck. New York: Blakiston Division, McGraw-Hill; 1976.
- Gorlin RJ, Cohen MM Jr, Levin LS. Gorlin syndrome (nevoid basal cell carcinoma syndrome). In: Gorlin RJ, Cohen MM, Hennekam RCM, editors. *Syndromes of the head and neck*. 3rd ed. New York: Oxford University Press; 1990.
- Shanley S, Ratcliffe J, Hockey A, Haan E, Oley C, Ravine D, et al. Nevoid basal cell carcinoma syndrome: a review of 118 affected individuals. *Am J Med Genet* 1994;50:282-90.
- Evans DG, Ladusans EJ, Rimmer S, Burnell LD, Thakker N, Fardon PA. Complications of naevoid basal cell carcinoma syndrome: results of a population based study. *J Med Genet* 1993;30(6):460-4.
- Fardon PA, Del Mastro RG, Evans DGR, Kilpatrick MW. Location of gene for Gorlin syndrome. *Lancet* 1992;339:581-2.
- Hahn H, Wicking C, Zaphiropoulos PG, Gailani MR, Shanley S, Chidambaram A, et al. Mutations of the human homolog of *Drosophila* patched in the nevoid basal cell carcinoma syndrome. *Cell* 1996;85:841-51.
- Gailani MR, Bale SJ, Leffell DJ, Di Giovanna JJ, Peck GL, Poliak S, et al. Developmental defects in Gorlin syndrome related to a putative tumor suppressor gene on chromosome 9. *Cell* 1992;69:111-7.
- Kimonis VE, Goldestein AM, Pastakia B, Yang ML, Kase R, DiGiovanna JJ, et al. Clinical manifestations in 105 persons with nevoid basal cell carcinoma syndrome. *Am J Med Genet* 1997;69:299-308.
- Golan A, Langer R, Bukovsky I, Caspi E. Congenital anomalies of the mullerian system. *Fertil Steril* 1989;51:747-55.
- Rock JA, Schlaff WD. The obstetric consequences of uterovaginal anomalies. *Fertil Steril* 1985;43:681-92.
- Pinsonneault O, Goldestein DP. Obstructing malformations of the uterus and vagina. *Fertil Steril* 1985;44:241-7.
- Heinonen PK, Saarikoski S, Pystynen P. Reproductive performance with uterine anomalies. An evaluation of 182 cases. *Acta Obstet Gynecol Scand* 1982;61:157-62.
- Verp MS, Simpson JL, Elias S, Carson SA, Sarto GE, Feingold M. Heritable aspects of uterine anomalies. I. Three familial aggregates with Mullerian fusion anomalies. *Fertil Steril* 1983;40:80-5.
- Jones TB, Fleisher AC, Daniell JF, Lindsey AM, James AE Jr. Sonographic characteristics of congenital uterine abnormalities and associated pregnancy. *J Clin Ultrasound* 1980;8:435-7.

Reprint requests:

Luca Ramaglia, MD, DDS
 Dipartimento di Scienze Odontostomatologiche e Maxillo-Facciali
 Facoltà di Medicina e Chirurgia
 Università di Napoli "Federico II"
 Via Sergio Pansini, 5
 80131 Napoli
 Italy
luca.ramaglia@unina.it