

# Manage joint issues with an injectable device *solution.*

With a single injection of **Spryng™ with OsteoCushion™ Technology**, you have the power to simply, effectively and economically manage lameness and joint issues.

Spryng™ with OsteoCushion™ Technology is an innovative veterinary medical device that takes the treatment of lameness issues into a new arena by addressing the root cause of the conditions – missing and damaged cartilage. Spryng™ aids in the management of joint pain from the loss of cartilage or tissue-bone mechanical malfunction caused by joint disfunction.

When injected into the joint, Spryng™ creates a sponge-like, shock-absorbing matrix – that works with synovial fluid to mimic the protective form and function of natural, healthy joint cartilage. When a horse jumps, runs or performs any movement with joint impact, Spryng™ absorbs and releases synovial fluid in response, with elastic stiffness that complements natural synovial fluid and cartilage dynamics.

Spryng™ also provides a natural scaffold, potentially protecting the joint from further injury, unlike other lameness management options that may only mask symptoms.




[Learn more and order](#)

Also available at

**AmerisourceBergen**  
MWI Animal Health®



Spryng™ is only available for use by or on the order of a licensed veterinarian.  
Spryng™ with OsteoCushion™ Technology is a veterinary medical device by **PetVivo, Inc.**  
© PetVivo, Inc. 2022 | SDPA-1-0523



**SIMPLE**  
Single injection with rapid results



**LONG LASTING**  
Long duration of joint protection

**INNOVATIVE**  
Address the affliction – helps to restore proper joint mechanics

**A VETERINARY MEDICAL DEVICE**

 **spryng™**  
with OsteoCushion™ Technology

# Influence of oblique proximal ulnar osteotomy on humeral intracondylar fissures in 35 spaniel breed dogs

Alan Danielski DVM, DipECVS<sup>1,2</sup>  | Ignacio Quinonero Reinaldos DVM<sup>3</sup>  |  
Miguel Angel Solano DVM, DipECVS<sup>1</sup> | Gerardo Fatone DVM<sup>2</sup>

<sup>1</sup>The Ralph Veterinary Referral Center, Marlow, UK

<sup>2</sup>Department of Veterinary Medicine and Animal Production, University of Naples "Federico II", Naples, Italy

<sup>3</sup>Small Animal Hospital, Faculty of Veterinary Medicine, University of Glasgow, Glasgow, UK

## Correspondence

Alan Danielski, The Ralph Veterinary Referral Center, Fourth Avenue Globe Business Park, Marlow SL7 1YG, UK.  
Email: [alan.danielski@gmail.com](mailto:alan.danielski@gmail.com)

## Abstract

**Objective:** To investigate the effects of oblique proximal ulnar osteotomy (PUO) on the healing of humeral intracondylar fissure (HIF) in spaniel breed dogs.

**Study Design:** Clinical retrospective study.

**Sample Population:** A total of 51 elbows from 35 spaniel dogs.

**Methods:** An oblique PUO was performed in dogs diagnosed with HIF. The degree of healing of HIF was subjectively and objectively assessed on preoperative and long-term follow-up CT imaging. Objective assessment was performed by measuring the bone density in Hounsfield units (HU) of a rectangular region of interest (ROI) encompassing the entire hypoattenuated humeral fissure. Major and minor complications were recorded.

**Results:** A total of 24 partial and 27 complete HIFs were diagnosed. The follow-up CT scan was performed at a median 18.5 months (range 10–49 months). Subjective assessment confirmed partial or complete healing of the HIF in 41 elbows (80.3%). Objective assessment confirmed a difference in mean HU of the HIF's ROI between preoperative (HU 640) and last follow-up CT images (HU 835) ( $p = .001$ ). Young dogs (<14 months) had the highest increase in HU of the HIF's ROI. Major complications occurred in five dogs (6 limbs) of which four were related to the lack of healing of the fissure (7.8%).

**Conclusion:** Oblique PUO resulted in partial or complete healing of HIF and pain resolution in the majority of dogs.

**Clinical Significance:** This study introduces an innovative approach to achieve healing of the HIF in the dog, which may help reduce the high complication rate traditionally associated with the use of transcondylar screws.

## 1 | INTRODUCTION

Humeral intracondylar fissure (HIF) is a common cause of thoracic limb lameness in spaniel breed dogs in the UK, and it can predispose to condylar fractures with

The preliminary results of this study were presented at the ESVOT Congress (22–24th September 2022) in Nice (France).

This is an open access article under the terms of the [Creative Commons Attribution](https://creativecommons.org/licenses/by/4.0/) License, which permits use, distribution and reproduction in any medium, provided the original work is properly cited.

© 2023 The Authors. *Veterinary Surgery* published by Wiley Periodicals LLC on behalf of American College of Veterinary Surgeons.

minimal or no trauma.<sup>1–5</sup> HIF was initially hypothesized to be due to a failure of the two centers of ossification of the humeral condyle to unite.<sup>6</sup> However, over the past years, due to an increase in popularity of cross-sectional imaging as a diagnostic tool, the stress fracture theory has gained more consensus.<sup>4,7,8</sup> This is supported by the fact that many dogs diagnosed with HIF are adult dogs, that a few studies have reported propagation/development of fissures in previously normal elbows, and that HIFs can extend to the supratrochlear foramen while the cartilaginous plate of the centers of ossification does not extend that far proximal. However, based on the current scientific evidence, it cannot be excluded that both hypotheses are valid and that the incomplete ossification theory can be applied to skeletally immature dogs while the stress fracture hypothesis can be applied to older dogs.

A recent study described the presence of a cartilaginous lesion present on the caudal aspect of the humerus of spaniel breed dogs with HIF as a result of humero-anconeal incongruity.<sup>9</sup> The authors suggested that this kind of incongruity may be the cause of abnormal cyclical load applied to the humeral condyle and that the fissure is the result of a stress fracture. If this hypothesis is correct, healing of the HIF could theoretically be achieved by resolving, or at least ameliorating, humero-anconeal incongruity. This could be achieved by performing an oblique proximal ulnar osteotomy (PUO) that would allow proximal translation and tilting of the proximal ulnar segment as a result of the upward pull of the triceps muscle.<sup>10,11</sup>

Specifically, we hypothesize that the displacement of the proximal ulnar segment could cause the tip of the anconeal process to move in a cranio-proximal direction, towards the supracondylar foramen. This could disrupt the abnormal cyclical load that is applied to the humeral condyle by the tip of the anconeal process during weight-bearing stance. This theory has been successfully tested in a recent case report where complete healing of the HIF was achieved in a 7-month-old Shetland sheepdog treated with staged bilateral oblique PUO.<sup>12</sup>

Our hypothesis was that an oblique PUO would mitigate the abnormal cyclic load applied to the caudal aspect of the humeral condyle by the anconeal process, thereby allowing some healing of the HIF.

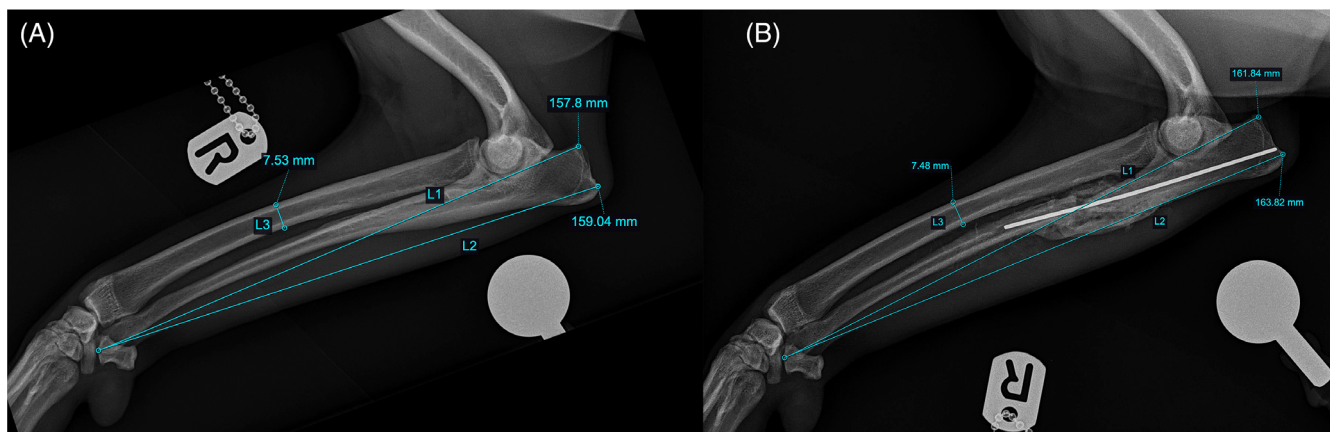
## 2 | MATERIALS AND METHODS

Dogs presenting to the authors' institution (2019–2022) for unilateral/bilateral thoracic limb lameness and had HIF diagnosed by computed tomography (CT) scan were included in the study. Dogs that did not undergo 6-week follow-up radiographs or later follow-up CT scans at a later stage were excluded from the study. Information

retrieved included age, sex, breed, uni-/bilateral lameness, subjective degree of discomfort on elbow extension (classified as mild, moderate and severe) preoperatively and at the 6-week follow-up appointment, partial/complete fissure, arthroscopic findings, postoperative complications, time between initial surgery and follow-up CT scan, and time between initial surgery and the last telephonic/written follow-up. Ethical approval to perform long-term follow-up CT imaging was obtained by the RCVS Ethics review panel (2021–2047).

### 2.1 | Preoperative imaging and surgical management

Computed tomography (GE Revolution, GE Healthcare, Chalfont St Giles, UK) of both thoracic limbs from the carpi to the shoulders was performed with the dog under deep sedation (3–8 mcg/kg dexmedetomidine and 0.2 mg/kg butorphanol, IV). Dogs were positioned in sternal recumbency, with the elbow joints parallel and extended cranially at approximately 130°–140° of extension. If CT revealed changes compatible with presence of HIF (as previously described by Carrera et al.),<sup>13</sup> elbow arthroscopy, using a 2.4 mm, 30° oblique arthroscope (Arthrex, Munich, Germany), was subsequently performed. A novel caudal portal was used to inspect the elbow joint.<sup>9</sup> The presence or absence of medial coronoid disease, a visible HIF, the recently described focal cartilaginous lesion on the caudo-proximal aspect of the humeral condyle,<sup>9</sup> and cartilage damage (using a previously described modified Outerbridge classification system)<sup>14</sup> affecting the medial compartment were recorded. If fragmentation of the medial coronoid process was present, arthroscopic subtotal coronoid ostectomy was performed. An oblique PUO was subsequently performed as previously described<sup>15</sup> with the aim to ameliorate humero-anconeal incongruity. The interosseous ligament was released by placing a Freer periosteal elevator in the space between the proximal radius and ulna, and by application of a force in a distal direction until the portion of the interosseous ligament of the proximal ulnar segment was completely transected. An intramedullary K-wire (1.25–1.4 mm) was then placed into the ulna in a retrograde fashion to prevent excessive caudal displacement of the proximal ulnar segment. The equivalent to 0.75 mg of diboterminal alfa of reconstituted recombinant human bone morphogenetic protein-2 (rhBMP-2) (InductOs, Medtronic BioPharma, Heerlen, Netherlands) was uniformly distributed on a collagen hemostatic matrix (Lyostypt, B. Braun Medical, Sheffield, UK) and was applied at the osteotomy site with the aim to stimulate early bone healing. If previous metallic implants such as transcondylar screws or



**FIGURE 1** Radiographic measurements performed on the medio-lateral view of the affected antebrachium, prior to surgery (A) and at the time of 6-week follow-up radiographs (B). The first line (L1) was drawn and measured from a point at the most cranial aspect of the dorsal cortex of the olecranon to an easily recognizable point at the distal end of the styloid process of the ulna. A second line (L2) was then drawn and measured from an easily recognizable point (such as where the k-wire was engaging the cortex for example) at the caudal aspect of the dorsal cortex of the olecranon to exactly the same point at the distal end of the styloid process of the ulna where the first line ended.

laterally applied plates were present, these were subsequently removed. A compressive bandage was applied for 3 days to limit postoperative swelling.

## 2.2 | Postoperative management

Postoperative analgesia was provided by the administration of methadone (0.2 mg/kg intramuscular, every 4 h) (Comfortan, Dechra, Skipton, UK) whilst in the hospital and oral NSAIDs for 3 weeks whilst at home. Trazodone hydrochloride (5–10 mg/kg, Bristol Laboratories, Berkhamsted, UK) was also dispensed for 6 weeks to reduce anxiety and distress. Upon discharge, the recommended postoperative care regimen included an initial 6-week period of cage rest, followed by an additional 6 weeks of room confinement. Throughout the entire 12-week recovery period, lead-only walks were instructed. Dogs were radiographically reassessed at 6 weeks to assess the degree of healing of the ulnar osteotomy and to screen for possible complications. Complications were classified as described by Cook et al.<sup>16</sup> A follow-up CT scan was then performed at a later date to assess the degree of healing of the HIF.

## 2.3 | Radiographic and CT assessment of the effect of PUO on the ulna

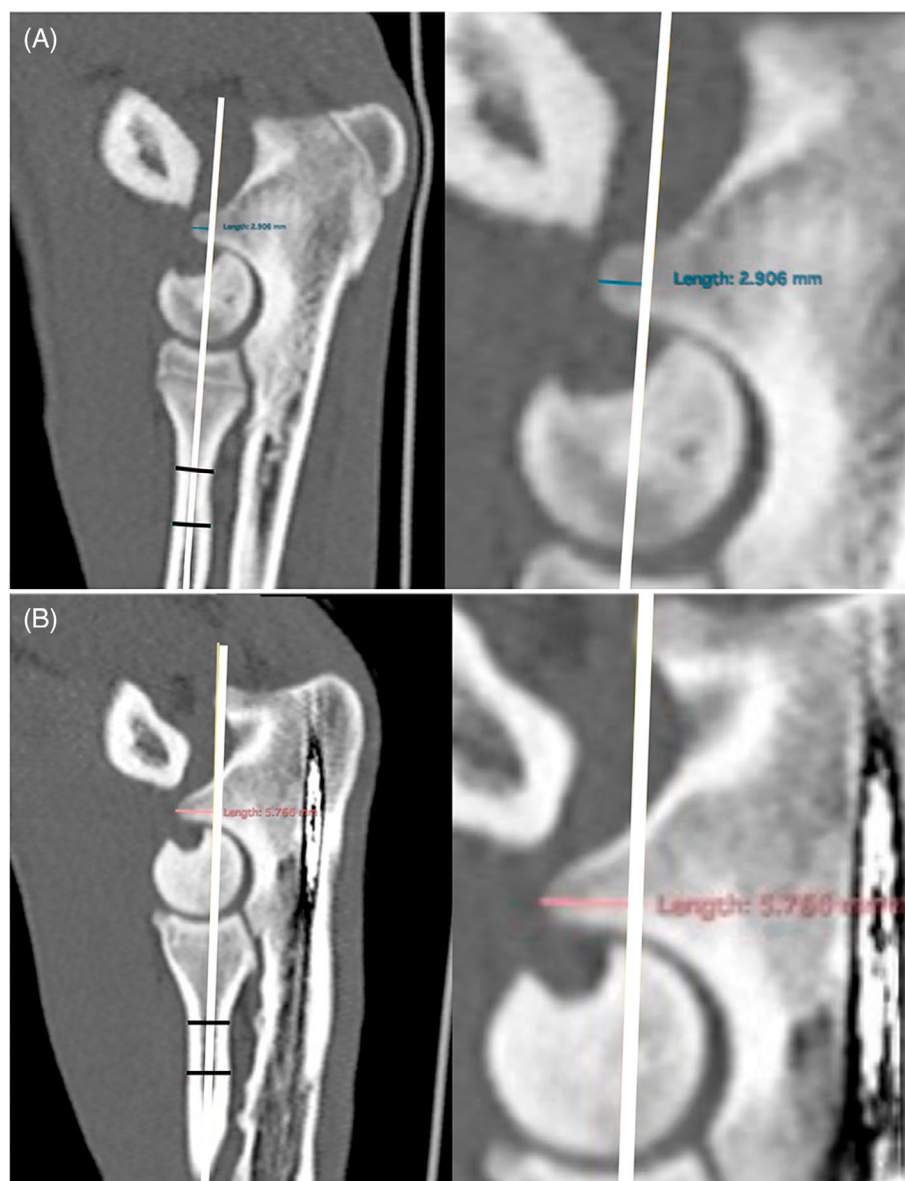
Given that the ulna would not only displace proximally but would also tilt, two measurements (one more cranial and one more caudal) were taken to better assess the magnitude of proximal ulnar displacement. On the preoperative medio-lateral radiograph, two lines (L1, more cranial

and L2, more caudal) were measured to assess the length of the ulna (in millimeters). To normalize these two measurements, the length of both these lines was divided by the width of the radius measured at its exact half (L3) (Figure 1). The same measurements were repeated on the 6-week follow-up radiographs taking particular care in selecting the exact same landmark points that were used on the preoperative images. An increase in ratio of these two measurements was interpreted as proximal displacement of the proximal ulnar segment with subsequent elongation of the ulna as a result of the PUO.

To assess if ulnar elongation corresponded to cranial displacement of the tip of the anconeal process in direction of the supratrochlear foramen, additional measurements were performed on preoperative and follow-up CT images. On sagittal images, the width of the proximal radius was measured in two points and a line intersecting the exact midpoint of these two lines was drawn. A second perpendicular line was drawn from the tip of the anconeal process to the point where the first line intersected the anconeal process. The distance between the tip of the anconeal process and the first line was then measured (Figure 2). A positive change in measurement was interpreted as cranial displacement of the anconeal process as a result of the tilting movement achieved by the PUO. All measurements were performed by the same investigator.

## 2.4 | Objective assessment of HIF healing on CT images

The bone density of the medial and lateral humeral condyle was assessed on coronal planes and recorded in

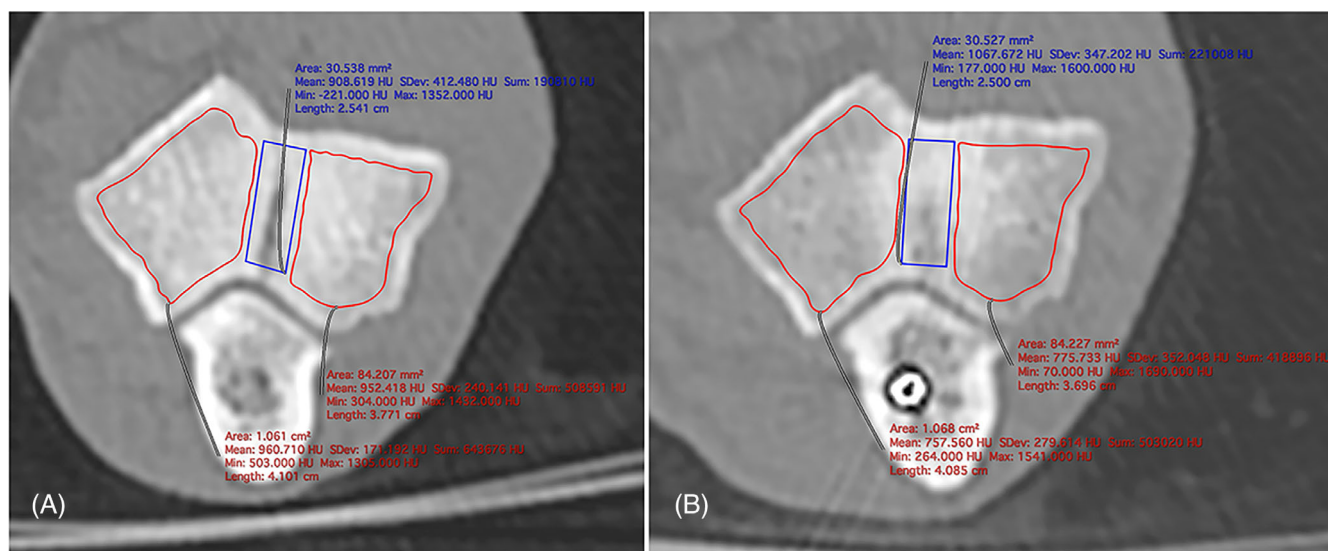


**FIGURE 2** The measurement of the cranial displacement of the tip of the anconeal process in direction of the supratrochlear foramen on preoperative (A) and follow-up (B) computed tomography (CT) scans. On sagittal images, the width of the proximal radius was measured in two points and a line intersecting the exact midpoint of these two lines was drawn. A second perpendicular line was drawn from the tip of the anconeal process to the point where the first line intersected the anconeal process (A1 and B1). The distance between the tip of the anconeal process and the first line was then measured in millimeters (A2 and B2).

Hounsfield units (HU) on the preoperative and last follow-up CT images. A medical image viewer (Horos, New York) and its built-in tools were used to perform the measurements. On the preoperative images, a rectangular region of interest (ROI) (with the area calculated in  $\text{mm}^2$ ) was drawn on the midline of the humeral condyle to include the entirety of the hypoattenuated humeral fissure. In dogs with a complete fissure, this rectangle was extended from the caudal to the cranial aspect of the humeral condyle whilst in dogs with partial fissures, the rectangle was extended from the caudal aspect of the humeral condyle to a cranial direction until where the hypoattenuated line of the fissure ended.

A free-hand ROI was then drawn to separately measure the bone density of the humeral condyle, both medial and lateral to the ROI encompassing the fissure (Figure 3). The selected ROIs were standardized to avoid cortical

bone inside the areas of density measurements. In order to standardize the density values as much as possible, and to reduce the dependence of the results of the spatial orientation of ROIs, three different coronal planes were chosen. The density measurements of these three planes were then summed and divided by three to obtain an average sample bone density value for each elbow. Care was taken to select matching coronal images and the same ROI area's size on preoperative and follow-up CT images to ensure consistency of measurements between time points. All measurements were performed by the same investigator. For those dogs where metallic implants were already present at the time of surgery, a CT scan was repeated following surgery once the metallic implants were removed to avoid metallic artifacts and the hypoattenuated area corresponding to the bone tunnel was not included in the measured ROIs. A decreasing mineral density of the ROIs of



**FIGURE 3** The measurement of the region of interest (ROI) of the humeral condyle on coronal computed tomographic (CT) images. A rectangular ROI (mm<sup>2</sup>) was drawn on the midline of the humeral condyle to include the entirety of the hypoattenuated humeral fissure. In dogs with a complete fissure, this rectangle was extended from the caudal to the cranial aspect of the humeral condyle (A) whilst in dogs with partial fissures, the rectangle was extended from the caudal aspect of the humeral condyle to a cranial direction until where the hypoattenuated line of the fissure ended (B). A free-hand ROI was then drawn to measure separately the bone density of the medial humeral condyle and of the lateral humeral condyle next to the ROI of the fissure. The data provided by the built-in ROI tool included area (mm<sup>2</sup>), mean Hounsfield Units (HU) (with standard deviation and sum), minimum HU recorded, maximum HU recorded, length of the drawn line (cm).

the medial and lateral regions of the humeral condyle was interpreted as reduction of the sclerosis of the bone whilst an increased mineral density of the rectangular ROI of the HIF was interpreted as healing of the fissure.

The bone density of both the medial and lateral regions of the humeral condyle was measured in the same way on CT images of spaniel dogs with no signs of HIF or elbow disease. A standard rectangular area on the midline was excluded from the measurements to account for the possible presence of an hypothetical fissure. This data was used to create a baseline for normal humeral condyle bone density.

The extent of fissure healing at the last follow-up CT scan was also evaluated subjectively, and it was categorized into three groups based on the condition of the HIF observed in the pre-operative images: healed, healing, and not-healing. Dogs where complete healing/bridging of the HIF was achieved were categorized as “healed” whilst those where enlargement of the HIF was noticed were classified as “not-healing.” Dogs with documented evidence of progressive but not complete healing of the HIF were classified as “healing.”

## 2.5 | Statistical analysis

All statistical analyses were performed using software (SPSS version 19, August 2010, SPSS). Results were

expressed as mean  $\pm$  SD for normally distributed variables. Continuous variables in the study were normally distributed (Kolmogorov–Smirnov test  $p > .05$ ). Univariate statistical analyses were performed to evaluate association/correlation between postoperative complications and categorical/continuous variables. Fisher’s exact test was used for discrete variables (i.e., partial/complete HIF and complications). A paired  $t$ -test was used to evaluate the difference between means before and after surgery or at the last follow-up. Independent  $t$ -test was used to evaluate the relationship between continuous variables and categorical variables (i.e., bodyweight and postoperative complications). A Kruskal–Wallis test was used to compare three or more independent samples and a continuous variable (i.e., degree of healing of the HIF after surgery with variables none/partial/complete fissure and weight). Pearson’s correlation was performed to assess linear correlation between continuous variables. Statistical significance was set to  $p < .05$  (type 1 error). For statistical purposes, dogs were divided into three age groups: immature dogs (0–14 months), adult dogs (15–95 months), and old dogs (>96 months).

## 3 | RESULTS

A total of 51 elbows (35 dogs) were included in the study and two dogs were excluded because of the lack of

follow-up CT images. The breeds most commonly represented were English springer spaniel (24), followed by cocker spaniel (8) and cocker × spaniel cross (3). A total of 29 dogs were male and six were female. Six of these dogs were active working dogs at the time of first consultation. At the time of surgery, the mean weight was  $18.08 \pm 3.8$  kg (range 7–23.6 kg) and the mean age was  $47.6 \pm 27.9$  months (range 5–101 months). Twenty percent of dogs were younger than 14 months ( $n = 10$ ) and 4% were older than 96 months. On preoperative clinical examination, 13 elbows (25.5%) had mild discomfort, 23 (45.1%) had moderate discomfort, four (7.9%) had severe discomfort, and 11 (21.5%) had no discomfort on elbow extension. Upon the 6-week follow-up assessment, extension of the elbows resulted in the absence of discomfort in 48 elbows (94%), accompanied by mild discomfort in two elbows, and moderate discomfort in another elbow (notably, these three latter cases coincided with observed cartilage damage determined through arthroscopy). The follow-up CT scan assessment was performed at a mean  $27.21 \pm 8.8$  months.

Surgery to treat HIF had already been performed in nine elbows (four elbows had a transcondylar screw only and four elbows had a transcondylar screw and a plate applied). In four of these elbows an infection was present, in two elbows the implants were poorly placed, in two dogs (two elbows) significant lameness was still present and in one elbow the implant had become loose and was backing out.

### 3.1 | Arthroscopic findings

Arthroscopy confirmed presence of concomitant medial coronoid disease in 12 elbows (23.5%). Radial incisure fragmentation of the medial coronoid process was present in seven elbows, tip fragmentation in two elbows

and a combination of tip-radial incisure fragmentation in four elbows. Concomitant cartilage damage of the medial compartment was present in 10 elbows (ranging from modified Outerbridge grade I to grade IV). The HIF was visible in all but one elbow (98%). Similarly, the focal cartilaginous lesion recently described on the caudal aspect of the humeral condyle of spaniels with HIF was seen in all but two elbows (96%).

### 3.2 | Objective assessment outcomes

On presentation, CT examination revealed the HIF to be partial in 24 elbows (47.1%) and complete in 27 elbows (52.9%). Objective assessment confirmed that a difference was found between the mean HU of the HIF's ROI on preoperative CT images and last-follow-up images ( $p = .001$ ). The same was true for the mean HU of the lateral aspect of the humeral condyle ( $p = .001$ ), the mean HU of the medial aspect of the humeral condyle ( $p = .001$ ), and the total mean HU of the humeral condyle (sum of the medial and lateral aspects of the condyle HUs) ( $p = .001$ ). The average HU of the humeral condyle before surgery was  $1703.7 \pm 294$ , at the last follow-up CT scan was  $1520.7 \pm 206$ , and in normal elbows ( $n = 64$ ) was  $689.5 \pm 105$ . Data also confirmed that young dogs have a wider fissure (HU  $481 \pm 221$  vs. HU  $675 \pm 177$ ;  $p = .03$ ) and less sclerosis of the humeral condyle (HU  $1386 \pm 193$  vs. HU  $1869 \pm 271$ ;  $p = .001$ ) than older dogs.

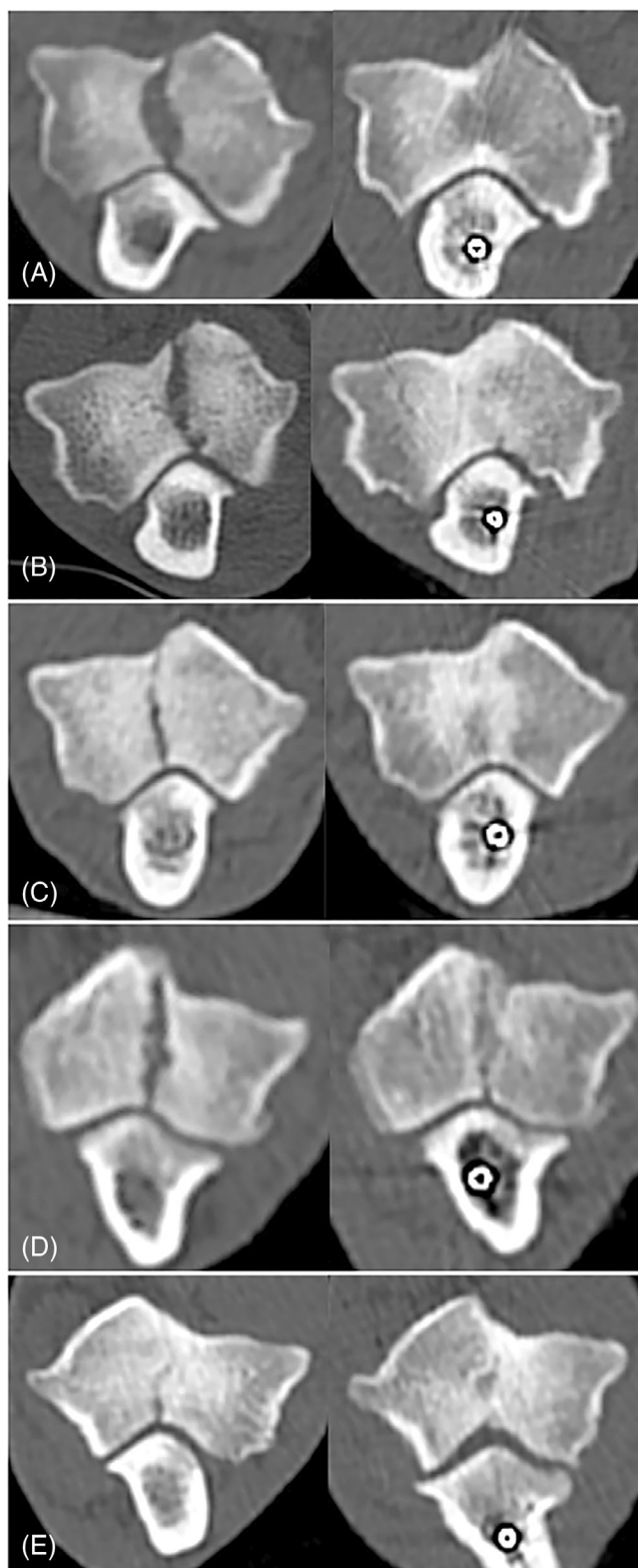
A difference was also found between anconeal tip displacement on pre-operative CT images versus last follow up images ( $p = .001$ ), and between L1 and L2 ratios on preoperative versus 6-week follow-up radiographs ( $p = .001$ ). (Table 1).

Objective assessment confirmed that the age of the dog was predictor of healing of the HIF (Kruskal–Wallis

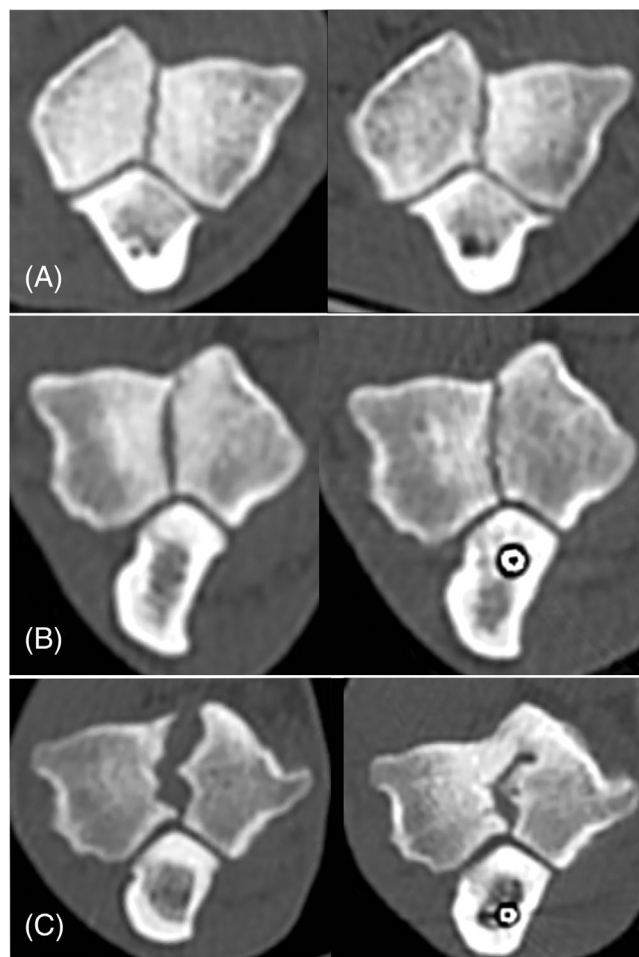
TABLE 1 Summary of imaging assessment.

Measurements	Presurgical	Follow-up	Paired <i>t</i> -test ( <i>p</i> -value)
Radiographic assessment			
Ratio radio ulnar length cranial (L1)	17.60	18.14	.01
Ratio radio ulnar length caudal (L2)	17.68	18.31	.01
CT scan assessment			
HU medial aspect humeral condyle	834.80	735.12	.01
HU lateral aspect humeral condyle	852.01	785.60	.01
HU total condylar region	1686.89	1520.73	.01
HU fissure	640.87	835.20	.01
Anconeal tip displacement (mm)	2.36	3.24	.01

Abbreviations: HU, Hounsfield unit; mm, millimeters.



**FIGURE 4** Examples of good healing of the fissure achieved by performing an oblique proximal ulnar osteotomy (PUO) (left column: preoperative computed tomographic (CT) images; right column: latest follow-up CT images). (A) A 6-month-old english springer spaniel (ESS) (A2: 10-month follow-up). (B) A 7-month-old ESS (B2: 10-month follow-up). (C) A 2-year-old ESS (C2: 18-month follow-up). (D) A 5-year and 8-month-old Cocker x Spaniel cross (D2: 20-month follow-up). (E) A 3-year and 8-month-old ESS (E2: 16-month follow-up).



**FIGURE 5** Examples of progressive healing of the fissure achieved after performing an oblique proximal ulnar osteotomy (PUO) (left column: preoperative computed tomographic (CT) images; right column: latest follow-up CT images). (A) A 2-year-old cocker spaniel (A2: 24-month follow-up). (B) A 4-year-old english springer spaniel (ESS) (B2: 10-month follow-up). (C) An 8-month-old ESS (C2: 18-month follow-up).

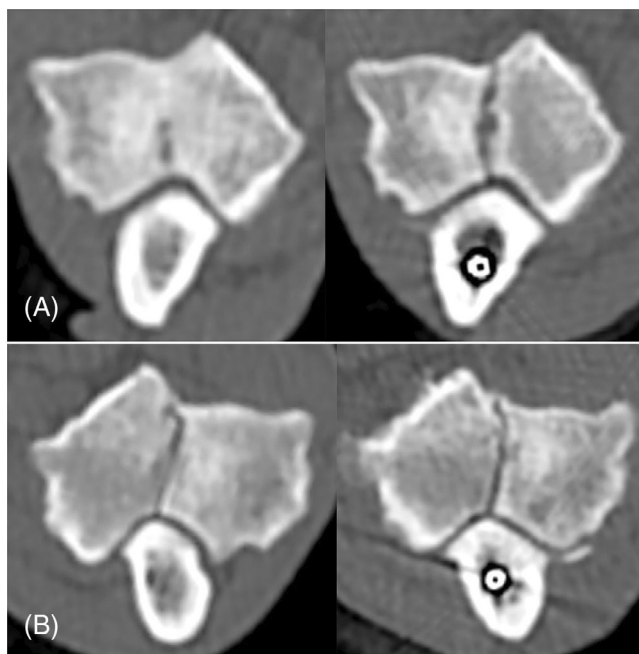
$p = .03$ ). Dogs in the youngest group (0–14 months) had the highest mean increase in HU at the level of the fissure (384.54 units). Dogs in the middle group (15–96 months) had a mean increase of 156 HU, and dogs in the oldest group (>96 months) had a mean decrease of 22.9 HU.

No relationship was found between the objective healing assessment of the fissure on CT scan and the difference in L1 length ratio between pre- and post-treatment ( $p = .278$ , or the difference in L2 length ratio ( $p = .233$ ) or anconeal tip displacement ( $p = .894$ ).

### 3.3 | Subjective assessment outcomes

Subjective assessment revealed the HIF to be healed in 28 elbows (54.9%), to be healing in 13 dogs (25.4%) and to





**FIGURE 6** Example of poor/lack of healing of the fissure after performing an oblique proximal ulnar osteotomy (PUO) (left column: pre-operative computed tomographic (CT) images; right column: latest follow-up CT images). (A) A 3-year-old cocker spaniel (A2: 23-month follow-up). (B) A 6-year 5-month-old english springer spaniel (B2: 24-month follow-up).

be not-healing in seven elbows (13.7%) (two elbows that suffered a fracture in the postoperative period were not included) (Figures 4–6). A nonparametric Kruskal–Wallis test confirmed a positive association between subjective and the objective assessment in terms of fissure healing ( $p = .001$ ).

Subjective assessment confirmed that there was no association between the healing of the HIF and weight or age of the dogs, regardless of whether the degree of healing was categorized as healed, healing or nonhealing. This was determined using  $t$ -tests ( $p = .786$  and  $0.284$ ) and Kruskal–Wallis tests ( $p = .475$  and  $0.183$ ), respectively.

### 3.4 | Complications

Minor complications ( $n = 3$ , 5.8%) were experienced in three limbs and they were due to the intramedullary pin that migrated proximally and needed to be removed under sedation through a stab incision of the skin at the 6-week follow-up appointment. A broken intramedullary pin was noted at the level of the osteotomy at the 6-week follow-up radiographs ( $n = 4$ ). However, due to the fact the bone healing progression at the level of the osteotomy

**TABLE 2** Dogs that sustained major complications.

Dog	Type of major complication	Surgical treatment
Dog 1	Lateral condylar fracture	4.5 mm transcondylar plate and 2.7 mm SOP applied laterally
Dog 2		
Left elbow	Bicondylar “Y” fracture	4.5 mm transcondylar screw, 2.7 mm SOP applied laterally and 2.7 mm LCP applied medially
Right elbow	Persistent intense sclerosis of the humeral condyle and widening of the HIF on 2nd look arthroscopy	4.5 mm transcondylar screw and 2.7 mm LCP applied medially
Dog 3	Lack of healing of the HIF, increased bone production on lateral epicondylar crest, discomfort on manipulation	3.5 mm transcondylar screw and 2.7 mm SOP applied laterally
Dog 4	Broken IM pin and excessive displacement of the proximal ulnar segment	Pin removal, debridement of bone ends, realignment of ulnar segments, placement of larger size IM pin, BMP application
Dog 5	Nonunion PUO	Debridement, removal of the IM pin, application of a 2.7 mm locking plate, bone graft and BMP

Abbreviations: BMP, bone morphogenetic proteins; HIF, humeral intracondylar fissure; IM, intramedullary pin; LCP, locking compression plate; mm, millimeters; PUO, proximal ulnar osteotomy; SOP, string of pearls locking plate.

was already considered satisfactory at that stage and that the outcome and the postoperative care were not changed following this discovery, these cases were not classified as having minor complications. Major complications were encountered in five dogs (six limbs); four of these major complications were related to healing of the fissure (7.8%) whilst two were related to healing of the PUO (3.9%) (Table 2).

Dog 1 experienced a lateral condylar fracture following a slip on a wet surface 3 months after the initial

surgery. Dog 2 had a follow-up CT scan performed 1 year and 4 months after surgery which revealed almost complete healing of the partial fissure previously present, bilaterally. However, the owner contacted us again 2 months later reporting a certain degree of stiffness (bilaterally) that was previously not present. One month later the dog suddenly screamed in pain and a Y-fracture was diagnosed on radiographs. CT scan of the contralateral elbow was concomitantly performed, and it revealed no improvement of the degree of sclerosis of the humeral condyle and also that, at the most caudo-proximal aspect of the humeral condyle, the fissure was mildly visible again. A decision to prophylactically stabilize the humeral condyle with a transcondylar screw and a medially applied plate was taken to prevent a fracture at the same time of performing the repair of the Y-fracture. The owner of dog 3 reported persistent lameness despite a transcondylar screw having been placed elsewhere several months earlier. The screw was removed and an oblique PUO was performed. A CT scan performed 1 year and 9 months after the surgery revealed that the bone tunnel left by the screw was still present. It also revealed that new bone had formed in the center of the condyle at the level of the HIF, but that the fissure itself was still surprisingly visible within the newly formed bone. The dog did not appear lame or stiff at this stage. Six months later, the owner started reporting occasional lameness and a repeat CT scan confirmed the lateral epicondylar crest to be visibly thicker and more sclerotic than what it previously was, suggesting presence of persistent instability. A transcondylar screw and a locking plate were applied to prevent fracture development.

No association could be found between the variables assessed in this study (age:  $p = .420$  and weight:  $p = .984$ ) and the development of complications or the need for revision surgery.

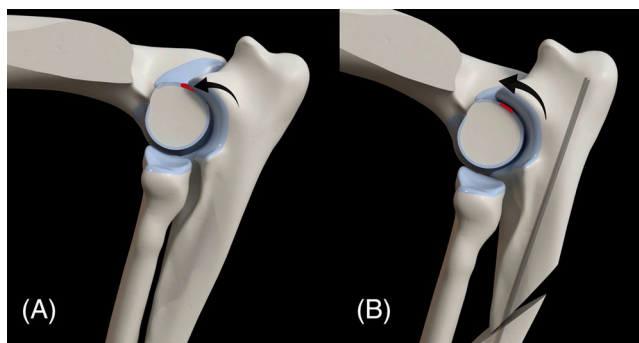
At the time of writing this manuscript (median time of 30 months from when surgery was performed), all owners were contacted again either by email or by telephone for an update and no additional complications or problems were reported.

## 4 | DISCUSSION

This study objectively demonstrated that performing an oblique PUO in dogs with HIF resulted in healing of the HIF and concomitant reduction of the sclerosis of the humeral condyle in the majority of dogs. The hypothesis of this study was therefore accepted.

Humeral intracondylar fissure has been reported in both adult and young spaniel breed dogs and its etio-pathogenesis is still under debate.<sup>3-5,7,8</sup> In the authors'

opinion, the different manifestations of humero-anconeal incongruity in young and old dogs (wider fissure and less sclerosis in young dogs, increased sclerosis and stress fracture formation in older dogs) are likely caused by the same underlying conformational issue. The combined axial and rotational loading of the tip of the anconeal process against the caudo-proximal aspect of the medial aspect of the humeral condyle during weightbearing may in fact prevent the fusion of the humeral condylar ossification centers in young dogs, and lead to stress fracture formation in older dogs. This seems to be supported by our analysis, which confirmed that young dogs have a wider fissure and less sclerosis of the humeral condyle than older dogs. A recent publication about dogs with HIF described the tip of the anconeal process to perfectly match a focal cartilaginous lesion present on the caudo-proximal aspect of the humeral condyle when arthroscopy was performed and the elbow was held at a weight-bearing angle.<sup>9</sup> This was described as humero-anconeal incongruity and in a recent case report this type of joint incongruity was believed to be the cause of HIF formation in an almost completely skeletally mature dog. Joint incongruity can create stresses within the humeral condyle that can either prevent ossification or promote a stress fracture.<sup>17</sup> Fatigue fractures (also commonly called "stress fractures") are the result of abnormal cyclical loading on normal bone.<sup>18</sup> As stress on bone is increased, it begins to deform through the bone's elastic range but can ultimately return to its original configuration. Stress beyond the elastic range creates microfractures and persistent plastic deformity. Eventually these microfractures coalesce into a discontinuity within the cortical bone taking the name of stress fracture.<sup>18</sup> Histological studies of stress fractures show that repetitive response to stress leads to osteoclastic activity that surpasses the rate of osteoblastic new bone formation, resulting in temporary weakening of the bone. If the osteoclastic activity continues to exceed the rate of osteoblastic new bone formation, a full cortical break occurs.<sup>19,20</sup> In humans, it is still under debate whether stress fractures occur owing to the increased load after fatigue of supporting structures or to contractile muscular forces acting across and on the bone but, in principle, both factors are thought to contribute to it.<sup>20-22</sup> In baseball players, the tip of the olecranon is forced into the olecranon fossa during rapid elbow extension which leads to compensatory compression on the medial aspect of the olecranon-olecranon fossa articulation. This compression is believed to be caused by repetitive abutment of the olecranon against the olecranon fossa, triceps traction on the olecranon during the deceleration phase of throwing, and medial olecranon impaction onto the olecranon fossa due to valgus stress.<sup>23-25</sup> Whilst the human olecranon has a similar but more open



**FIGURE 7** Schematic representations of the motion of the ulna relative to the humeral condyle and the focal cartilaginous lesion. (A) 3D representation of the conflict between tip of the anconeal process and the caudal aspect of the humeral condyle, leading to the formation of a focal cartilaginous lesion (red dot) (humero-anconeal incongruity). (B) 3D representation of the humero-ulnar relationship after performing an oblique proximal ulnar osteotomy (PUO), illustrating proximo-cranial displacement of the tip of the anconeal process in direction of the supratrochlear foramen and hypothetical amelioration of humero-anconeal incongruity.

semilunar notch, it lacks a prominent anconeal process such as dogs have. When humero-anconeal incongruity is present, such a prominent process may apply a supra-physiological cyclic force to the caudo-proximal aspect of the humeral condyle (at level of where the focal cartilaginous lesion is) which will result in cumulative bone strain leading to bone damage and fracture if net bone damage exceeds bone repair.

Our study found that PUO causes the tip of the anconeal process to move in a cranio-proximal direction. This suggests that the tip of the anconeal process will no longer apply an abnormal load on the caudal aspect of the humeral condyle at the level of the cartilaginous lesion during weight bearing (Figure 7). Halting this repetitive mechanical overload of the humeral condyle should lead to rebalance of the osteoblastic/osteoclastic activity and lead to healing of the skeletal lesion, which in our study was achieved in 80% of elbows.

In this study, release of the interosseous ligament was considered an essential part of the surgery aimed at achieving proximal displacement and tilting of the proximal ulnar segment. The osteotomy cut was started 1–2 cm distal to the radial head at level of where the periosteal elevator can physically be inserted in the space between radius and ulna. The interosseous ligament was then disrupted all the way distally until the proximal ulnar segment was completely released. In most cases, a small osteotome was necessary to release the most distal part of the proximal ulnar segment due to mineralized-like adhesions that were present at that specific level and

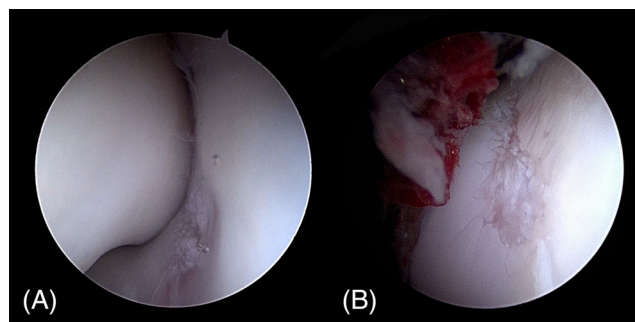
that could not be broken with the periosteal elevator alone. The placement of an intramedullary pin is considered crucial following the release of the interosseous ligament due to the elevated risk of excessive caudal displacement of the proximal ulnar segment and we consistently aimed to insert the smallest feasible intramedullary (IM) pin, engaging the distal ulnar segment by only 2–3 cm. This enabled the intended caudal displacement of the proximal ulnar segment to be attained until the pin made contact with the caudal cortex of the distal segment and the cranial cortex of the proximal ulnar segment. Human recombinant bone morphogenetic protein-2 (a human protein with osteoinductive activity that leads to accelerated bone healing)<sup>26,27</sup> was routinely used in all dogs older than 8 months to promote bone union of the two ulnar segments as there was a concern about the risk of delayed or nonunion, which is reported to be as high as 31.1% in a recent manuscript analyzing the complication rate following oblique PUO in dogs.<sup>28</sup> In this study, this type of complication was drastically reduced to 1.9% (1/51 case of delayed union). Although it is difficult to make a direct comparison to this recent study, we suspect that our lower complication rate is associated to early healing of the osteotomy, which is anecdotally difficult to achieve in adult and old dogs, and is attributable to the use of rhBMP-2. Nevertheless, it is important to take into account other factors that may explain the reduced incidence of delayed- or nonunions observed in our cases. These may include the use of an ulnar intramedullary pin, the use of a new sagittal blade in all surgeries and the meticulous attention given to thorough irrigation of the bone and of the blade with a cold sterile solution during the cutting procedure (to minimize damage to the cellular environment).

The results of this study confirmed our clinical impression that the degree of healing of HIF in dogs younger than 14-months-old is superior than in older dogs. Histological samples harvested from the fissure line of adult dogs revealed presence of amorphous and necrotic material and of significant amount of intermediate fibroconnective and cartilaginous tissue surrounded by two borders of osteosclerosis.<sup>6,29</sup> It is intuitive to think that the amount of fibrous and necrotic tissues present in the HIF of an older dog would somehow impede or at least slow down the healing of the fissure. In young dogs, instead, this does not seem to be the case as we suspect that the superior healing activity and bone metabolism of a young dog can relatively easily overcome the presence of a smaller amount of fibrotic and/or necrotic tissue present within the fissure and lead to complete healing of the bone defect. Additionally, young dogs are favored by an increased vascular capacity or angiogenicity at the site of skeletal repair that also contributes to accelerate the

healing process.<sup>30</sup> On the contrary, angiogenesis has been shown to be impaired as a function of age in two different animal models and cocker spaniels aged between 2- and 3-years-old have been shown to have a decrease in the number and density of vessels within the humeral condyle when compared to a noncocker spaniel control group.<sup>31,32</sup> Lastly, it has to be noted that the sclerosis present on either side of the fissure of older dogs can further act as an important barrier to angiogenesis across the fissure.

A histological characteristic of sclerotic bone is a significant reduction in vascular supply of the affected area. Due to its impact on the vascular supply of the humeral condyle, the authors suspect that the sclerosis of the humeral condyle plays a crucial role in influencing the degree of healing of the fissure. In certain cases where severe sclerosis of the condyle was observed on preoperative CT images, the fissure width and length initially increased before subsequently reducing. These instances indicated the persistent presence of severe sclerosis of the humeral condyle during the first follow-up CT assessment, coinciding with the period when the fissure appeared enlarged. However, the sclerosis notably decreased by the time of the last follow-up CT scan when the fissure exhibited a reduction in size. Although statistical significance was not achieved ( $p = .120$ ), indications of a potential association between subchondral sclerosis resolution and fissure healing have arisen. It is plausible that the limited case number in our study has contributed to this outcome, potentially leading to a type II error.

Sclerotic bone has been shown to have reduced creep responses in cortical and trabecular bone.<sup>33</sup> This may bear implications in terms of increased microcrack propagation and altered mechanical load distribution thereby implying reduced bone toughness and increased stiffening during cyclic loading.<sup>33</sup> Stiffer materials are generally more brittle and this means that they are more likely to suddenly break without warning. This would explain the authors' conjecture that the severely sclerotic humeral condyle of an adult dog is more susceptible to sudden catastrophic failure than the humeral condyle of a young dog with a large HIF. Dog 2 suddenly experienced a Y-fracture of the left elbow without any warning except for stiffness at the time of getting up from lying down. The 1 year 4-month follow-up CT scan confirmed that the partial fissure had healed but that intense sclerosis of the humeral condyle was still present. Arthroscopy of the fractured elbow was repeated immediately prior to fracture repair. Whilst the original focal cartilaginous lesion appeared to have some degree of fibrocartilage coverage, the lesion was more proximally elongated in the direction of the supratrochlear foramen (along the sagittal plane) (Figure 8). This would suggest that the cranio-proximal



**FIGURE 8** Arthroscopic view of the left elbow of dog 2 using the caudal portal. (A) Preoperative view of the focal cartilaginous lesion caused by humero-anconeal incongruity. (B) Arthroscopic view of the cartilaginous lesion performed at the time of bicondylar fracture repair 19 months after the initial surgery. The initial focal lesion seems to be covered by a thin layer of fibrocartilage and the cartilage damage seems to be extending more proximally, along the sagittal plane, in direction of the supratrochlear foramen.

displacement achieved by the anconeal process was insufficient to completely resolve humero-anconeal incongruity and that some degree of cyclical overload was still applied to the humeral condyle by the anconeal process. These findings are contrasting with the result of the second-look arthroscopy of the contralateral elbow which confirmed that, despite the fact that the anconeal process was more proximally displaced into the supratrochlear foramen and the partial thickness focal cartilaginous lesion had healed, the intracondylar fissure was wider than what it initially was. Whilst the fissure was not so visible on last follow-up CT images, the humeral condyle appeared to be still severely sclerotic (mean HU of the humeral condyle before surgery: 1085, at the first follow-up: 782, at the last follow-up: 941). It is not clear if the widening of the fissure and the increased sclerosis are due to the anconeal process not displacing proximo-cranially enough or to impaired vascularization of the humeral condyle.

Traditional surgical treatment of this condition involves placement of a transcondylar screw to bridge the fissure, stabilize the condyle and reduce the risk of fracturing.<sup>34–37</sup> Healing of fissures following this type of surgical treatment has been inconsistently reported in the veterinary literature. Although data from a few studies suggest that up to 77% of fissures can heal or reduce in size,<sup>3,16,28,37–39</sup> it is important to note that the data presented may be influenced by the limitations of radiographs as a sensitive method for objectively assessing the degree of fissure healing.<sup>40,41</sup> In certain cases, even diagnosing the presence of HIF itself can be exceptionally challenging, further questioning the accuracy of these results. Additionally, it is important to acknowledge that

the use of postoperative advanced imaging such as CT as a method to reliably assess the degree of healing of the fissure is limited by the presence of the transcondylar screw and the metallic artifacts it generates. Use of allograft or autograft in combination with a strong implant fixation have also been described to manage these challenging nonhealing stress fractures but lack of adequate sequential imaging, of objective assessment of the degree of healing and presence of metallic implants precludes the reliable assessment of the degree of healing achieved.<sup>38,39</sup> In our study, absence of metallic implants allowed us to reliably and objectively assess the degree of HIF healing in all elbows.

The overall complication rate following a transcondylar screw placement is notably high and varies from 15% to 69.2%. Seroma appears to be the most common minor complication and ranges from 7.1% to 44%. Surgical site infection (SSI) is instead the most reported major complication following the use of a transcondylar screw and it has an incidence of up to 42.3%.<sup>34,36,37,42–46</sup> This incidence of SSI vastly exceeds the average reported SSI rate for clean, elective orthopedic surgeries and it has been linked in several studies with a poor long-term outcome. Other commonly reported major complications include implant failure (with an incidence of broken screws ranging from 2.5% to 9%), implant loosening (1.2%–9%) and medial epicondylar fissure fracture (16.5%).<sup>17,35–37,42–46</sup> By avoiding placing a transcondylar screw, all the aforementioned complications were avoided in our study. The minor complication related to migration of the IM pin that we experienced was attributed to the creation of a larger hole and the use of a smaller diameter IM pin, intended to facilitate breaking of the pin below the proximal cortex of the anconeus to avoid impingement of the insertion of the triceps brachii tendon. When it became clear that creating a larger hole at the level of the cortex contributed to pin migration, we returned to using the same size pin that was broken at the level of the cortex of the anconeus. We acknowledge that some surgeons may be reluctant to consider using an IM pin in the ulna due to the potential risks of infection and difficulty of retrieval of the metalwork. However, in this study, no infections were experienced, and the IM pins were easily retrieved in those dogs where they migrated or when ulnar osteotomy revision surgery was needed. Performing a PUO is certainly not a procedure free of complications and these can include excessive proximal segment caudal migration, delayed osteotomy union, infection, seroma formation, hemorrhage and radial head subluxation.<sup>15,28,47,48</sup> In this study, two major complications were experienced at level of the osteotomy site: one hypertrophic nonunion of the osteotomy (which required debridement, grafting with autologous cancellous bone and

stabilization with a locking plate) and excessive caudal displacement of the proximal ulnar segment (which required debridement, retrieval of the broken pin, reduction of the ulnar segments back into position and replacement of the IM pin with a larger one). Despite these two complications, a large callus osseous formation was documented in all dogs at the 6-week follow-up appointment most likely as a result of the use of rhBMP-2. The overall complication rate related to oblique PUO was 9.8%, consisting of two major and three minor complications. This rate was significantly lower than the complication rates reported in the literature, which range from 13% to 54%.<sup>15,28,47,48</sup> While this complication range is similar to the reported complication rate associated to the use of a transcondylar screw as a treatment for HIF (15%–69%), we believe that the complications associated with PUO are generally more benign and easily addressed. Moreover, these complications do not seem to impact the long-term outcome to the same extent as the complications associated with the use of a transcondylar screw. Lastly, while it is generally accepted that dogs undergoing PUO experience more pain in the postoperative period than dogs undergoing screw placement, this study found that the majority of dogs were pain-free at the 6-week follow-up appointment. We suspect that this is due to the high degree of bone healing achieved at the osteotomy site (by the combined use of rh-BMP-2 and of the IM pin) and to the amelioration of humero-anconeal incongruity.

In a study where 34 dogs with HIF were managed conservatively, 18% of these subsequently experienced a fracture at a mean of 14 months and two dogs needed placement of a screw at a later stage to treat persistent lameness, increasing to 23.5% the rate of dogs needing surgery.<sup>4</sup> The same study reported that the mean follow-up for dogs not requiring surgery was 56 months, concluding that a low number of nonsymptomatic HIFs will fracture and that if this happens, it is most likely to happen within 2 years from when the diagnosis is performed.<sup>4</sup> In this study, the rate of dogs needing revision surgery to address a fracture (3.9%) or to treat an unstable humeral condyle (3.9%) was considerably lower (7.8%) with a median follow-up for all dogs of 30 months. Four major HIF-related complications were experienced in three dogs. Dog 2, as previously discussed, suffered a Y-fracture of the left elbow and had a transcondylar screw and a medial plate applied to the right elbow to prevent a fracture. Dog 3 sequential CT scans revealed that the fissure was still present 16 months after surgery and that a large amount of new sclerotic bone formation was present at level of the lateral epicondylar crest. The medial compartment of the elbow appeared to be collapsed medially more than what it was at the time of the initial surgery, potentially increasing the force applied to

the lateral aspect of the humeral condyle by the radial head therefore causing excessive instability. The humeral condyle was stabilized with a 3.5 mm mediolateral transcondylar screw and one 2.7 mm locking plate applied laterally. Dog 1 (which previously had suboptimal placement of a 4.5 mm transcondylar screws) slipped on a wet sea slipway and suffered a lateral condylar fracture of the right humerus 5 months after having PUO and screw removal performed. Six weeks after the first surgery was performed on the right antebrachium, this dog underwent surgery on the left side to remove a suboptimally placed transcondylar screw and to perform an oblique PUO to treat a partial HIF. The follow-up CT scan of the left elbow performed 1 year later demonstrated complete infilling of the hole left by the screw and complete healing of the partial HIF initially diagnosed.

In humans, nonsurgical management is generally recommended for sclerotic stress fractures. The resolution of such fractures can take up to 6 months as they tend to heal at a slower pace compared to complete fractures.<sup>25,49</sup> Being aware of this, we typically discharge dogs with instructions of lead-only walk for 3 months but we also recommend that clients keep their dogs on the lead for the majority of walks for up to 6 months, and only return to normal off-lead exercise after that time. We suspect that dog 1 engaged in vigorous exercise too soon and the trauma happened when the stress fracture was still in an early healing phase. The long recovery phase is an important drawback of performing a PUO compared to stabilization with a transcondylar screw, which allows for a faster return to normal activity. However, we believe that the long-term benefits of achieving healing of the fissure and avoidance of postoperative complications such as screw breakage/loosening and infection, vastly outweigh this negative factor. Some exceptions are to be made. Since this study was concluded, the authors routinely perform a PUO and place a transcondylar screw in dogs older than 8 years (due to the documented poor healing of the fissure in older dogs), in adult dogs that present with severe sclerosis of the humeral condyle (due to the high risk of sudden fracture) and in the adult dogs of clients that are not willing to strictly follow the postoperative instructions.

This study has also demonstrated that performing a PUO can be considered as a revision strategy for dogs experiencing major complications after the placement of a transcondylar screw. In four dogs, chronic infection and signs of implant loosening were observed, leaving amputation the only option considered by the referring veterinarians. In all these dogs, the implants were removed and an oblique PUO was performed. Follow-up CT scans confirmed complete healing of the HIF in all these dogs, even

though the bone tunnels left by the previous implants were still visible. Notably, a severely sclerotic border was observed along these bone tunnels, which is suspected to have impeded neovascularization of this area, subsequently hindering the process of bone formation. The authors now commonly perform a debridement of the sclerotic borders of the bone tunnels by over-drilling the hole with a larger drill bit followed by packing of autologous cancellous bone graft into the tunnel.

A number of limitations need to be acknowledged in this retrospective study. The most important limitation is the absence of second-look arthroscopy to confirm the resolution of humero-ulnar incongruity (and healing of the cartilaginous lesion). With the data currently available, the study can only conclude that the condition was ameliorated. However, from an ethical point of view, it was not justifiable to perform such a procedure in dogs that were clinically well and sound on the operated limbs. Other limitations include the lack of a control group, a relatively small sample size, lack of objective measurement of clinical outcomes and lack of assessment of intra- and interobserver variability in the measurement of ROIs on CT images and ulnar length on radiographs.

In conclusion, this study provides compelling evidence to support our hypotheses that oblique PUO effectively leads to proximal displacement and tilting of the proximal ulnar segment, resulting in cranial displacement of the tip of the anconeal process towards the supratrochlear foramen, and subsequent healing of the HIF in the majority of dogs. These findings suggest that an oblique PUO is a viable and promising treatment option for HIF, especially in young dogs.

#### AUTHOR CONTRIBUTIONS

Danielski A, DVM, DipECVS: performed all surgical procedures, conceived and designed the study, contributed to data collection and analysis, drafted, revised and approved the submitted manuscript. Quinonero Reinaldos I, DVM: contributed to data collection and analysis, revision and approval of the submitted manuscript. Solano MA, DVM, DipECVS: contributed to data collection and statistical analysis, revision and approval the manuscript. Fatone G, DVM, PhD: contributed to revision and final approval of the manuscript. All authors provided a critical review of the manuscript and endorsed the final version. All authors are aware of their respective contributions and have confidence in the integrity of all contributions.

#### CONFLICT OF INTEREST STATEMENT

The authors declare no conflicts of interest related to this report.

## ORCID

Alan Danielski  <https://orcid.org/0000-0002-1558-602X>  
 Ignacio Quinonero Reinaldos  <https://orcid.org/0009-0005-9794-6496>

## REFERENCES

- Denny HR. Condylar fractures of the humerus in the dog: a review of 133 cases. *J Small Anim Pract.* 1983;24:185-197.
- Vannini R, Olmstead ML, Smeak DD. Humeral condylar fractures caused by minor trauma in 20 adult dogs. *J Am Anim Hosp Assoc.* 1988;24:355-362.
- Meyer-Lindenberg A, Heinen V, Fehr M, Nolte I. Incomplete ossification of the humeral condyle as the cause of lameness in dogs. *Vet Comp Orthop Traumatol.* 2002;15:187-194.
- Moores AP, Moores AL. The natural history of humeral intracondylar fissure: an observational study of 30 dogs. *J Small Anim Pract.* 2017;58:337-341.
- Moores AP. Humeral Intracondylar fissure in dogs. *Vet Clin North Am Small Anim Pract.* 2021;51(2):421-437.
- Marcellin-Little DJ, DeYoung DJ, Ferris KK, et al. Incomplete ossification of the humeral condyle in spaniels. *Vet Surg.* 1994; 23:475-487.
- Witte PG, Bush MA, Scott HW. Propagation of a partial incomplete ossification of the humeral condyle in an American cocker spaniel. *J Small Anim Pract.* 2010;51:591-593.
- Farrell M, Trevail T, Marshall W, Yeadon R, Carmichael S. Computed tomographic documentation of the natural progression of humeral intracondylar fissure in a cocker spaniel. *Vet Surg.* 2011;40:966-971.
- Danielski A, Yeadon R. Humero-anconeal elbow incongruity in spaniel breed dogs with humeral intracondylar fissure: arthroscopic findings. *Vet Surg.* 2022;51(1):117-124.
- Turner BM, Abercromby RH, Innes J, McKee WM, Ness MG. Dynamic proximal ulnar osteotomy for the treatment of ununited anconeal process in 17 dogs. *Vet Comp Orthop Traumatol.* 1998;11:76-79.
- Fitzpatrick N, Yeadon R. Working algorithm for treatment decision making for developmental disease of the medial compartment of the elbow in dogs. *Vet Surg.* 2009;38(2):285-300.
- Karydas S, Danielski A. Proximal ulnar osteotomy as a treatment for humeral Intracondylar fissure in a Shetland sheepdog. *Animals (Basel).* 2023;13(3):519.
- Carrera I, Hammond GJC, Sullivan M. Computed tomographic features of incomplete ossification of the canine humeral condyle. *Vet Surg.* 2008;37:226-231.
- Farrell M, Heller J, Solano M, Fitzpatrick N, Sparrow T, Kowaleski M. Does radiographic arthrosis correlate with cartilage pathology in Labrador Retrievers affected by medial coronoid process disease? *Vet Surg.* 2014;43(2):155-165.
- Caron A, Fitzpatrick N. Bi-oblique dynamic proximal ulnar osteotomy: surgical technique and clinical outcome in 86 dogs. *Vet Surg.* 2016;45(3):356-363.
- Cook JL, Evans R, Conzemius MG, et al. Proposed definitions and criteria for reporting time frame, outcome and complications for clinical orthopaedic studies in veterinary medicine. *Vet Surg.* 2010;39(8):905-908.
- Butterworth SJ, Innes JF. Incomplete humeral condylar fractures in the dog. *J Small Anim Pract.* 2001;42:394-398.
- Fredericson M, Jennings F, Beaulieu C, Matheson GO. Stress fractures in athletes. *Top Magn Reson Imaging.* 2006;17(5): 309-325.
- Li G, Zhang S, Chen C, et al. Radiographic and histologic analysis of stress fracture in rabbit tibias. *Am J Sports Med.* 1985;13: 285-294.
- Stanitski CL, McMaster JH, Scranton PE. On the nature of stress fractures. *Am J Sports Med.* 1978;6:391-396.
- Markey KL. Stress fractures. *Clin Sports Med.* 1987;6(2): 405-425.
- Daffner RH, Pavlov H. Stress fractures: current concepts. *AJR Am J Roentgenol.* 1992;159(2):245-252.
- Mauro CS, Hammoud S, Altchek DW. Ulnar collateral ligament tear and olecranon stress fracture nonunion in a collegiate pitcher. *J Shoulder Elbow Surg.* 2011;20(7):e9-e13.
- Smith SR, Patel NK, White AE, Hadley CJ, Dodson CC. Stress fractures of the elbow in the throwing athlete: a systematic review. *Orthop J Sports Med.* 2018;6(10).
- Greif DN, Emerson CP, Allegra P, Shallop BJ, Kaplan LD. Olecranon stress fracture. *Clin Sports Med.* 2020;39(3): 575-588.
- Schaefer SL, Lu Y, Seeherman H, Li XJ, Lopez MJ, Markel MD. Effect of rhBMP-2 on tibial plateau fractures in a canine model. *J Orthop Res.* 2009;27(4):466-471.
- Schmiedt CW, Lu Y, Heaney K, Muir P, Amodie DM, Markel MD. Comparison of two doses of recombinant human bone morphogenetic protein in absorbable collagen sponges for bone healing in dogs. *Am J Vet Res.* 2007;68(8):834-840.
- Danielski A, de Marcos CI, Danielski C, Farrell M, Solano MA. Lower body weight and increasing age are significant risk factors for complications following bi-oblique proximal ulnar osteotomy in dogs. *J Am Vet Med Assoc.* 2023;1:1-7.
- Gnudi G, Martini FM, Zanichelli S, et al. Incomplete humeral condylar fracture in two English pointer dogs. *Vet Comp Orthop Traumatol.* 2005;18(4):243-245.
- Tomlinson RE, McKenzie JA, Schmieder AH, Wohl GR, Lanza GM, Silva MJ. Angiogenesis is required for stress fracture healing in rats. *Bone.* 2013;52(1):212-219.
- Rivard A, Fabre JE, Silver M, et al. Age-dependent impairment of angiogenesis. *Circulation.* 1999;99(1):111-120.
- Larsen LJ, Roush JK, McLaughlin RM, et al. Microangiography of the humeral condyle in cocker spaniel and non-cocker spaniel dogs. *Vet Comp Orthop Traumatol.* 1999;12:134-137.
- Chen X, Goh JC, Teoh SH, De SD, Soong R, Lee T. Localized sclerotic bone response demonstrated reduced nanomechanical creep properties. *J Mech Behav Biomed Mater.* 2013;17:198-208.
- Moores AP, Tivers MS, Grierson J. Clinical assessment of a shaft screw for stabilization of the humeral condyle in dogs. *Vet Comp Orthop Traumatol.* 2014;27:179-185.
- Moores A. Humeral condylar fractures and incomplete ossification of the humeral condyle in dogs. *In Pract.* 2006;28:391-397.
- Hattersley R, McKee M, O'Neill T, et al. Postoperative complications after surgical management of incomplete ossification of the humeral condyle in dogs. *Vet Surg.* 2011;40:728-733.
- Chase D, Sul R, Solano M, Calvo I, Joslyn S, Farrell M. Short- and long-term outcome after transcondylar screw placement to treat humeral intracondylar fissure in dogs. *Vet Surg.* 2019;48:299-308.
- Walton MB, Crystal E, Morrison S, et al. A humeral intracondylar repair system for the management of humeral

- intracondylar fissure and humeral condylar fracture. *J Small Anim Pract.* 2020;61(12):757-765.
39. Fitzpatrick N, Smith TJ, Riordan J, Yeadon R. Treatment of incomplete ossification of the humeral condyle with autogenous bone grafting techniques. *Vet Surg.* 2009;38(2):173-184.
  40. Martin RB, Crews L, Saveraid T, Conzemius MG. Prevalence of incomplete ossification of the humeral condyle in the limb opposite humeral condylar fracture: 14 dogs. *Vet Comp Orthop Traumatol.* 2010;23(3):168-172.
  41. Piola V, Posch B, Radke H, Telintelo G, Herrtage ME. Magnetic resonance imaging features of canine incomplete humeral condyle ossification. *Vet Radiol Ultrasound.* 2012;53(5):560-565.
  42. McCarthy J, Woods S, Mosley JR. Long-term outcome following management of canine humeral intracondylar fissure using a medial approach and a cannulated drill system. *Vet Rec.* 2020;186(15):490.
  43. Jenkins G, Moores AP. Medial epicondylar fissure fracture as a complication of transcondylar screw placement for the treatment of humeral intracondylar fissure. *Vet Surg.* 2022;51(4):600-610.
  44. Carwardine D, Burton NJ, Knowles TG, Barthelemy N, Parsons KJ. Outcomes, complications and risk factors following fluoroscopically guided transcondylar screw placement for humeral intracondylar fissure. *J Small Anim Pract.* 2021;62(10):895-902.
  45. Carwardine D, Mather A, Schofield I, et al. Medial versus lateral transcondylar screw placement for canine humeral intracondylar fissures: a randomized clinical trial. *Vet Surg.* 2023;1-13.
  46. Potamopoulou M, Brown G, Whitelock R. Correlation between the insertion side of a transcondylar screw for the surgical Management of Humeral Intracondylar Fissures in dogs and the incidence of postoperative surgical site infection. *Vet Comp Orthop Traumatol.* 2023;36:311-316.
  47. Gilson SD, Piermattei DL, Schwarz PD. Treatment of humeroulnar subluxation with a dynamic proximal ulnar osteotomy. A review of 13 cases. *Vet Surg.* 1989;18:114-122.
  48. Williams H, Arthurs G, Burton N, Kulendra E, Radke H, Parsons K. Lateral radial head subluxation as a complication following proximal ulnar osteotomy or ostectomy in eight dogs. *Vet Comp Orthop Traumatol.* 2019;32:250-256.
  49. Ahmad CS, ElAttrache NS. Valgus extension overload syndrome and stress injury of the olecranon. *Clin Sports Med.* 2004;23(4):665-676.

**How to cite this article:** Danielski A, Quinonero Reinaldos I, Solano MA, Fatone G. Influence of oblique proximal ulnar osteotomy on humeral intracondylar fissures in 35 spaniel breed dogs. *Veterinary Surgery.* 2023;1-15. doi:[10.1111/vsu.14061](https://doi.org/10.1111/vsu.14061)