

Provided for non-commercial research and education use.
Not for reproduction, distribution or commercial use.



(This is a sample cover image for this issue. The actual cover is not yet available at this time.)

This is an open access article which appeared in a journal published by Elsevier. This article is free for everyone to access, download and read.

Any restrictions on use, including any restrictions on further reproduction and distribution, selling or licensing copies, or posting to personal, institutional or third party websites are defined by the user license specified on the article.


For more information regarding Elsevier's open access licenses please visit:

<http://www.elsevier.com/openaccesslicenses>



Contents lists available at ScienceDirect

JPRAS Open

journal homepage: <http://www.journals.elsevier.com/jpras-open>

Case report

Pinna fillet flap after advanced external ear tumor resection

L. Esposito ^a, S. Razzano ^b, C. Lo Faro ^c, G. Dell'Aversana Orabona ^c,
F. Schonauer ^{a,*}^a Unit of Plastic, Reconstructive and Aesthetic Surgery, Federico II University, Via S. Pansini 5, 80131 Naples, Italy^b Department of Orthopaedic, Traumatologic, Rehabilitative and Plastic-Reconstructive Sciences, Second University of Naples, Piazza Miraglia, 80138 Naples, Italy^c Department of Maxillofacial Surgery, Federico II University, Via S. Pansini 5, 80131 Naples, Italy

ARTICLE INFO

Article history:

Received 26 January 2016

Accepted 4 February 2016

Available online 9 March 2016

Keywords:

Fillet flap

Ear reconstruction

Pinna

Spare parts

ABSTRACT

Reconstruction after excision of infiltrating basal cell carcinomas (BCCs) of the upper pole of the ear can be achieved with different techniques. The concept of spare-part surgery, which allows the surgeon to perform primary reconstruction of a defect without harvesting tissue from the adjacent areas, has been applied to the ear anatomy. We describe our experience with the use of a fillet flap from the residual external ear in two patients out of a series of six, undergoing reconstruction of ear defects after infiltrating BCC resection between January 2011 and December 2014. Reconstruction with the fillet of pinna flap was proven to be an easy surgical technique with good functional and cosmetic outcomes. Our technique, not previously reported, enhances the versatility of ear reconstruction.

© 2016 The Authors. Published by Elsevier Ltd on behalf of British Association of Plastic, Reconstructive and Aesthetic Surgeons. This is an open access article under the CC BY-NC-ND license (<http://creativecommons.org/licenses/by-nc-nd/4.0/>).

Introduction

Five main layers coexist in the auricular anatomical structure. The internal structure of the pinna is composed of a cartilaginous skeleton and a thin layer of perichondrium that surrounds and separates the cartilage from the external skin. The surgical treatment of skin cancer of the ear ranges from more

* Corresponding author. Unit of Plastic, Reconstructive and Aesthetic Surgery, Federico II University, Via S. Pansini 5, 80131 Naples, Italy. Tel.: +39 0817462742.

E-mail addresses: luigi539@msn.com (L. Esposito), razzanosergio@gmail.com (S. Razzano), Lofaroc@gmail.com (C. Lo Faro), giovanni.dellaversanaorabona@unina.it (G. Dell'Aversana Orabona), fschona@libero.it (F. Schonauer).

<http://dx.doi.org/10.1016/j.jpra.2016.02.002>

2352-5878/© 2016 The Authors. Published by Elsevier Ltd on behalf of British Association of Plastic, Reconstructive and Aesthetic Surgeons. This is an open access article under the CC BY-NC-ND license (<http://creativecommons.org/licenses/by-nc-nd/4.0/>).

conservative approaches^{1–3} to total or subtotal ear amputation when the tumor requires wider margins. At a meeting, we presented the use of a skin flap harvested from residual ear tissue, otherwise discarded, for the reconstruction of selected defects.⁴ The concept of filleting the pinna is based on “spare-part” reconstruction.⁵

We report two case descriptions, out of a series of six, of advanced skin cancer infiltrating more than two-thirds of the external ear, almost worth amputation. Lesions were excised and spared clear skin and perichondrium were used to partially or totally cover the residual wound.

Case 1

A 67-year-old man was referred to our clinic for a recurrent infiltrating carcinoma of the upper pole of the right ear (Figure 1). The patient was managed under general anesthesia; resection was performed with 1-cm skin margins, including the temporal fascia on the deep aspect, representing a subtotal amputation of the right ear. Reconstruction decisions were made based on the intraoperative histological examination result (IHER). IHER confirmed an infiltrative basal cell carcinoma (BCC) with clear margins. Reconstruction with a combination of flaps was performed. The clear helical rim skin and perichondrium of the middle third of the ear was dissected off its internal cartilaginous skeleton and used as a pinna fillet flap (PFF) for the reconstruction of the residual defect. The fillet flap was advanced cranially and rotated anteriorly to cover the postauricular wound. A superiorly based preauricular transposition flap was added to complete the reconstruction of the residual upper defect. A Penrose drain was applied (Figure 2). The duration of the surgery was 1 h and 25 m. The patient was discharged the following day after drainage removal. The flap remained viable with no partial flap loss. No dehiscence of the surgical wound was observed. The result remained stable over time; no revision surgery was required. Follow-up at 12 months showed no locoregional recurrence.

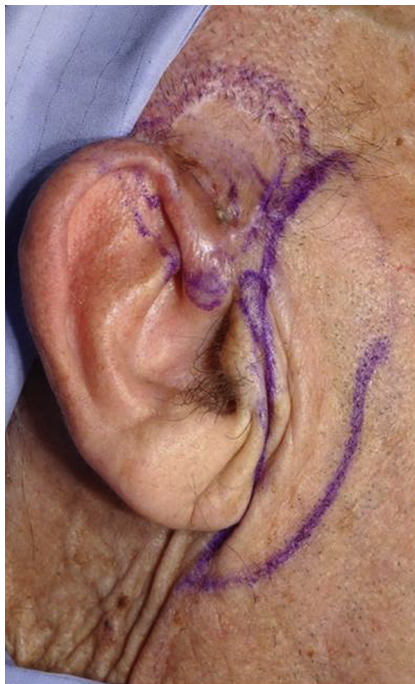

Fig. 1. Recurrent infiltrating carcinoma and preoperative planning.

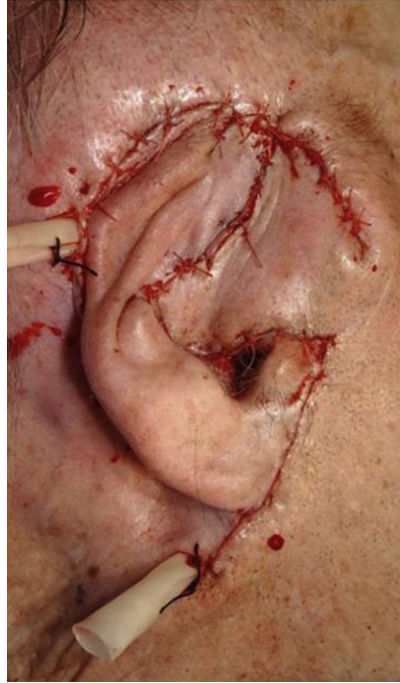

Fig. 2. Immediate postoperative result.

Case 2

A 66-year-old man was referred to us with a 2-year history of an ulcerating lesion of the right ear. At clinical examination, a 5×4.5 -cm ulcerated lesion of the anterior aspect of the right ear was observed, fixed to the underlying layers with the clinical appearance of a deeply infiltrating BCC, involving the preauricular region as well. The patient underwent a procedure of excision of the anterior three-fourths of the pinna. Surgery was performed under local anesthesia with sedation. Resection was performed with 1-cm healthy margins (Figure 3); IHER showed clear margins of the excised lesion and surgical reconstruction with PFF was planned. The residual pinna was entirely freed by its cartilage skeleton. Clear posterior skin and perichondrium of the ear were used as a fillet flap for the reconstruction of the peri-meatal residual defect. The PFF was reflected and advanced anteriorly to cover the defect. No additional skin grafts or flaps were needed. At the level of the external meatus, the flap was opened and the natural meatal orifice recreated. A Penrose drain was applied under the flap. The surgical time was 1 h and 5 m. A gentle pressure dressing was applied on the flap. The patient was managed as a day case, and the drainage was removed in the clinic on the second postoperative day. At the 2-year follow-up, no local recurrence was noted. No stenosis of the meatus was reported, and the aperture remained good (Figure 4).

Discussion

Several alternatives for the coverage of auricular and periauricular defects have been described in the literature including local or pedicled flaps.^{1–3} Possible reconstructive options for medium-to large-sized defects in this area are scalp transposition flaps, superficial temporal artery (STA) island flaps, and pectoralis major myocutaneous pedicled flaps.^{5–8} Reconstruction with locoregional flaps requires general anesthesia and a considerably longer operative time. These techniques are certainly favored in the case of extensive tumor excision, when no clear skin of the native ear can be spared for the

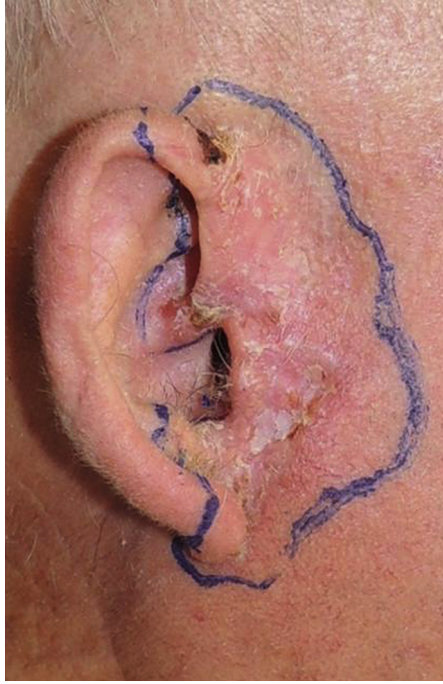

Fig. 3. Ulcerating lesion and preoperative planning.

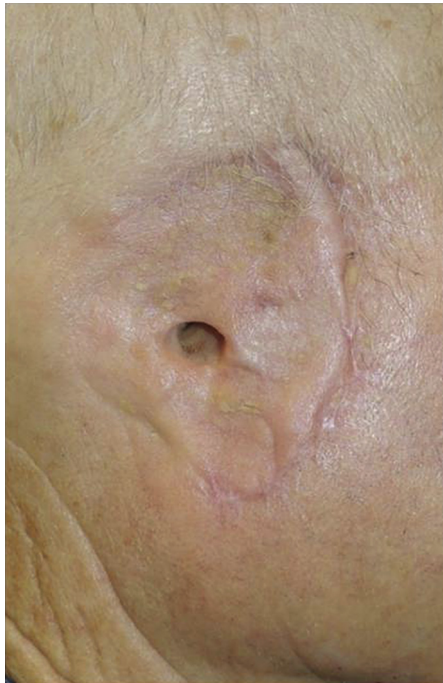


Fig. 4. Final result at the 2-year follow-up.

subsequent reconstruction. Some authors preferred microvascular reconstruction for defects after excision of advanced auricular tumors.⁹ Alternatively, according to the “spare-part” concept, once complete cancer clearance is achieved, if spare tissue is available, a quick, relatively easy, and time-saving reconstruction with good functional and cosmetic results is possible.¹⁰ In our patients, the flaps were composed of healthy tissue.

Dissection of PFF was technically easy and quick. Other advantages of PFF were its color match, the absence of a donor-site defect, and a more natural reconstruction of the native footprint of the ear. PFF cannot be used for defects involving both aspects of the ear.

In conclusion, ear and scalp reconstruction remains a challenge; any reconstruction planning and execution require consideration of the general health of the patient, and of the size and nature of the defect, by selecting among the wide range of options available. We believe that PFF is a further technique for the reconstruction of auricular and periauricular defects after infiltrative BCC excision, especially in elderly patients. Apart from our published abstract, we are not aware of any report of this type of flap to cover ear defects after tumor resection.

Conflicts of interest

None.

Funding

None.

References

1. Bialostocki A, Tan ST. Modified Antia-Buch repair for full-thickness upper pole auricular defects. *Plast Reconstr Surg*. 1999 Apr;103:1476–1479.
2. Taghizadeh R, Teo TC, Gilbert PM. The Antia-Buch flap. *J Oral Maxillofac Surg*. 2008 Oct;66:2194.
3. Schonauer F, Vuppapapati G, Marlino S, Santorelli A, Canta L, Molea G. Versatility of the posterior auricular flap in partial ear reconstruction. *Plast Reconstr Surg*. 2010 Oct;126:1213–1221.
4. Esposito L, Moio M, Mataro I, et al. Fillet of pinna flap in scalp reconstruction. *BMC Surg*. 2013;13(suppl 1):A45.
5. Küntscher MV, Erdmann D, Homann HH, Steinau HU, Levin SL, Germann G. The concept of fillet flaps: classification, indications, and analysis of their clinical value. *Plast Reconstr Surg*. 2001 Sep 15;108:885–896.
6. Colletti G, Tewfik K, Bardazzi A, et al. Regional flaps in head and neck reconstruction: a reappraisal. *J Oral Maxillofac Surg*. 2015 Mar;73(3):571.e1–571.e10.
7. Zayakova Y, Stanev A, Mihailov H, Pashaliev N. Application of local axial flaps to scalp reconstruction. *Arch Plast Surg*. 2013 Sep;40:564–569.
8. Tenna S, Brunetti B, Aveta A, Poccia I, Persichetti P. Scalp reconstruction with superficial temporal artery island flap: clinical experience on 30 consecutive cases. *J Plast Reconstr Aesthet Surg*. 2013 May;66:660–666.
9. Hussussian CJ, Reece GP. Microsurgical scalp reconstruction in the patient with cancer. *Plast Reconstr Surg*. 2002 May;109:1828–1834.
10. Schonauer F, Schaden L, Teo TC. Fillet of finger flap for hand resurfacing after tumor excision. *Eur J Surg Oncol*. 1999 Aug;25:424–426.