



ELSEVIER



## Correspondence and Communications

## Elective localization at the upper left chest of Dermatofibrosarcoma Protuberans



Dear Sir,

Dermatofibrosarcoma Protuberans is a superficial, low-grade, locally aggressive, fibroblastic sarcoma that occurs in young patients, predominately in the trunk. Although its incidence is rare (<1 per 100,000 tumors), DFSP is the most common dermal sarcoma.<sup>1</sup>

Because DFSP can be highly infiltrative in the subcutaneous tissues and along fascial planes, it is mandatory obtaining an early exact diagnosis. In fact, if neglected or underappreciated at the time of surgical resection, the risk of local recurrences is very high.

DFSP site predilection for the trunk is widely recognized in the literature. In a large population-based study of DFSP derived from a cohort of almost 7000 patients, trunk was the most common anatomic site, except in older men.<sup>2</sup>

Cases of Dermatofibrosarcoma Protuberans of the breast have been reported too, both in female<sup>3</sup> and male patients.<sup>4</sup>

Between 1998 and 2018 at our Plastic Surgery Unit we have observed and treated 28 patients with DFSP, 18 male and 10 female, with an age-range between 14 and 64 years old. According to the guidelines, we treated our patients

with wide surgical excision and immediate reconstruction; for all 28 patients we received final histology compatible with DFSP.

The lesions were located as follows: 13 at the left chest (of which one at the left breast), 3 at the proximal left arm, 3 on the head, 2 at the right chest, 3 on the dorsum (one upper dorsal, one infrascapular area, one lumbosacral region), 1 right groin, 1 left groin, 1 left thigh, 1 left foot.

The most common site of occurrence was the chest (Figure 1); in particular we have observed an “hot spot” of localization in the subclavicular/parasternal region of the left chest, (Figure 2) accounting for 57% (16 out of 28 lesions).

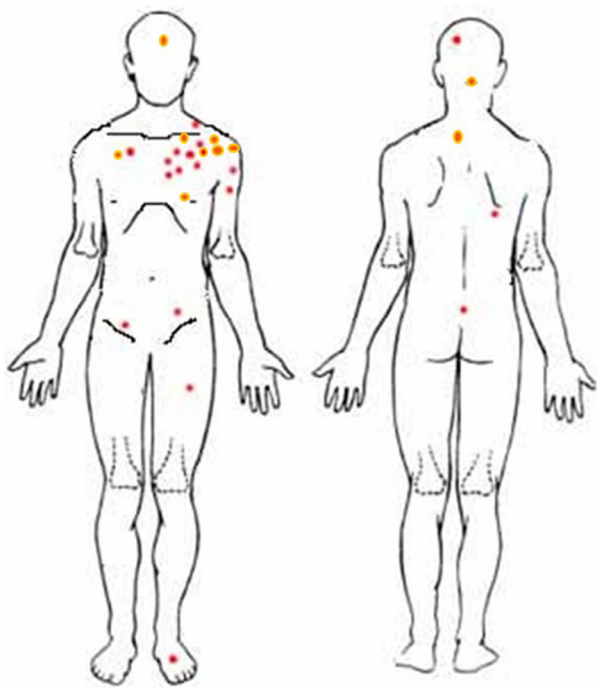
Other papers have studied the DFSP prevalence for site showing that most frequent localizations are in the trunk, followed by the limbs (especially at the proximal third) and last by the head and neck region.<sup>5</sup> However, a preferential localization with a specific “hot spot” area has not been reported so far.

Starting from this clinical observation few questions should arise: why so many cases exactly in the same site? Is there a reason to explain the prevalence of DFSP in that specific area of the body?

Considering the small number of cases we cannot draw final statements; our future intent is to understand if there

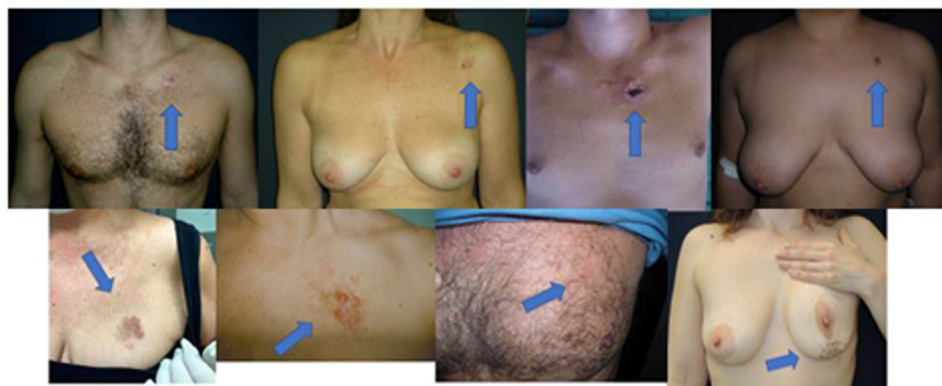

Figure 1 Series of patient pictures documenting Dermatofibrosarcoma Protuberans elective localization at the upper chest.



**Figure 2** “Hot spot” of localization in the subclavicular/parasternal region of the left chest.

is a specific anatomical or pathological reason that could justify this cutaneous distribution.

In conclusion, our message to Dermatologists, Plastic Surgeons and General Practitioners is to consider a preferential localization at the left upper chest for DFSP, comparable to the nose and central face for Basal Cell Carcinoma or to the scalp or lower lip for Squamous Cell Carcinoma.

### Declaration of Competing Interest

None.

### Funding

None.

### References

1. Gladdy RA, Wunder JS. Risk-stratified surveillance in dermatofibrosarcoma protuberans: less is more. *Cancer* 2019;125(5):670-2 Mar 1.
2. Kreicher KL, Kurlander DE, Gittleman HR, Barnholtz-Sloan JS, Bordeaux JS. Incidence and survival of primary Dermatofibrosarcoma Protuberans in the US. *Dermatol Surg* 2016;42(1):S24-31 JanSuppl.
3. Muhammed A, Elnakib E, Nady M. Dermatofibrosarcoma of the breast - case report and review of literature. *Eur J Breast Health* 2018;14(4):234-7.
4. Saikia BK, Das I, Mandal GK. Fibrosarcomatous change in the background of dermatofibrosarcoma protuberans in male breast: study of a rare case and review of the entity. *J Midlife Health* 2016;7(1):45-8 Jan-Mar.
5. D’Andrea F, Voza A, Brongo S, Di Girolamo F, Voza G. Dermatofibrosarcoma protuberans: experience with 14 cases. *J Eur Acad Dermatol Venereol* 2001;15(5):427-9.

Fabrizio Schonauer, Ludovica Giordano,  
Francesco D’Andrea

*Unit of Plastic and Reconstructive Surgery, Federico II  
University of Naples, Italy*

*E-mail address: fschona@libero.it*

© 2020 British Association of Plastic, Reconstructive and Aesthetic Surgeons. Published by Elsevier Ltd. All rights reserved.

<https://doi.org/10.1016/j.bjps.2020.05.097>