

Endovascular Treatment of Distal Aortic Arch Aneurysm Associated with Coarctation of Aorta

in a Jehovah's Witness

Luigi Di Tommaso, MD
Vito A. Mannacio, MD
Ettorino Di Tommaso, MD
Giovanni B. Pinna, MD
Immacolata Fontana, MD
Gabriele Iannelli, MD

Late aneurysm formation in the proximal aorta or distal aortic arch is a recognized sequela of untreated stenosis of the aortic isthmus and is associated with substantial risk of aortic rupture. We describe the case of a 44-year-old man with untreated coarctation of the aorta who presented with a prestenotic dissecting thoracic aortic aneurysm. He declined surgery because he was a Jehovah's Witness. Instead, we performed emergency endovascular aortic repair in which 2 stent-grafts were placed in the descending aorta. Our experience suggests that this procedure is a useful and safe alternative to open surgery in patients who have aneurysms associated with coarctation of the aorta. (*Tex Heart Inst J* 2017;44(6):399-401)

Presented at the AATS
Aortic Symposium, New
York, 24–25 April 2014.

Key words: Aortic coarctation/complications; aortic aneurysm, thoracic/etiology; blood vessel prosthesis implantation/methods; endovascular procedures/methods; Jehovah's Witness; stents; subclavian artery/surgery; time factors; treatment outcome; vascular surgical procedures/methods

From: Departments of Cardiac Surgery (Drs. E. Di Tommaso, L. Di Tommaso, Iannelli, Mannacio, and Pinna) and Anesthesiology (Dr. Fontana), School of Medicine, University Federico II, 80131 Naples, Italy

Address for reprints:
Luigi Di Tommaso, MD,
Via Vincenzo Gemito 35,
81100 Caserta, Italy

E-mail: lditommaso@tin.it

© 2017 by the Texas Heart®
Institute, Houston

Coarctation of the aorta accounts for 3% to 5% of congenital cardiac malformations.¹⁻³ Late aneurysmal formation in the proximal or distal aortic arch is a well-recognized sequela of untreated coarctation, and it is associated with an increased risk of aortic rupture and death.⁴ The prevalence of these aneurysms was 20% in the era before surgical treatment was feasible, and 5% thereafter.^{1,2} It has been reported that 32% of aneurysms are proximal to the coarctation, 51% are distal, and 17% involve the left subclavian artery (LSA) rather than the aorta.^{1,2} After surgical correction of coarctation, aneurysms may also form at the site of repair, regardless of the surgical technique used.²

We describe the case of a Jehovah's Witness with an untreated coarctation who had an acute dissection of a prestenotic thoracic aortic aneurysm. To avoid open surgery and the need for blood products, we performed an emergency endovascular aortic repair. Only a few patients have undergone this treatment, and, to our knowledge, our patient was the first to have it in an emergency.^{3,5}

Case Report

In April 2013, a 44-year-old man with untreated coarctation of the aorta experienced new-onset chest pain and sought treatment at a local hospital. He was transferred to our institution when he was diagnosed with acute dissection of a thoracic aortic aneurysm.

The coarctation and a large prestenotic aortic aneurysm, proximal to the LSA, had been diagnosed 20 years earlier. The patient also had a history of systemic hypertension, which had been managed medically. His blood pressure was 150/100 mmHg at the current presentation.

Contrast-enhanced computed tomograms showed a tortuous descending thoracic aorta with a voluminous dissected aneurysm, distal to the origin of the subclavian artery (Figs. 1 and 2). Angiograms showed that the aneurysm was prestenotic (diameter, 78 mm; gradient, 45 mmHg) and proximal to the untreated coarctation (Fig. 3).

The patient would have been a candidate for open surgery, but his religious beliefs precluded blood transfusion if bleeding occurred, placing him at an extremely high risk of death. Although endovascular repair has risks, this option was considered to be safer because it would minimize the risk of bleeding and reduce the risk of injury to the laryngeal and phrenic nerves.

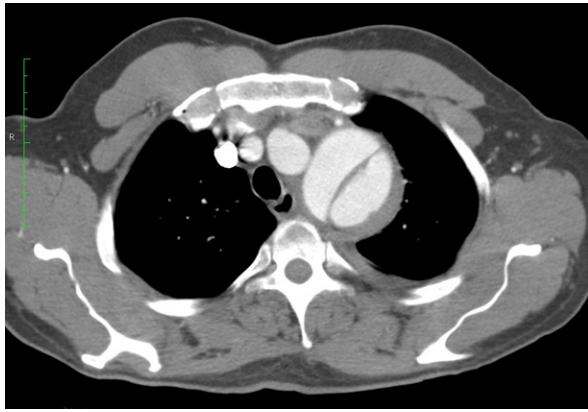


Fig. 1 Preoperative contrast-enhanced computed tomogram shows the dissecting aneurysm of the descending thoracic aorta, distal to the origin of the left subclavian artery.

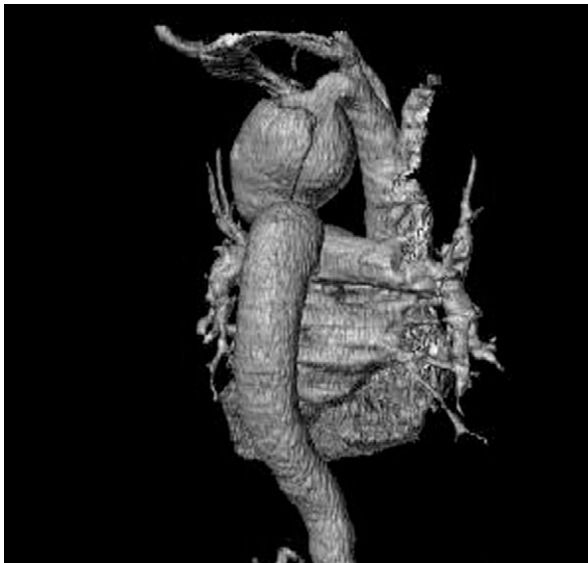


Fig. 2 Preoperative computed tomogram (3-dimensional volume-rendered reconstruction) of the thoracic aorta shows the dissected aneurysm.

The procedure to implant 2 stent-grafts was performed with the patient under general anesthesia and mechanical ventilation with invasive monitoring. He was given 5,000 IU of intravenous unfractionated heparin before insertion of the catheters. Femoral access was achieved by surgical dissection of the right common femoral artery, but the stenotic and aneurysmal tract of the descending thoracic aorta prevented passage of the catheter. Therefore, we introduced a pigtail catheter through the right radial artery, evaluated the aorta angiographically, and advanced the catheter through the aneurysm and stenosis, down to the common right femoral artery. Next, we introduced a stiff guidewire through the pigtail catheter and advanced it to the common right femoral artery. Finally, we introduced

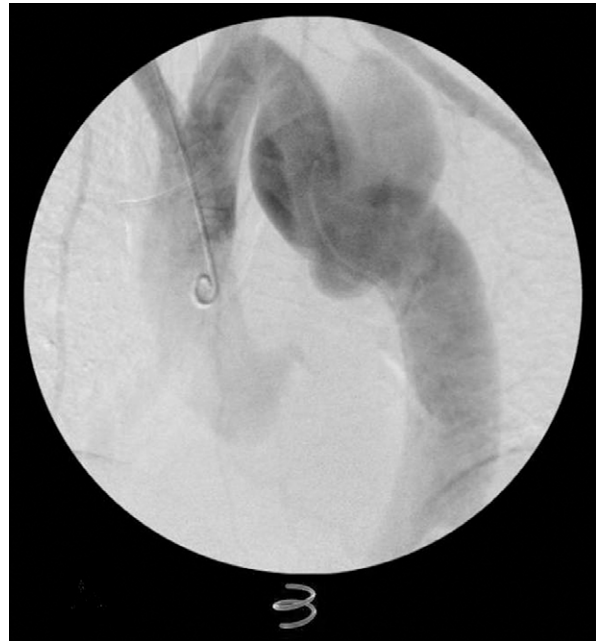

Fig. 3 Angiogram before stent-graft implantation shows the prestenotic dissected aneurysm proximal to the untreated coarctation.

a pigtail catheter through the femoral artery and advanced it over the guidewire, up to the ascending aorta.

One after the other, we introduced two 300-cm, 0.035-in Meier™ Guidewires (Boston Scientific Corporation; Natick, Mass) to straighten the descending aorta. To completely exclude the aneurysmal sac, we used fluoroscopic guidance to place 2 Valiant® stent-grafts (Medtronic, Inc.; Minneapolis, Minn) over one of the 2 guidewires and move them into the optimal position at the distal aortic arch. The devices were oversized by 10% compared with the normal aorta of the landing zone. We deliberately covered the origin of the LSA to affix the stent-graft proximally. (We did not perform revascularization because specific indications were not present, such as dominant left vertebral artery, marked stenosis of the right vertebral artery, and inclusion of the internal carotid artery.⁶⁻⁸) Rapid pacing and hypotension were induced to enable correct positioning of the stent-grafts. A subsequent aortogram confirmed that the aneurysmal sac had been completely occluded and that there were no endoleaks or bleeding (Fig. 4). Postoperatively, the pressure gradient across the coarctation decreased to less than 10 mmHg.

The patient was discharged from the hospital within one week. Computed tomographic scans were performed at 3, 6, 18, and 36 months (Fig. 5). Complete thrombosis of the aneurysmal sac was achieved, and the patient's antihypertensive therapy was markedly reduced. To prevent further development of aneurysms, we treated his residual mild systemic hypertension with an angiotensin-converting enzyme inhibitor. The pa-

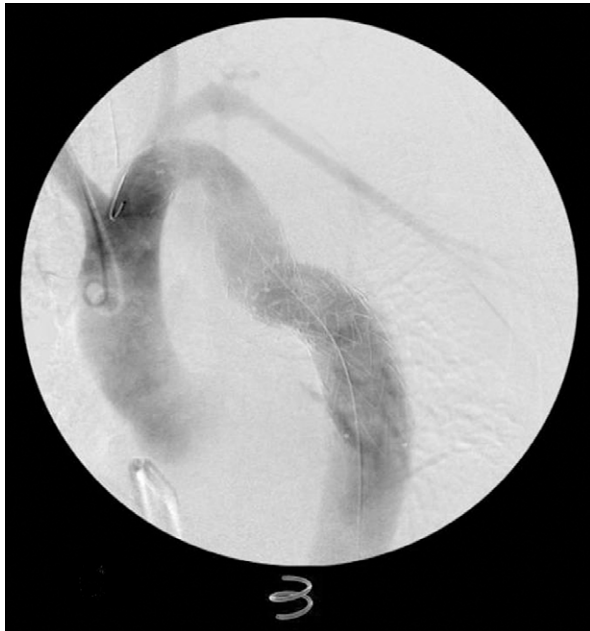


Fig. 4 Angiogram after stent-graft implantation shows occlusion of the aneurysmal sac with absence of endoleaks and bleeding.

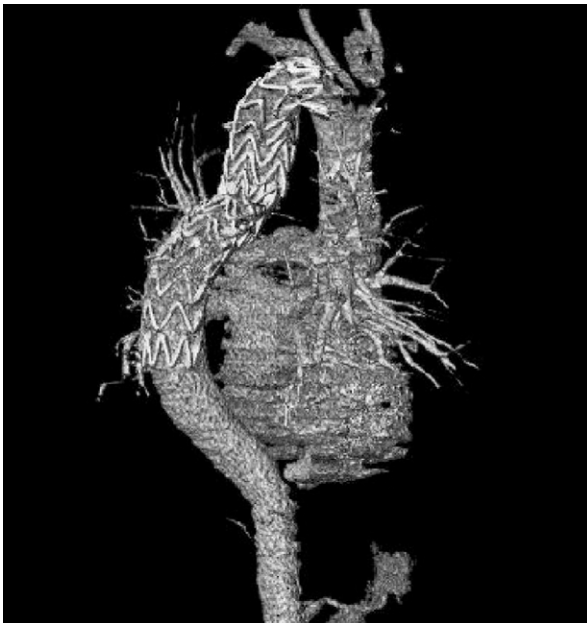

Fig. 5 Postoperative computed tomogram (3-dimensional volume-rendered reconstruction) of the thoracic aorta shows complete thrombosis of the aneurysmal sac.

tient had no signs or symptoms related to the intentional occlusion of the LSA.

Discussion

Surgery to repair aneurysms associated with coarctation of the aorta is challenging. Patients with anatomic complexities or aortic arch involvement may need a

longer aortic cross-clamp time, left-sided heart bypass, cerebrospinal drainage, and deep hypothermia. In some patients, especially those in whom aneurysms develop after a surgical coarctation repair, endovascular repair may be an alternative to open surgery because it avoids the severe morbidity associated with surgical reoperation. Our good results in the treatment of unusual thoracic aortic diseases⁸ and encouraging experience in the current patient show the potential usefulness of endovascular repair in patients with aneurysms associated with coarctation. Most of these aneurysms can be treated with short stent-grafts, which reduce the risk of paraplegia and enable safe coverage of the LSA. Further studies including cross-sectional imaging are needed to determine the long-term effectiveness and durability of stent-grafts in this situation.

References

1. Jenkins NP, Ward C. Coarctation of the aorta: natural history and outcome after surgical treatment. *QJM* 1999;92(7):365-71.
2. Preventza O, Livesay JJ, Cooley DA, Krajcer Z, Cheong BY, Coselli JS. Coarctation-associated aneurysms: a localized disease or diffuse aortopathy. *Ann Thorac Surg* 2013;95(6):1961-7.
3. Bell RE, Taylor PR, Aukett M, Young CP, Anderson DR, Reidy JF. Endoluminal repair of aneurysms associated with coarctation. *Ann Thorac Surg* 2003;75(2):530-3.
4. Hormann M, Pavlidis D, Brunkwall J, Gawenda M. Long-term results of endovascular aortic repair for thoracic pseudoaneurysms after previous surgical coarctation repair. *Interact Cardiovasc Thorac Surg* 2011;13(4):401-4.
5. Khavandi A, Bentham J, Marlais M, Martin RP, Morgan GJ, Parry AJ, et al. Transcatheter and endovascular stent graft management of coarctation-related pseudoaneurysms. *Heart* 2013;99(17):1275-81.
6. Di Tommaso L, Monaco M, Mottola M, Piscione F, Pantaleo A, Pinna GB, et al. Major complications following endovascular surgery of descending thoracic aorta. *Interact Cardiovasc Thorac Surg* 2006;5(6):705-8.
7. Sobocinski J, Patterson BO, Karthikesalingam A, Thompson MM. The effect of left subclavian artery coverage in thoracic endovascular aortic repair. *Ann Thorac Surg* 2016;101(2):810-7.
8. Di Tommaso L, Iannelli G, Mottola M, Mannacio M, Poli V, Esposito G, et al. TEVAR for iatrogenic injury of the distal aortic arch after pacemaker implantation. *EJVES Extra* 2013;26(2):e17-e20. Available from: https://www.researchgate.net/publication/257614987_TEVAR_for_Iatrogenic_Injury_of_the_Distal_Aortic_Arch_after_Pacemaker_Implantation.